

**Sir,  
Vertical rectus transposition in Duane's syndrome: does co-contraction worsen?**

We read with interest the article by Akar *et al.*<sup>1</sup> We would like to make the following observations/queries.

In patients with Duane's retraction syndrome there is some degree of subnormal and some degree of anomalous innervation of the lateral rectus (LR) muscle. The extent and severity of the two may be variable. Presumably, subnormal innervation may lead to deficient abduction and anomalous innervation may lead to co-contraction with globe retraction, palpebral aperture narrowing, or retraction equivalents like upshoots and downshoots.

In their article the authors describe patients of type 1 Duane syndrome to be with esotropia of 20 pd or more, an AHP larger than 20°, limited abduction, and no significant upshoots or downshoots in the adducted position. There is no objective grading used for the measurement of shoots or palpebral aperture changes. Some of these cases may have had retraction or retraction equivalents (shoots) that were not clinically very apparent.

It has been suggested that vertical rectus transposition (VRT) may worsen retraction and shoots.<sup>2,3</sup> Thus an objective measurement (pre- and postoperative) of palpebral aperture changes and shoots is in order, more so with augmented transposition as in Akar *et al.*<sup>1</sup>

Also, the confirmation of absence of anomalous LR innervation pre-operatively is essential. This may be assessed by the Romero-Apis force degeneration test<sup>4</sup> or, as suggested by some, by electromyography.<sup>5</sup>

It has also been suggested by some that prerequisite to VRT should be the elimination of misinnervation of the lateral rectus by a procedure such as periosteal fixation.<sup>6</sup>

We notice some increase in globe retraction on adduction in Figure 2a; however, it is difficult to comment with only a single photograph. We would like to know from the authors whether they noticed any worsening of retraction or shoots in their patients on follow-up.

In our opinion, VRT in DRS cases should always be performed with the rider that retraction and retraction equivalents may worsen.

**Conflict of interest**

The authors declare no conflict of interest.

**References**

- 1 Akar S, Gokyigit B, Pekel G, Demircan A, Demirok A. Vertical muscle transposition augmented with lateral fixation (Foster) suture for Duane syndrome and sixth nerve palsy. *Eye (Lond)* 2013; **27**: 1188–1195.
- 2 Rosenbaum AL. Costenbader lecture. The efficacy of rectus muscle transposition surgery in esotropic Duane syndrome and VI nerve palsy. *J AAPOS* 2004; **8**: 409–419.
- 3 Molarte AB, Rosenbaum AL. Vertical rectus muscle transposition surgery for Duane's syndrome. *J Pediatr Ophthalmol Strabismus* 1990; **27**: 171–177.
- 4 Romero-Apis D. *Estrabismo*. Auroch: Mexico, DF Auroch, 1997, p 156.

- 5 Souza-Dias C. Congenital VI nerve palsy is Duane syndrome until disproven. *Binocul Vis Strabismus Q* 1992; **7**: 70.
- 6 Sharma P, Tomar R, Menon V, Saxena R, Sharma A. Evaluation of periosteal fixation of lateral rectus and partial VRT for cases of exotropic Duane's retraction syndrome. *Indian J Ophthalmol* 2014; **62**: 204–208.

V Bhambhwani, PK Pandey, S Sood and K Rana

Guru Nanak Eye Centre and Maulana Azad Medical College, New Delhi, India  
E-mail: vishaalb@gmail.com

*Eye* (2015) **29**, 839; doi:10.1038/eye.2014.309;  
published online 6 February 2015

**Sir,  
Reply: Vertical rectus transposition in Duane's syndrome: does co-contraction worsen?**

We thank Bhambhwani *et al.*<sup>1</sup> for their remarks, which we shall address in turn. With regard to Bhambhwani *et al.*'s comments on 'Vertical rectus transposition in Duane's syndrome: does co-contraction worsen?' we reported in Table 1 (complications part) that no case had lid fissures narrowing.<sup>2</sup> For all patients, standardized preoperative and postoperative photographs were taken in the following manner. Photographs were taken at a fixed distance, under identical lighting conditions, with the patient in a sitting position, and with the eyes in primary gaze. The patient's head was placed firmly in the head rest of a slit lamp and the lateral canthal angles were aligned with the side marks. An 18-inch metal bar had been fixed to the head rest of the slit lamp, projecting forward. The camera was held directly beneath the metal bar, moving forward or backward to focus on the patient's lid margins. The patient was asked to fixate on the camera while the uninvolved eye was occluded. Photographs were taken with a digital camera (Cybershot DSC-F828; Sony Electronics Inc, Tokyo, Japan) with a macrolens at a reproduction ratio of 1:4.

Digital image analysis was used to standardize each patient's preoperative and postoperative photographs for accurate objective comparison. Preoperative and postoperative photographs at the final follow-up examination were analyzed for margin-to-reflex distance (MRD), in mm, and used to access eyelid position. Adobe Photoshop version 7.0.1 (Adobe Systems Inc, San Jose, CA, USA) was used to measure the distance (pixels) from the center of the pupil to the upper eyelid margin (MRD<sub>1</sub>) and lower eyelid margin (MRD<sub>2</sub>), and the corneal diameter. The MRD<sub>1</sub> and MRD<sub>2</sub> were then standardized to an average horizontal corneal diameter (calculated as 11.6 mm in women and 11.7 mm in men), as described previously.<sup>3,4</sup> There was no statistically significant difference between the preoperative and postoperative standardized MRD (MRD<sub>1</sub> + MRD<sub>2</sub>) (independent samples *t*-test) (*P* = 0.652). After vertical rectus transposition surgery (standard or augmented), there was no worse retraction or up- or downshoots.

As suggested by some authors,<sup>5</sup> the electromyography of all patients was assessed preoperatively for confirmation of absence of anomalous lateral rectus innervation. No patients had anomalous lateral rectus innervation.

Figure 2A shows preoperative and postoperative photographs of a case with left type 1 Duane syndrome. For this patient, the preoperative MRD was 9.0 mm and the postoperative MRD was 9.5 mm. We did not determine an increase in globe retraction on adduction for the left eye.

Some authors reported that vertical rectus transposition surgery in cases of Duane's retraction syndrome may worsen globe retraction or up- or downshoots.<sup>6,7</sup> However, other studies have determined that globe retraction or up- or downshooting did not worsen.<sup>8,9</sup> We did not notice any worsening of retraction or shoots in our patients on follow-up.

#### Conflict of interest

The authors declare no conflict of interest.

#### References

- 1 Bhambhwani V, Pandey PK, Sood S, Rana K. Vertical rectus transposition in Duane's syndrome: does co-contraction worsen? *Eye (Lond)* 2015; **29**: 839.
- 2 Akar S, Gokyigit B, Pekel G, Demircan A, Demirok A. Vertical muscle transposition augmented with lateral fixation (Foster) suture for Duane syndrome and sixth nerve palsy. *Eye (Lond)* 2013; **27**(10): 1188–1195.
- 3 Taban M, Taban M, Perry JD. Lower eyelid position after transconjunctival lower blepharoplasty with versus without a skin pinch. *Ophthalm Plast Reconstr Surg* 2008; **24**(1): 7–9.
- 4 Chang EL, Bernardino CR, Rubin PA. Normalization of upper eyelid height and contour after bony decompression in thyroid-related ophthalmopathy: a digital image analysis. *Arch Ophthalmol* 2004; **122**(12): 1882–1885.
- 5 Sausa-Dias C. Congenital VI. nerve palsy is Duane syndrome until disproven. *Binocul Vis Strabismus Q* 1992; **7**: 70.
- 6 Rosenbaum AL. Costenbader lecture. The efficacy of rectus muscle transposition surgery in esotropic Duane syndrome and VI nerve palsy. *J AAPOS* 2004; **8**: 409–419.
- 7 Molarte AB, Rosenbaum AL. Vertical rectus muscle transposition surgery for Duane's syndrome. *J Pediatr Ophthalmol Strabismus* 1990; **27**: 171–177.
- 8 Velez FG, Foster RS, Rosenbaum AL. Vertical rectus muscle augmented transposition in Duane syndrome. *J AAPOS* 2001; **5**: 105–113.
- 9 Britt MT, Velez FG, Velez G. Vertical rectus muscle transposition for bilateral Duane syndrome. *J AAPOS* 2005; **9**: 416–421.

S Akar<sup>1</sup>, B Gokyigit<sup>2</sup>, G Pekel<sup>3</sup>, A Demircan<sup>2</sup> and A Demirok<sup>2</sup>

<sup>1</sup>Department of Ophthalmology, Faculty of Medicine, Baskent University, Istanbul, Turkey

<sup>2</sup>Pediatric Ophthalmology and Strabismus Department, Professor Dr N Reşat Belger Beyoglu Education and Research Eye Hospital, Istanbul, Turkey

<sup>3</sup>Department of Ophthalmology, Faculty of Medicine, Pamukkale University, Denizli, Turkey  
E-mail: akarserpil@yahoo.com

*Eye* (2015) **29**, 839–840; doi:10.1038/eye.2014.310;  
published online 6 February 2015

#### Sir, *Enterococcus casseliflavus* endophthalmitis due to metallic intraocular foreign body

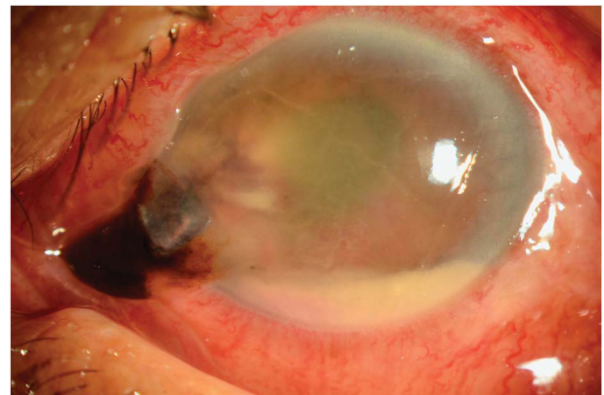
*Enterococcus casseliflavus* infection has been rarely implicated in ophthalmic infections. We report a case of *E. casseliflavus* exogenous endophthalmitis due to a metallic intraocular foreign body (IOFB).

#### Case report

A healthy 54-year-old male presented with a 3-day history of left eye pain and blurred vision after a metal chip entered his left eye during hammering. As the accident occurred overseas, there was a 3-day interval from injury to presentation.

Visual acuity of the left eye was hand movement with a left grade 4 reverse relative afferent pupillary defect. Slit lamp examination findings are shown in Figure 1. Computed tomography of orbits confirmed a 3 × 6 mm metallic IOFB impacted in the retina inferiorly.

He underwent left corneoscleral laceration repair, phacoemulsification (with no intraocular lens implanted), 20G vitrectomy, IOFB removal through the corneal incision with the aid of an intraocular magnet, intravitreal vancomycin (1 mg/0.1 ml) and ceftazidime (2.25 mg/0.1 ml), and silicone oil injection. Postoperatively, topical cefazolin, gentamicin, and atropine were commenced. Vitreous culture grew



**Figure 1** Slit lamp examination of the left eye showed conjunctival chemosis, corneal oedema, and an inferonasal corneoscleral laceration with iris prolapse. The anterior chamber was shallow with a fibrinous reaction and a 1.6-mm hypopyon.