






PAC-MAN Endocarditis: Atypical Vegetation on the Mitral Valve

PAC-MAN Endokarditi: Mitral Kapak Üzerinde Atipik Vejetasyon

 Cihan İlyas SEVGİCAN,^a
 İbrahim OĞUZ,^a
 Havane Asuman KAFTAN,^a
 Bilgin EMRECAN,^b
 Samet YILMAZ^a

Departments of
^aCardiology,
^bCardiovascular Surgery,
 Pamukkale University
 Faculty of Medicine,
 Denizli, TURKEY

Received: 16.08.2018
 Accepted: 05.10.2018
 Available online: 19.12.2018

Correspondence:
 Cihan İlyas SEVGİCAN
 Pamukkale University
 Faculty of Medicine,
 Department of Cardiology, Denizli,
 TURKEY/TÜRKİYE
 c7sevgican@gmail.com

Keywords: Mitral valve;
 endocarditis; surgery

Anahtar Kelimeler: Mitral kapak;
 endokardit; cerrahi

A 72 year-old male who was under the treatment of intravenous prednisolone for contact dermatitis in dermatology clinic was consulted to cardiology department for chest pain and intermittent fever episodes. Patient's past medical history was consisted with hypertension and atrial fibrillation and he was using amlodipine 10 mg once a day. His physical examination revealed blood pressure 90/60 mmHg and heart rate 120 per minute. There was a 3/6 systolic murmur in mesocardiac area. During the course of the evaluation, laboratory tests revealed *creatinine* 1.37 mg/dL, CRP 21.4 mg/dL, WBC 19.04 K/uL, Hb 13.8 g/dL and PLT 68,000/mm³. *Coagulase-Negative Staphylococcus spp.* was detected in the blood culture which was taken two days before examination.

Transthoracic echocardiography revealed normal left ventricular ejection fraction, concentric left ventricular hypertrophy, biatrial dilatation, moderate mitral and tricuspid regurgitation. Hypodense and mobile vegetation was detected in the size of 13*18 mm on the atrial surface of the posterior mitral leaflet. Transesophageal echocardiography clearly demonstrated PAC-MAN like atypical vegetation on the mitral valve (Figure 1). Due to the presence of left-sided heart valve involvement, mobile and large vegetation, immediate valve sparing surgery was performed to the patient. Surgical material also confirmed the atypical shaped cardiac vegetation (Figure 2). *Staphylococcus aureus* was seen in the patient's surgical material culture. After the surgery, the patient was followed for six weeks by appropriate antibiotherapy and discharged uneventfully.

If atypical forms of vegetations are seen on the echocardiography, especially on the valves, and the clinic is appropriate, the diagnosis of infective endocarditis should be added to the differential diagnosis. Identification of the agent, appropriate antibiotherapy and follow-up, and, if necessary, surgical planning at optimal time are life-saving treatment. Especially protection of high-risk patients from frequent bacteremia episodes (oral hygiene, protection from wound infections, intravenous drug abuse, immunosuppressive treatment) and close follow-up is important for preventive medicine.

Source of Finance

During this study, no financial or spiritual support was received neither from any pharmaceutical company that has a direct connection with the research subject, nor from a company that provides or produces medical instruments and materials which may negatively affect the evaluation process of this study.

Conflict of Interest

No conflicts of interest between the authors and/or family members of the scientific and medical committee members or members of the potential conflicts of interest, counseling, expertise, working conditions, share holding and similar situations in any firm.

Authorship Contributions

Idea/Concept: Cihan İlyas Sevgican, İbrahim Oğuz; **Design:** Samet Yılmaz; **Control/Supervision:** Havane Asuman Kaftan, Samet Yılmaz; **Data Collection and/or Processing:** İbrahim Oğuz, Cihan İlyas Sevgican; **Analysis and/or Interpretation:** Samet Yılmaz, Havane Asuman Kaftan; **Literature Review:** İbrahim Oğuz, Cihan İlyas Sevgican; **Writing the Article:** Cihan İlyas Sevgican, İbrahim Oğuz; **Critical Review:** Havane Asuman Kaftan, Samet Yılmaz; **References and Fundings:** Samet Yılmaz, Bilgin Emreca, Havane Asuman Kaftan; **Materials:** Bilgin Emreca.

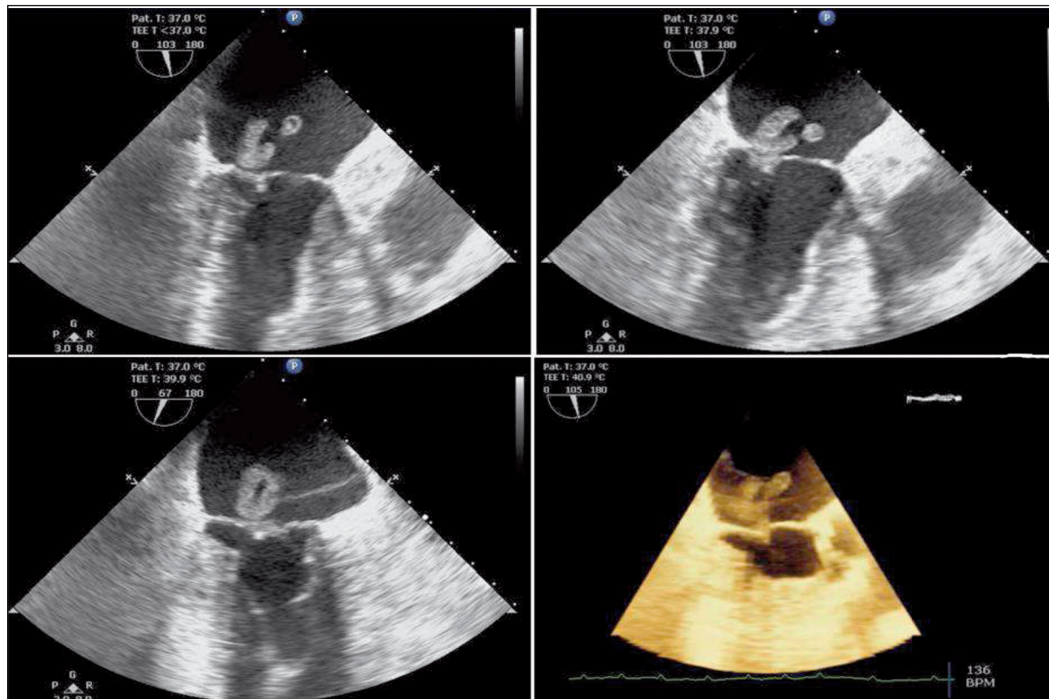


FIGURE 1: Atypical vegetation is seen on the posterior leaflet of the mitral valve.

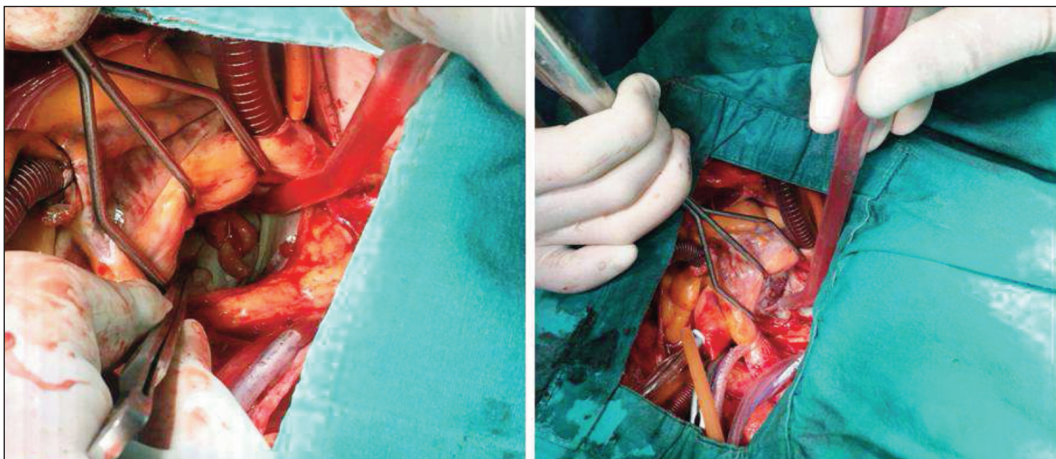


FIGURE 2: Atypical vegetation is seen on the mitral valve posterior leaflet (Left image), Posterior mitral leaflet image after resection (Right image).