

# The influence of iris color and retina pigment epithelium melanin on allergic rhinitis

Sefa Dereköy<sup>1</sup>, Fethullah Kenar<sup>2</sup>, Güliz Fatma Yavaş<sup>3</sup>, Tuncay Küsbeci<sup>3</sup>, Faruk Öztürk<sup>2</sup>, Abdullah Ayçiçek<sup>4</sup>

<sup>1</sup>Department of Otolaryngology, Faculty of Medicine, Çanakkale Onsekiz Mart University, Çanakkale, Turkey

<sup>2</sup>Department of Otolaryngology, Faculty of Medicine, Pamukkale University, Denizli, Turkey

<sup>3</sup>Department of Ophthalmology, Faculty of Medicine, Afyon Kocatepe University, Afyonkarabisar, Turkey

<sup>4</sup>Department of Otolaryngology, Faculty of Medicine, Afyon Kocatepe University, Afyonkarabisar, Turkey

## Abstract

**Objective:** The purpose of this case control study is to establish the influence of iris color and retina pigment epithelium melanin on allergic rhinitis.

**Methods:** Ninety-nine subjects diagnosed prospectively as allergic rhinitis and 85 control subjects were included in the study. Color of iris was recorded after ophthalmic examination. Electro-oculographic measurement was done after pupil dilatation and Arden ratios were recorded.

**Results:** Mean age was 29.44±9.8 years in subject with allergic rhinitis and 32.67±12.9 years in control subjects (p>0.05). Measured mean Arden ratio was 158.22±29.4 in subjects with allergic rhinitis and 179.34±29.3 in normal subjects (p<0.05). In control group, Arden ratio was significantly higher in eyes with brown iris (p<0.05). In subjects with allergic rhinitis, Arden ratio was significantly lower in brown eyes (p<0.05).

**Conclusion:** An association between allergic rhinitis and melanin content of iris and retina pigment epithelium was found. It can be speculated that pigment-producing system may play a role in the pathogenesis of the allergic rhinitis.

**Keywords:** Allergic rhinitis, iris color, retina pigment epithelium, Arden ratio, melanin.

## Özet: İris rengi ve retina pigment epitel melanininin alerjik rinite olan etkisi

**Amaç:** Bu olgu kontrol çalışmasının amacı, iris rengi ve retina pigment epitel melanininin alerjik rinite olan etkisini saptamaktır.

**Yöntem:** Çalışmaya 85 kontrol denek ve prospektif olarak alerjik rinit tanısı konan 99 hasta alındı. Göz muayenesinden sonra iris rengi kaydedildi. Pupil dilatasyonundan sonra elektrookülografik ölçüm yapıldı ve Arden oranları kaydedildi.

**Bulgular:** Yaş ortalaması alerjik rinitli hastalarda 29.44±9.8 yıl, kontrol deneklerde 32.67±12.9 yıl idi (p>0.05). Ölçülen Arden oranı ortalaması alerjik rinitli hastalarda 158.22±29.4, kontrol deneklerde 179.34±29.3 idi (p<0.05). Kontrol grubunda Arden oranı kahverengi irisi olan gözlerde anlamlı derecede daha yüksekti (p<0.05). Alerjik rinitli hastalarda Arden oranı kahverengi irisi olan gözlerde anlamlı derecede daha düşüktü (p<0.05).

**Sonuç:** Alerjik rinit ile iris ve retina pigment epitelinin melanin içeriği arasında bir ilişki bulunmuştur. Pigment üretici sistemin alerjik rinit patogenezinde rol oynayabileceği öne sürülebilir.

**Anahtar sözcükler:** Alerjik rinit, iris rengi, retina pigment epiteli, Arden oranı, melanin.

Allergic rhinitis is an increasingly common disorder which manifests itself with symptoms of itchy nose, rhinorrhea, sneezing and nasal congestion as a result of exposure of sensitized individuals to certain antigens. The release of vasoactive mediators such as histamine, leukotrienes, prostaglandins, cytokines and trypsin follows after allergens

bind specific IgE on the surfaces of basophils and mast cells and they show their effects in nasal vasculature by their receptors to result in either vasoconstriction and vasodilatation. Alterations in vascular innervation can be one of the reasons in regards of the continuity of allergic rhinitis.<sup>[1]</sup> Normally, a constant release of noradrenaline is thought to

**Correspondence:** Sefa Dereköy, Prof., MD. Department of Otolaryngology, Faculty of Medicine, Çanakkale Onsekiz Mart University, Terzioğlu Kampüsü, Fakülte Dekanlığı, Çanakkale, Turkey.  
e-mail: sefaderekoy@gmail.com

**Received:** January 12, 2016; **Accepted:** February 15, 2016

Online available at:  
www.entupdates.org  
doi:10.2399/jmu.2016001006  
QR code:



keep the sinusoidal veins partially contracted due to the fact that the vasoconstrictor effects of stimulation of  $\alpha$ -adrenoreceptors is more evident than vasodilatation after the stimulation of  $\beta$ 2-receptors.<sup>[2]</sup> So, there is a continuous balance between pro-constrictory and pro-dilatory vasoactive forces, which establishes the basal sinusoidal tone. It was suggested that in allergic rhinitis, H3 receptors assist nasal blockage by inhibition of a basal sympathetic vasoconstricting tone.<sup>[3]</sup> Melanin is the basic chromophore of the human iris and it is regarded to be the most important reason which identifies the color of the irises. The melanocytes located in the iris of human and primate eyes take both cholinergic and adrenergic innervation and the adrenergic nervous stimulation has an effect on tyrosinase activity and iris color.<sup>[4]</sup> Retinal pigment epithelium (RPE) is an unilayer of pigment cells that lies between the neural retina and uveal tract and it is accountable for essential metabolic supplement to the whole retina and is in charge of phagocytosis of the photoreceptor outer segment disks. The electro-oculogram (EOG) is a commonly used test that measures the effect of dark and light to the standing potential between RPE and photoreceptor complex providing to evaluate the integrity of the RPE-photoreceptor complex. Arden ratio refers the calculation between the lowest dark adapted point (dark trough) and highest light point (light peak). Reduced Arden ratios of the EOG indicate dysfunction of the photoreceptor retinal pigment epithelium complex.<sup>[5]</sup>

Melanocytes can also play roles as regulators of the immune responses of the skin following UV exposure via providing some cytokines, including TNF- $\alpha$ , IL-1, IL-2 and IL-3, which are mediators also in allergic rhinitis.<sup>[6]</sup> Synnerstad et al.<sup>[7]</sup> found that the children who were reported to have any of the allergic diseases, 79% of them were blonde and 77% were blue eyed and they also found that the children who were reported to have active atopic dermatitis have marked lower nevi than children without atopy. Allergic rhinitis have many common physiopathologic properties with atopic dermatitis, a skin disorder that is successfully cured by phototherapy. Recently, phototherapy is also evaluated as an influential therapy in the management of allergic rhinitis.<sup>[8,9]</sup> These findings suggest that there may be a relationship between allergic disorders and pigmentation. In the present study, it is aimed to determine whether the iris color and RPE influences allergic rhinitis.

## Materials and Methods

This study was planned as a prospective study and implemented in the departments of otolaryngology and ophthalmology. The study was endorsed by the Institutional Ethics

Committee and written informed consent was obtained from each of the patients.

Allergic rhinitis was diagnosed by history, physical examination, prick test (Stallergenes S.A., Cedex, France) and serum IgE results. Allergic rhinitis was diagnosed with the presence of the symptoms such as itchy nose, rhinorrhea, sneezing and nasal congestion. Control group consisted of normal subjects without any systemic or ocular disease.

In all patients, visual acuity was recorded using Snellen chart, and biomicroscopic anterior segment examination was done while the iris color was subjectively defined by two doctors, one was from the ophthalmology department and the other was from the otolaryngology department. Fundus examination was done by a 90 diopters lens. Any patient who had abnormal visual acuity and funduscopy findings was excluded. The EOG test was performed to all subjects according to the ISCEV (International Society for Clinical Electrophysiology of Vision) protocol. After pupil dilatation with topical tropicamide 1% (Tropamid fort, Bilim, Istanbul, Turkey) and phenylephrine hydrochloride 2.5% (Mydrin, Alcon, Fort Worth, TX, USA), EOG was performed (MonElec 2, Metrovision, Perenchies France). The patient head was rested on a chin rest at 33 cm. Four cupula electrodes were placed to the lateral and medial canthus of the right and the left eye. After a dark phase of 12 minutes, light phase lasting 12 minutes was performed. So, 8 saccades under dark conditions and 8 saccades under light conditions were completed. Saccade amplitude was 50 degrees and light phase was performed at 100 cd/m<sup>2</sup>. After the test was completed, the light peak/dark trough ratio (Arden ratio) was recorded. Arden ratios were compared for two groups and evaluated according to the iris colors.

Statistical analysis was performed using the Statistical Package for Social Sciences 10.0 for Windows (SPSS Inc., Chicago, IL, USA). Comparison of two groups for iris color was computed by Mann-Whitney U test. Mean Arden ratios between two groups were evaluated by independent samples t-test. Iris color distribution between the groups was evaluated by chi-square test. Within each group, change in mean Arden ratio according to the iris color was calculated by Kruskal-Wallis test. At all times, p values <0.05 were regarded as statistically significant.

## Results

Ninety-nine patients with allergic rhinitis were included in the study. The control group consisted of 85 normal subjects. Mean age was 29.44 $\pm$ 9.8 years in the study group, whereas it was 32.67 $\pm$ 12.9 years in the control group (p>0.05). In the study group, 68 (62.4%) patients were

female and 31 (41.3%) were male, whereas in the control group, 41 (37.6%) subjects were female and 44 (58.7%) subjects were male.

In the study group, color of iris was not recorded in 6 subjects. For the recorded patients with allergic rhinitis, 39 (41.9%) subjects had brown iris, 38 (40.9%) subjects had hazel iris and 16 (17.2%) subjects had blue iris. In the control group, 57 (67.1%) subjects had brown iris, 16 (18.8%) subjects had hazel iris and 12 (14.1%) subjects had blue iris ( $p < 0.05$ ) (Fig. 1). Numbers of hazel iris and blue-colored iris were significantly higher in the study group compared to brown iris ( $p < 0.05$ ). Brown iris was found to be lower in the patients with allergic rhinitis.

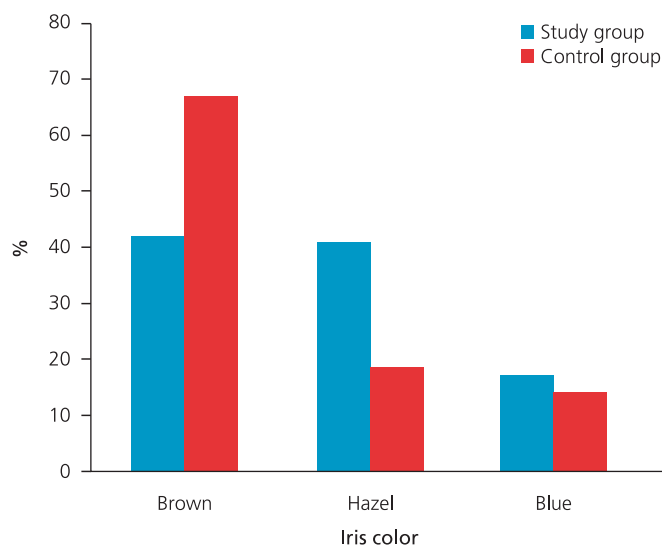
Mean Arden ratio was found to be significantly lower in the study group. It was  $158.22 \pm 29.4$  (107–227) in the study group and  $179.34 \pm 29.3$  (143–243) in control group ( $p < 0.05$ ). Mean Arden ratio in groups according to iris color was given in Table 1. Arden ratio was found to be significantly lower in brown iris in the patients with allergic rhinitis as compared to study group, while no differences were present for the hazel and blue irises between the two groups. In the study group, Arden ratio was lower in subjects with brown iris compared to hazel and blue iris ( $p < 0.05$  and  $p < 0.05$  respectively), whereas there was no significant difference between hazel and blue irises ( $p > 0.05$ ). In the control group, Arden ratio was significantly lower in subjects with hazel or blue iris compared to brown iris ( $p < 0.05$  and  $p < 0.05$  respectively), whereas there was no significant difference between hazel and blue irises ( $p > 0.05$ ).

## Discussion

In this study, we attempted to demonstrate whether there was a relationship between allergic rhinitis and melanin content of iris and RPE. To the extent of our knowledge, this is the first study in English literature that showed an association between allergic rhinitis and melanin content of iris and RPE.

The present study shows that the ratio of brown iris in the patients with allergic rhinitis is significantly lower, whereas the percentages of hazel and blue irises are found to be significantly higher. This result shows that the light-colored eye has higher risk for the development of allergic rhinitis so that decreased melanin pigment content in the iris is related with increased incidence of allergic rhinitis.

The wall of the human eye is composed of three parts, the retina, the uveal tract, and the opaque white sclera and transparent cornea. The uveal tract further consists of three



**Fig. 1.** Distribution of the iris colors among the patient and the control groups.

layers, from anterior to posterior—the iris, the ciliary body and the choroid. Pigmented cells are divided into two-different types—the pigment cells and the uveal melanocytes localized in the uveal tract. The uveal melanocytes also consist of iridal, ciliary and choroidal melanocytes. The melanocytes in human iris produce both the reddish-yellow pheomelanin and brown-black eumelanin. The melanin content in the iridal melanocytes is the most important distinctive mark of the eye color. Despite the number of melanocytes in brown, hazel and blue irises have been reported to be very comparable, the quantity of uveal melanin in eyes with dark-colored irises (dark brown and brown) is much more than that in light-colored eyes (yellow-brown, green, hazel and blue).<sup>[10]</sup> Darker irises have larger granule density and greater melanin granules. Lower tyrosinase activity and melanin content were reported in

**Table 1.** Mean Arden ratio in groups according to iris color.

Iris color	Allergic rhinitis (n=99)	Control group (n=85)	p1
All	158.22±29.4	179.34±29.3	<0.05
Brown	148.36±21.8	187.86±31.1	<0.05
Hazel	167.00±37.0	163.25±17.2	>0.05
Blue	162.50±19.5	160.33±9.9	>0.05
p2	<0.05	<0.05	

p1: Independent samples t-test; p2: Kruskal-Wallis test.

uveal melanocytes cultured from light-colored irises.<sup>[11]</sup> The melanosomes are the organelles that contain melanin in the pigment cells, and are involved with lysosomes. While the melanosomes are few and often not fully developed in the iridial melanocytes of blue-eyed individuals, they are a lot and of grade III–IV in brown-eyed individuals.<sup>[12]</sup>

The iris which is certain in Caucasian infants begins with a clear blue color and then becomes brown in the more melanized persons or remains blue in the less melanized ones.<sup>[13]</sup> As far as the eye is exposed to sunlight, melanin pigment is started to be produced by the iris and color of the eye progressively changes towards the color of the adult stage and pigmentation is completed by age 3. At post early childhood and during adulthood, the eye color may change in 10–15% of Caucasians. As the eye color itself, the tendency to change the eye color may be an inherited trait. Depigmentation and or atrophy of the iris can be seen in various non-inflammatory and inflammatory status including trauma, Horner's syndrome, Waardenburg syndrome, acute angle closure glaucoma, viral iridocyclitis and Fuchs' uveitis syndrome.<sup>[14]</sup> It is very interesting that the generally accepted treatment of glaucoma relied on  $\beta$ -adrenergic blockers, selective  $\alpha$ -adrenergic agonists (e.g. clonidine) and prostaglandin analogues. Latanoprost, a prostaglandin F2 $\alpha$  derivative that has been used successfully for the glaucoma treatment has an interesting side effect; an iridial pigmentation increase in 5–15% of the patients, even the highest number of side effects has occurred in patients with heterochromatic (e.g. green/brown or blue/brown) or hazel eye color.<sup>[15]</sup> Besides the iridial pigmentation side effect, in some patients, latanoprost have been shown to result in longer and darker eye lashes.<sup>[16]</sup> Similarly, physical examination of the head in allergic rhinitis may reveal some characteristic findings such as dark discoloration under the eyes, or "allergic shiners" which is attributed to venous engorgement.<sup>[17]</sup> In individuals with allergic rhinitis, concentrations of prostaglandins PGE2 and PGD2 are found to be increased following allergen challenge in lavage fluid.<sup>[1]</sup> Also, in addition to epinephrine, three beta-adrenergic agonists; isoproterenol, salbutamol and metaproterenol have recently been demonstrated to lead to evident proliferation of iridial melanocytes in vitro, raising the number of the cells around 300%.<sup>[18]</sup> In Horner's syndrome which occurs as a result of a lesion anywhere along the oculosympathetic pathway, McCartney et al.<sup>[19]</sup> found that there was marked lack of sympathetic axons and the number of stromal melanocytes was reduced in the affected eye. Melanocytes are in close relationship to adrenergic innervation and

adrenergic agonist agents stimulate melanogenesis and growth in uveal melanocytes. Nasal obstruction and rhinorrhoea were reported symptoms associated with Horner's syndrome and cervical sympathetic paralysis.<sup>[20]</sup> Nasal congestion was seen following cervical sympathectomy and antihypertension drugs, whereas basal activation of  $\alpha$ 1-adrenoceptors prevented "automatic" nasal blockage.<sup>[3]</sup>

Mean Arden ratio was found to be significantly lower in the patients diagnosed with allergic rhinitis as compared to the control group. Meanwhile, Arden ratio was decreased more in the patients with brown iris compared to hazel and blue iris in the study group. This present result indicates that melanin content decreased in RPE of the patients with allergic rhinitis. The EOG is believed to show RPE and rod/cone interactions of the human eye, hence it was regarded to be an effective non-invasive diagnostic instrument.<sup>[5]</sup> The lower EOG dark trough values have been determined in albinism, which is characterized with congenital decline or total absence of pigment in eyes, skin and hair.<sup>[21]</sup> On the other hand; in neurofibromatosis type 1 disease which includes hyperpigmented skin lesions, cutaneous and plexiform neurofibromas, Lisch nodules and optic gliomas, the Arden ratios of the EOG test were considerably higher.<sup>[22]</sup>

Retina pigment epithelium is a monolayer of cells that are linked by tight junctions near the apical surface. These junctions separate the basal and apical membranes of the pigment epithelium, which have different ionic permeability characteristics that lead to the generation of a voltage across the cell. This voltage, called the standing potential, is positive at the cornea and measures 6–10 mV. The change in this voltage throughout the human eye stimulated by the alteration of illumination constitutes the base of the clinical EOG. The EOG needs RPE membrane integrity, however it is not a pure test of RPE function, as photoreception of the retina is necessary and as the light response is not known to be related with any specific retinal or RPE function (including vision, visual pigment regeneration and RPE water transport).<sup>[23]</sup> In EOG, a light rise is due to the release of a substance which prompts an increase in the intracellular calcium concentration within the RPE. Increase of intracellular calcium results in basal membrane depolarization by opening a basolateral ionic Cl<sup>-</sup> channel. Most of the fluid regulation in the RPE is managed by calcium-gated Cl<sup>-</sup> channels and the aquaporins, expressed also by cultured normal human nasal epithelial cells.<sup>[24]</sup> The EOG changes in response to mannitol, acetazolamide, alcohol, hypoxia, and hyperoxia have all been investigated as potentially available non-photic stim-



uli which directly influence the RPE. These results demonstrate the metabolic influences on the transepithelial potential of the RPE.<sup>[25]</sup> Adrenergic and muscarinic receptors have been demonstrated at the apical membrane of the RPE and a mechanism on the RPE apical surface is obviously a “receptor” for epinephrine, even at micromolar concentration.<sup>[26]</sup> Melanin in RPE is involved in many important functions including light protection, protection from oxidative stress, detoxification of peroxides. While the light-colored eye is risky for the development of uveal melanoma, the lower incidence of age-related macular degeneration in dark-colored eyes can be involved with lower light intensity that can reach to the retina.

Ultraviolet irradiation (UVR) is a major stimulus of facultative pigmentation. Melanocyte, a kind of specialized dendritic cell can secrete a large number of signal molecules such as cytokines (nitric oxide, TNF- $\alpha$ , IL-1, IL-3 and IL-6), serotonin, eicosanoids, and catecholamines, in response to UVR. Phototherapy can effectively attenuate the effector stage of allergic rhinitis at different checkpoints by inhibiting secretion and synthesis of pro-inflammatory mediators, by inducing apoptosis of the immune cells (T and B cells, eosinophils and dendritic cells) and by decreasing the antigen presenting capacity of the dendritic cells.<sup>[27]</sup>

Synnerstad et al.<sup>[7]</sup> found that the children with atopic dermatitis have significantly fewer nevi than children without atopy. They reported that why children with atopic dermatitis have few nevi is not known, whereas the reason might be due to altered immune responses, genetic factors or effect of various treatments including UVR and topical steroids. They postulated that the pro-inflammatory cytokines in the atopic skin may influence melanocyte growth and/or progression to nevi negatively. Awaya et al. found that people exhibiting conspicuous nevi are resistant to pollinosis and suggested that people who have weak nevi-producing systems are more susceptible to pollinosis and that systems inducing the occurrence of pollinosis and those producing nevi are competing with each other, so that nevi may delay or inhibit the occurrence of pollinosis.<sup>[28]</sup>

It could be thought that there was no relationship between nasal mucosa and the human eye. Everett<sup>[29]</sup> reported that sneezing can be produced by exposure of the eyes to bright light. Moreover, Ozsutcu et al.<sup>[30]</sup> reported that the pupil size in response to photic stimuli in children with allergic rhinitis was smaller than that of the control group and may indicate parasympathetic hyperactivity and sympathetic hypoactivity. Several hypotheses such as common adrenergic control or ion channels could be devel-

oped to explain the relationship between allergic rhinitis and melanin content of iris and RPE, whereas further studies are needed to confirm.

Our study being relatively small size of our subjects, lack of definite criteria for selection of patients, lack of demographic data regarding especially lifestyle, geographic and climatic reasons, and finally being a single-center study were the limitations of this study. However, we hope that this study will pioneer not only further studies about the relationship between the iris color and the allergic rhinitis, but also to better understanding of pathophysiologic mechanisms of allergic rhinitis.

As Tsatmali et al.<sup>[31]</sup> proposed that the pigment system plays a modulating, down-regulating response to all forms of cutaneous inflammation whether induced by sunlight, infections, or injuries; we can speculate that pigment-producing system may have a role in the pathophysiology of allergic rhinitis.

**Conflict of Interest:** No conflicts declared.

## References

1. Al Suleimani YM, Walker MJ. Allergic rhinitis and its pharmacology. *Pharmacol Ther* 2007;114:233–60.
2. Dahl R, Mygind N. Anatomy, physiology and function of the nasal cavities in health and disease. *Adv Drug Deliv Rev* 1998;29:3–12.
3. Taylor-Clark TE. Insights into the mechanisms of histamine-induced inflammation in the nasal mucosa. *Pulm Pharmacol Ther* 2008;21:455–60.
4. Stjernschantz JW, Albert DM, Hu DN, Drago F, Wistrand PJ. Mechanism and clinical significance of prostaglandin-induced iris pigmentation. *Surv Ophthalmol* 2002;47 Suppl 1:S162–75.
5. Arden GB, Constable PA. The electro-oculogram. *Prog Retin Eye Res* 2006;25:207–48.
6. Nordlund JJ. The melanocyte and the epidermal melanin unit: an expanded concept. *Dermatol Clin* 2007;25:271–81.
7. Synnerstad I, Nilsson L, Fredrikson M, Rosdahl I. Fewer melanocytic nevi found in children with active atopic dermatitis than in children without dermatitis. *Arch Dermatol* 2004;140:1471–5.
8. Koreck AI, Csoma Z, Bodai L, et al. Rhinophototherapy: a new therapeutic tool for the management of allergic rhinitis. *J Allergy Clin Immunol* 2005;115:541–7.
9. Leong SC. Rhinophototherapy: gimmick or an emerging treatment option for allergic rhinitis? *Rhinology* 2011;49:499–506.
10. Wakamatsu K, Hu DN, McCormick SA, Ito S. Characterization of melanin in human iridal and choroidal melanocytes from eyes with various colored irides. *Pigment Cell Melanoma Res* 2008;21:97–105.
11. Hu DN, McCormick SA, Orlov SJ, Rosembat S, Lin AY, Wo K. Melanogenesis by human uveal melanocytes in vitro. *Invest Ophthalmol Vis Sci* 1995;36:931–8.

12. Eagle RC, Jr. Iris pigmentation and pigmented lesions: an ultra-structural study. *Trans Am Ophthalmol Soc* 1988;86:581–687.
13. Bito LZ, Matheny A, Cruickshanks KJ, Nondahl DM, Carino OB. Eye color changes past early childhood. The Louisville Twin Study. *Arch Ophthalmol* 1997;115:659–63.
14. Tugal-Tutkun I, Urgancioglu M. Bilateral acute depigmentation of the iris. *Graefes Arch Clin Exp Ophthalmol* 2006;244:742–6.
15. Wistrand PJ, Stjernschantz J, Olsson K. The incidence and time-course of latanoprost-induced iridial pigmentation as a function of eye color. *Surv Ophthalmol* 1997;41 Suppl 2:S129–38.
16. Johnstone MA. Hypertrichosis and increased pigmentation of eyelashes and adjacent hair in the region of the ipsilateral eyelids of patients treated with unilateral topical latanoprost. *Am J Ophthalmol* 1997;124:544–7.
17. Weis E, Shah CP, Lajous M, Shields JA, Shields CL. The association between host susceptibility factors and uveal melanoma: a meta-analysis. *Arch Ophthalmol* 2006;124:54–60.
18. Hu DN, Woodward DF, McCormick SA. Influence of autonomic neurotransmitters on human uveal melanocytes in vitro. *Exp Eye Res* 2000;71:217–24.
19. McCartney AC, Riordan-Eva P, Howes RC, Spalton DJ. Horner's syndrome: an electron microscopic study of a human iris. *Br J Ophthalmol* 1992;76:746–9.
20. Takanashi J, Tada H, Tomita M, et al. Contralateral rhinorrhea as a feature of infantile Horner's syndrome. *Neurology* 2003;61:1309–10.
21. Reeser F, Weinstein GW, Feiock KB, Oser RS. Electro-oculography as a test of retinal function. The normal and supernormal EOG. *Am J Ophthalmol* 1970;70:505–14.
22. Lubinski W, Zajaczek S, Sych Z, Penkala K, Palacz O, Lubinski J. Electro-oculogram in patients with neurofibromatosis type 1. *Doc Ophthalmol* 2001;103:91–103.
23. Marmor MF. Standardization notice: EOG standard reappraised. *Electro-oculogram*. *Doc Ophthalmol* 1998;95:91–2.
24. Jun ES, Kim YS, Yoo, Roh HJ, Jung JS. Changes in expression of ion channels and aquaporins mRNA during differentiation in normal human nasal epithelial cells. *Life Sci* 2001;68:827–40.
25. Boulton M, Dayhaw-Barker P. The role of the retinal pigment epithelium: topographical variation and ageing changes. *Eye (Lond)* 2001;15:384–9.
26. Joseph DP, Miller SS. Alpha-1-adrenergic modulation of K and Cl transport in bovine retinal pigment epithelium. *J Gen Physiol* 1992;99:263–90.
27. Kemeny L, Koreck A. Ultraviolet light phototherapy for allergic rhinitis. *J Photochem Photobiol B* 2007;87:58–65.
28. Awaya A, Watanabe K, Kato S. Individuals exhibiting conspicuous nevi (lentigo simplex) are resistant to allergic rhinitis/conjunctivitis (pollinosis), but those who do not show increased susceptibility to pollinosis. *Microbiol Immunol* 2003;47:101–3.
29. Everett HC. Sneezing in response to light. *Neurology* 1964;14:483–90.
30. Ozsutcu M, Ozkaya E, Demir A, Erenberk U, Sogut A, Dundaroz R. Pupillometric assessment of autonomic nervous system in children with allergic rhinitis. *Med Princ Pract* 2013; 22:444–8.
31. Tsatmali M, Ancans J, Thody AJ. Melanocyte function and its control by melanocortin peptides. *J Histochem Cytochem* 2002; 50:125–33.

This is an open access article distributed under the terms of the Creative Commons Attribution-NonCommercial-NoDerivs 3.0 Unported (CC BY-NC-ND3.0) Licence (<http://creativecommons.org/licenses/by-nc-nd/3.0/>) which permits unrestricted noncommercial use, distribution, and reproduction in any medium, provided the original work is properly cited.

*Please cite this article as:* Dereköy S, Kenar F, Yavaş GF, Küsbeci T, Öztürk F, Ayçiçek A. The influence of iris color and retina pigment epithelium melanin on allergic rhinitis. *ENT Updates* 2016;6(1):23–28.