

Case Report

Pulmonary Langerhans Cell Histiocytosis Case with Diabetes Insipidus and Tuberculosis

E Ugurlu, G Altinisik, U Aydogmus¹, F Bir²

Pamukkale University,
Medicine Faculty, Chest
Disease Department,
¹Pamukkale University,
Medicine Faculty, Thoracic
Surgery Department,
²Pamukkale University,
Medicine Faculty, Pathology
Department, Denizli, Turkey

ABSTRACT

A 19-year-old male patient was observed due to having central diabetes insipidus (DI) for five years. He had a history of smoking 5–10 cigarettes a day for two years, but stopped smoking from the last month. The computerized tomography revealed thin-walled cystic lesions in different sizes more dominantly in the upper lobes and consolidated areas in the left upper and lower lobes. The wedge resection from the right lower lobe revealed pulmonary langerhans cell histiocytosis. Follow-up acid-fast bacteria (AFB) examinations revealed (+++) and antituberculous treatment was started. On the 40th day of the anti-tuberculosis treatment, the patient applied once again due to fever and chest pain. Although infiltrations persisted in the left upper and middle zones in the postero-anterior lung roentgenogram, right-sided pneumothorax was detected. The case is considered tuberculosis and the patient continued to receive anti-TB treatment under the close supervision.

KEYWORDS: *Diabetes insipidus, Langerhans cell histiocytosis, Lung, Tuberculosis, Pneumothorax*

Acceptance Date: 12-07-2016

INTRODUCTION

Langerhans cell histiocytosis (LCH) is a rare disease caused by the proliferation of dendritic cells and macrophages belonging to the mononuclear phagocytic system.^[1] The skin, oral cavity, bone, pituitary gland, spleen, abdomen, and gastrointestinal tract, bone marrow, lungs, and central nerve system may be affected.^[2] Central diabetes insipidus may develop with the exposure of the posterior side of the pituitary gland.^[2] The presented pulmonary langerhans cell histiocytosis (PLCH) case had unique features like a mild history of smoking that possibly triggered the disease at an early age, the differential location of consolidation, accompanying tuberculosis (TB), and central diabetes insipidus.

CASE

A 19-year-old male patient was followed due to having central diabetes insipidus (DI) for five years. The patient applied to the department of pediatric nephrology and was given nasal spray involving desmopressin after being diagnosed with DI because of low urine density and a positive result of the thirst test. The DI dependent complaints of the patient were under control with desmopressin. The patient applied to the emergency service with complaints of a dry cough for two months,

difficulty in breathing increasing with effort, and fever particularly at night. Pneumonia was considered as the initial diagnosis.

There were no significant findings in his physical examination. The patient had a short and light smoking history (5-10 cigarettes a day for 2 years) and he stopped smoking for the last month. He did not declare any disease in his family history.

A non-homogeneous consolidation area with melting zones inside, which started from the hilar region on the left upper and middle zones and extends towards periphery, was seen in the posteroanterior (PA) radiography, as shown in Figure 1. In the computerized tomography, thin - walled cystic lesions in different sizes were seen more dominantly in the upper lobes and consolidated area were seen left upper lobe [Figure 2]. Cystic lesions were seen not spared lower lung and consolidated area were seen left lower lobe [Figure 3].

Address for correspondence: Dr. Erhan Ugurlu, Pamukkale Universitesi Tıp Fakultesi, Göğüs Hastalıkları AD, Göğüs Hastalıkları Polikliniği, Denizli, Türkiye,
E-mail: drerhanugurlu@gmail.com

This is an open access article distributed under the terms of the Creative Commons Attribution-Non Commercial-Share Alike 3.0 License, which allows others to remix, tweak, and build upon the work non-commercially, as long as the author is credited and the new creations are licensed under the identical terms.

For reprints contact: reprints@medknow.com

How to cite this article: Ugurlu E, Altinisik G, Aydogmus U, Bir F. Pulmonary langerhans cell histiocytosis case with diabetes insipidus and tuberculosis. *Niger J Clin Pract* 2017;20:503-6.

Access this article online	
Quick Response Code: 	Website: www.njcponline.com
	DOI: 10.4103/1119-3077.204379

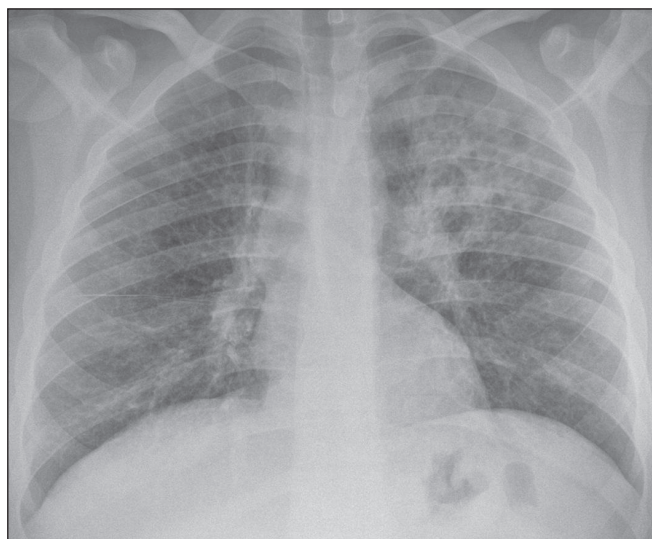


Figure 1: A non-homogeneous consolidation area with melting zones inside, which started from the hilar region on the left upper and middle zones and extends towards periphery.

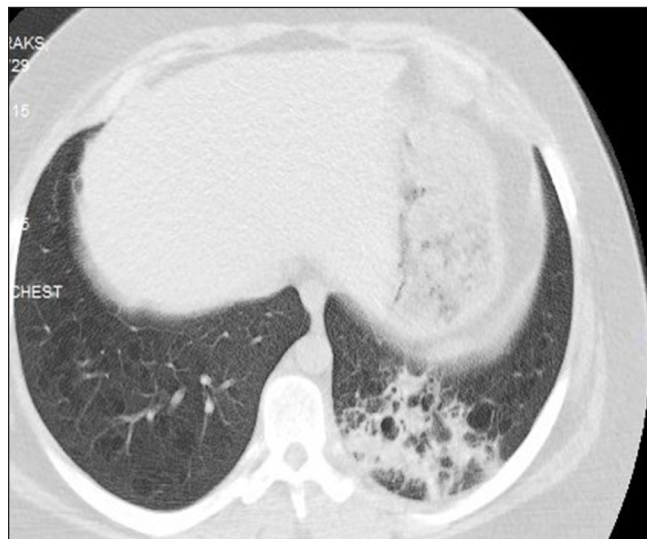

Figure 3: Cystic lesions were seen not spared lower lung and consolidated area were seen left lower lobe.

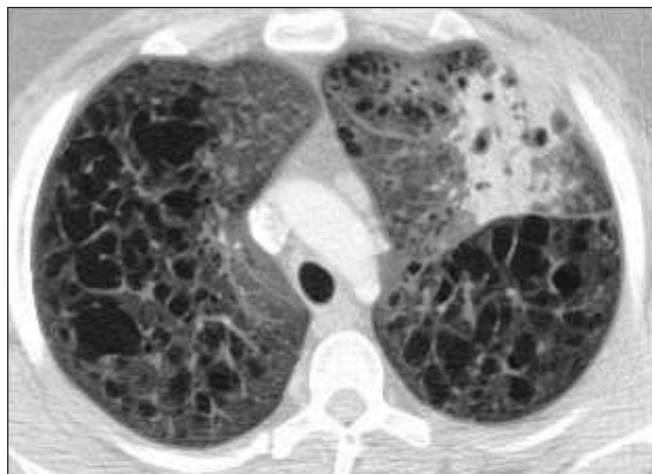

Figure 2: Thin-walled cystic lesions in different sizes were seen more dominantly in the upper lobes and consolidated area were seen in the left upper.

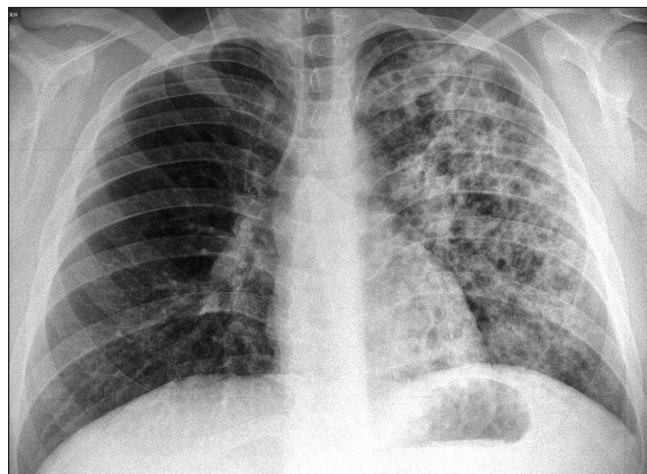


Figure 4: An increase of infiltrations in the control PA radiography.

Endobronchial lesion was not seen and no pathological area was determined in bronchoscopy. Bronchoalveolar lavage (BAL) was implemented. The BAL results found neutrophil leukocytes [4%], eosinophil [6%], lymphocyte [10%], and alveolar macrophage [80%]. A laboratory examination showed white blood cell count 9790/ μ L, hemoglobin 11.9 g/dL, C-reactive protein 5.2 mg/dL, Na: 141 mmol/L, K: 4.44 mmol/L, Cl: 105 mmol/L, and Ca: 8.83 mmol/L. Treatment with cefoperazone/sulbactam, meropenem, teicoplanin, and linezolid antibiotics were administered upon the persistence of the fever, but without success. As shown in Figure 4, there was an increase of infiltrations in the control PA radiography.

Right lung wedge resection with video-assisted thoracoscopic surgery (VATS) was implemented for

an exact diagnosis. In the macroscopic examination, cysts of various sizes and shapes were seen in the lung parenchyma, as shown in Figure 5A.

In the walls of some of the cysts in the fractions prepared from the lung parenchyma, which included cystic cavities, the cerebriform created nodular structures by following small airways; atypical cell clusters having notched nucleuses, with wider eosinophilic cytoplasm than inflammatory cells and compatible with Langerhans cells; and inflammatory cell infiltration comprised of eosinophils and lymphocytes. In the immunochemical examination, the atypical cells that created infiltration were stained positively with S100 and CD1a [Figure 5 B-D]. Emphysematous cavities characterized with septal destruction in lung parenchyma, anthracosis

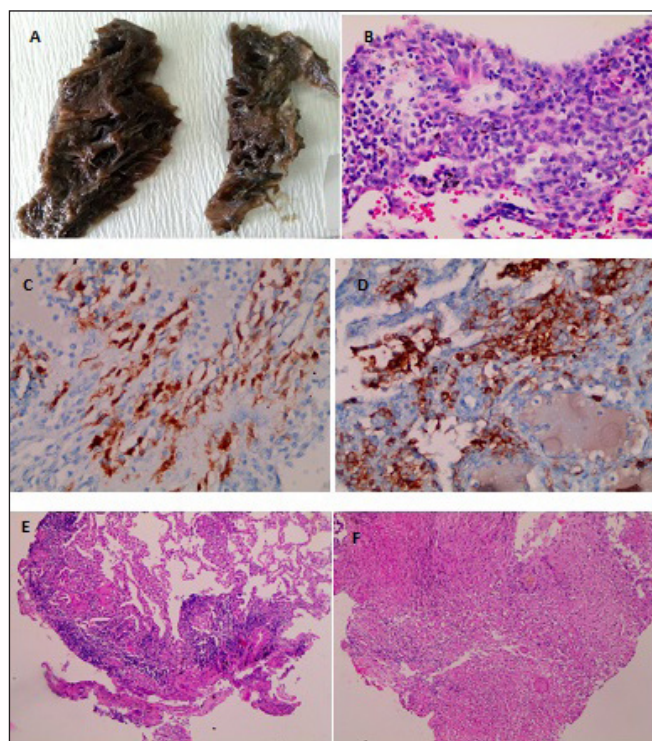


Figure 5: (a) Lung parenchyma involving distinct cystic dilatations. (b) Eosinophils and lymphocyte localized on the wall of cysts in lung parenchyma and infiltration consisting of Langerhans cells (c) S-100 positive Langerhans cells (d) CD-1a positive Langerhans cells (e) Granulomas consisting of epithelioid histiocytes (f) Granulomas inside the fibrous tissue.

laden macrophage clusters filling some alveoli around bronchioles, and characteristic respiratory bronchiolitis areas were determined in the fragments prepared from the lung parenchyma with natural appearance macroscopically. Based on these findings, the patient was diagnosed with PLCH.

One week later, the patient returned with fever and an AFB smear of phlegm was found (+++). The consolidated areas were identified with TB infection and an anti-TB treatment including isoniazid, rifampicin, ethambutol, and pyrazinamide was started. Reproduction was determined in the *mycobacterium tuberculosis* culture sent one week after the hospitalization of the patient. On the 40th day of the anti-TB treatment, the patient returned once again due to fever and chest pain. Although infiltrations persisted in the upper left and middle zones in the PA radiography, right-sided pneumothorax was detected, as shown in Figure 6. A chest tube was inserted and the AFB sputum test was negative. Bronchoscopy was performed again for persisting infiltrations.

In the sections prepared from transbronchial biopsy, epithelioid histiocytes and granuloma structures consisting of giant cells were observed inside the lung parenchyma and fibrous connective tissue. Necrosis was

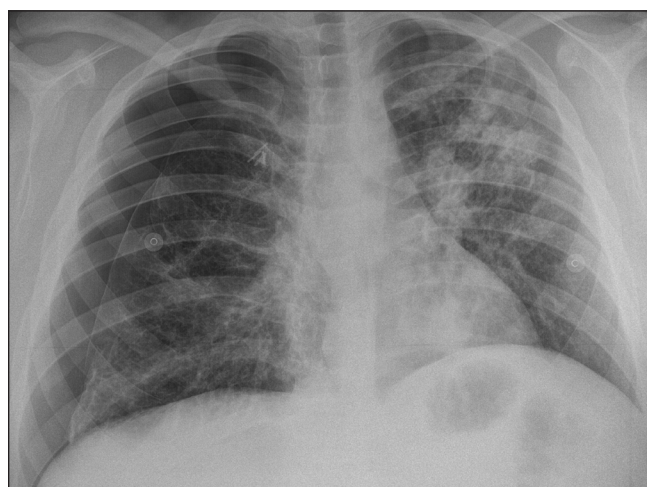


Figure 6: Right-sided pneumothorax.

not detected. There were no microorganisms stained with gram, PAS, and EZN dyes histochemically. Consequently, the patient was diagnosed with chronic granulomatous infection [Figure 5] E,F. The clinical presentation of the case was considered TB and the patient is still receiving anti-TB treatment under close supervision.

DISCUSSION

PLCH is seen more frequently in males and people younger than 40 years of age. Eighty percent of the patients are currently smokers or have a history of smoking.^[3] Patients often arrive at the hospital complaining of cough and shortness of breath. Some patients may arrive due to pneumothorax as well.^[4] Our patient had a short history of smoking and was only diagnosed with PLCH because of his complaints related to TB. If he had not expressed TB-related complaints, the disease might have proceeded asymptotically for many years.

Around 15% of the patients with PLCH may apply due to extrapulmonary manifestations such as bone involvement and central DI.^[4] One of the studies diagnosed a patient at the age of 42, who applied with the complaints of polyphagia, polydipsia, dry cough, and shortness of breath, with central diabetes insipidus and VATS and PLCH through the thirst test.^[5] In contrast to our patient, the patient was diagnosed with two different diseases simultaneously. Another study presented three patients diagnosed with DI, who were then diagnosed with PLCH shortly after, 1 year later, and 3 years later, respectively.^[6] Our patient was diagnosed with PLCH 5 years after the diagnosis of central DI. The reason for this delay could be the inability to perform further examinations due to the very limited aspects of DI that arise from LCH, or the asymptomatic nature of other system effects because they are still in the early stages. The records of our

patient show that no further examinations intended for the DI etiology were performed.

The most common radiological appearances of adult patients with PLCH are the nodule and cysts localized mostly in the upper lobes, while the costophrenic sinuses were spared.^[7] PLCH in childhood is linked to costophrenic sinuses.^[8] The severity of the disease is determined by the number and size of these nodules and cysts.^[7] Since the costophrenic angle was spared in our patient, the adult type PLCH was probably considered based on his smoking habit, rather than the pediatric type.

The short and light smoking history of our patient and the DI diagnosis he received 5 years ago cast doubt on the diagnosis of non-smoking related PLCH that started in childhood and was diagnosed late. However, another study presented the characteristics of two patients diagnosed with LCH and then PLCH, in childhood and adulthood respectively, and reported that both patients did not smoke before the diagnosis, though they smoked 20 cigarettes a day over the last 3 years.^[9]

The deterioration in the function of alveolar macrophages in diseases damaging the lung forms the basis for the infection of TB because of the problems in PLCH, hystiocytes, and macrophages, but there are no known prevalence studies showing co-infection in patients with PLCH.^[10]

Although rare, atypical manifestations such as consolidations may be seen in PLCH patients.^[11] A transbronchial biopsy showed that the consolidation area was associated with TB. In the literature, there have been only four cases of TB in association with PLCH up to now.

As far as we know, this man is the first patient reported in the literature to have DI, PLCH, and TB. Considering the presence of LCH, further examinations should be

made in patients who are diagnosed central DI, and *mycobacterium tuberculosis* must be considered in the existing consolidations in patients with PLCH.

Financial Support and Sponsorship

Nil

Conflicts of Interest

None

REFERENCES

1. Wei P, Lu HW, Jiang S, Fan LC, Li HP, Xu JF. Pulmonary langerhans cell histiocytosis: case series and literature review. *Medicine (Baltimore)* 2014;93:141.
2. Grana N. Langerhans cell histiocytosis. *Cancer Control* 2014;21:328-34.
3. Jawad H, Walker CM, Wu CC, Chung JH. Cystic interstitial lung diseases: recognizing the common and uncommon entities. *Curr Probl Diagn Radiol* 2014;43:115-27.
4. Ryu JH, Tian X, Baqir M, Xu K. Diffuse cystic lung diseases. *Front Med* 2013;7:316-27.
5. Choi YS, Lim JS, Kwon W, Jung SH, Park IH, Lee MK, *et al.* Pulmonary Langerhans Cell Histiocytosis in an Adult Male Presenting with Central Diabetes Insipidus and Diabetes Mellitus: A Case Report. *Tuberc Respir Dis (Seoul)* 2015;78:463-8.
6. Fuks L, Kramer MR, Shitrit D, Raviv Y. Pulmonary Langerhans cell histiocytosis and diabetes insipidus in pregnant women: our experience. *Lung* 2014;192:285-87.
7. Trotman-Dickenson B. Cystic lung disease: achieving a radiologic diagnosis. *Eur J Radiol* 2014;83:39-46.
8. Bano S, Chaudhary V, Narula MK, Anand R, Venkatesan B, Mandal S. Pulmonary Langerhans cell histiocytosis in children: a spectrum of radiologic findings. *Eur J Radiol* 2014;83:47-56.
9. Bernstrand C, Cederlund K, Ashtröm L, Henter JI. Smoking preceded pulmonary involvement in adults with Langerhans cell histiocytosis diagnosed in childhood. *Acta Paediatr* 2000;89:1389-92.
10. Farazi A, Jabbariasl M. Silico-tuberculosis and associated risk factors in central province of Iran. *Pan Afr Med J* 2015;20:333.
11. Ko SM, Choe BK, Kim HS, Lee HJ, Kwon KY. Atypical radiological manifestations of pulmonary Langerhans cell histiocytosis in a 12-year-old girl. *Br J Radiol* 2008;81:238-41.