

Distal medial tibial locking plate for fixation of extraarticular distal humeral fractures; an alternative choice for fixation



Ali Cagdas Yorukoglu ^a, Ahmet Fahir Demirkan ^{a,*}, Nihal Buker ^b

^a Pamukkale University, Faculty of Medicine, Department of Orthopedics and Traumatology, Pamukkale, Denizli, Turkey

^b Pamukkale University, School of Physical Therapy and Rehabilitation, Pamukkale, Denizli, Turkey

ARTICLE INFO

Article history:

Received 10 May 2017

Received in revised form

17 January 2018

Accepted 26 February 2018

Available online 4 May 2018

Keywords:

Distal humeral fractures

Distal tibial locking plate

Fixation

Osteosynthesis

Extraarticular

Distal humerus

ABSTRACT

Objective: The aim of this study was to describe an alternative fixation method for distal humeral extra-articular fractures through posterior approach using distal tibia anatomic locking plate; and to evaluate the patient's functional outcome and union condition.

Methods: Eighteen patients (11 men and 7 women; average age of 37.0 ± 17.3 years (range: 18–73 years)) with a distal humeral extra-articular fracture who were treated with distal tibial medial locking plate were included into the study. The mean follow up time was 36.2 ± 16.7 (12–57) months. Functional results were evaluated with perception of pain, range of joint motion, grasp and pinch strengths.

Results: Union was achieved in 17 of 18 patients. Only one patient had non-union due to infection and underwent debridement. The mean time for union was 7.8 ± 5.9 months (2–20). Patient perception of pain was $X = 1.88 \pm 2.50$ and $X = 4.55 \pm 2.68$, respectively, at rest and activity. The active ranges of joint motion were adequate for functional use. General functional state of affected extremity (DASH-T) was perfect ($X = 27.14 \pm 25.66$), the performance of elbow joint was good ($X = 84.44 \pm 11.57$). There were no differences in the comparison of grasp and pinch grip of patients with uninvolved extremity ($p > 0.05$).

Conclusions: In distal humeral extra-articular fractures, use of distal medial tibia plate has advantages such as providing high rates for union, low rates for complication, and early return to work with early rehabilitation, therefore it may be considered a fixation choice that can be used for distal humeral extra-articular fractures.

Level of evidence: Level IV, therapeutic study.

© 2018 Publishing services by Elsevier B.V. on behalf of Turkish Association of Orthopaedics and Traumatology. This is an open access article under the CC BY-NC-ND license (<http://creativecommons.org/licenses/by-nc-nd/4.0/>).

Introduction

The humeral shaft fractures account for 3% of overall orthopedic injuries, resulting in social and functional losses.¹ The majority of humeral shaft fractures can be treated conservatively with high union rates and good functional results.² Surgical treatment is generally reserved for open fractures, floating elbow injuries, fractures associated with vascular injuries, unacceptable alignment and failure of conservative treatment.^{3,4} Although there are many surgical options, fixation with plate-screw remains to be golden

standard in surgical treatment of distal humeral shaft fractures.⁵ Fixation of distal humerus fractures can be problematic due to the muscle forces acting on the fracture line and unique morphology of the distal humerus. Depending on the fracture pattern a short distal fracture segment allows limited opportunities for fixation; for this reason selection and application of the plate can be difficult.⁶ In distal fractures, conventional 4.5 mm shaft plates allows placement of one or two screws in the distal fragment, often resulting in an insufficient fixation.^{7–9} This study describes an alternative fixation method for distal humeral extra articular fractures through posterior approach using medial tibia anatomic locking plate; and evaluates the patient's functional outcome and union condition.

Material and method

The study is approved by the local ethical committee. An informed consent was obtained from all the patients. Patients

* Corresponding author. Pamukkale University, Faculty of Medicine, Department of Orthopedics and Traumatology, 20070, Pamukkale, Denizli, Turkey. Tel: + 90 (258) 296 5668. Fax: +90 258 213 10 34.

E-mail addresses: alicagdasyorukoglu@gmail.com (A.C. Yorukoglu), fahirdemirkan@yahoo.com (A.F. Demirkan), nasuk@gmail.com (N. Buker).

Peer review under responsibility of Turkish Association of Orthopaedics and Traumatology.

treated for a distal humeral extraarticular fracture with distal medial tibial plate between 2011 and 2016, were included in this retrospective analysis. The inclusion criteria were; history of no previous restriction of elbow and shoulder joint, patients with distal humeral extra articular fractures in whom conservative treatment failed, patients of age of 18 years or over. Pathological fractures and patients without a regular follow-up were excluded from the study.

Injury mechanisms, additional injuries, any radical symptoms, and whether postoperative revision was required were noted.

The fracture unions were evaluated with anteroposterior and lateral radiography preoperatively, postoperatively and at sixth week, third month and sixth month. The osseous consolidation of patients was assumed when callus formation or cortical continuity was observed radiologically.

Surgical method

Modified triceps sparing approach was used, the triceps muscle was retracted medially to expose the radial nerve, proximal to its piercing of the intermuscular septum. After exploration of the nerve a 3.5 mm distal medial tibial plate was used to fix the fracture. Following fracture reduction, distal tibia medial anatomic plate of 3.5 mm (Synthes®) were used with minimum 6 screws distal and proximal to fracture (Table 2). The malleolar tip extension end of the plate was cut off and if required thin distal portion of the plate was bended for fitting the plate to the posterior cortex of Humerus (Fig. 1). No cast or brace was used postoperatively.

Rehabilitation program

Shoulder and elbow range of motion (ROM) were initiated postoperatively at second day after pain control. The patients had 15–20 repeated active distal and proximal Range of Joint Motion (RJM) exercises twice a day, and passive elbow RJM exercises. The patients with nerve injury underwent appropriate radial splint and electrical stimulation. The strengthening exercises were started after nerve recovery. A vertical Visual Analogue Scale of 10 cm was used to assess the pain experienced by patients.¹⁰ A universal goniometer was used for Range of Joint Motion (RJM) assessment. Turkish version of DASH (DASH-T) was used for general assessment of upper extremity. Mayo elbow performance score was used for assessment of elbow joint. Grasp and pinch strength were compared with unaffected extremity.

Statistical analysis

Data was analyzed using the Statistical Packages for Social Sciences (SPSS, 16.0, version for Windows). Descriptive statistics (means, frequencies, standard deviation) were used to describe characteristics of humeral fractures.

Table 1
Demographic characteristics of patients.

Variables	Patients (n = 18)	
	Min–Max	X±SD
Age (year)	18–73	37.0 ± 17.3
Height (cm)	160–183	170.3 ± 6.8
Weight (kg)	53–97	77.5 ± 13.5
BMI (kg/m ²)	20.2–35.1	26.8 ± 5.4
Education (year)	0–16	8.8 ± 5.08
Follow-up period	12–57	36.2 ± 16.7
Time for union (month)	2–20	7.8 ± 5.9
Time to operation (day)	1–19	3.2 ± 4.5

Results

There were 18 patients included in the study, 11 men and 7 women with an average age of 37.0 ± 17.3 years (range: 18–73 years). The mean follow up time was 36.2 ± 16.7 (12–57) months. Other demographic characteristics of patients are provided in Table 1.

Of patients, seven had fractures due to low energy trauma and 11 had fractures due to high energy trauma. Only one patient had type 1 open fracture. 15 of patients were cases of acute fracture, and three were cases of revision. Of revised patients, one had intramedullary nail, and two had plate screws. Six of primary cases were operated for loss of closed reduction, five patients were operated for radial nerve injury after reduction or closed surgery. Two patients were operated for multi-trauma, and two patients were operated for segmented fractures. Two patients with AO A1 fractures were operated because of implant failure and two patients with radial nerve injury after reduction. Patients underwent surgery within an average of 3.2 days after the injury (range: 1–19 days). The fractures were classified according to AO-Müller classification. The mean distances of the fracture line to the epicondylar axis and olecranon fossa were measured as 51.43 ± 10.4 mm and 34.3 ± 8.72 mm respectively (Table 2).

Union was achieved in 17 of 18 patients. Only one patient had non-union due to infection and underwent debridement and the implant was (medial lateral plate) replaced. The mean time for union was 7.8 ± 5.9 months (2–20) (Table 1). The continuity of the nerve was impaired in only one of the five patients with radial nerve injury. It was repaired with sural nerve graft. The nerve functions improved in all of the patients (Fig. 2).

Patient perception of pain was X = 1.88 ± 2.50 and X = 4.55 ± 2.68, respectively, at rest and activity. The active ranges of joint motion were adequate for functional use. General functional state of affected extremity (DASH-T) was perfect (X = 27.14 ± 25.66), the performance of elbow joint was good (X = 84.44 ± 11.57) (Table 3).

There were no differences in comparison of grasp and pinch grip of patients with uninvolved extremity (Table 4).

Discussion

This study evaluated 18 patients with extra articular distal humeral diaphysal fractures clinically and radiologically, treated with tibia distal medial anatomic plate. This technique has been demonstrated to be an alternative fixation method to distal humerus extra articular fractures because it requires less soft tissue dissection, short operative time, and allows for stable fixation with good functional results.

According to the forces acting to the fracture line surgical treatment is recommended for distal humeral fractures to achieve stable fixation and to give early elbow motion which is important for good functional outcomes.^{11,12} Among the surgical treatment options, plate screw fixation is accepted as the gold standart.¹³

Due to anatomical structure specific to distal humerus, dual plate provides better biomechanical resistance compared to conventional shaft plates. The dual plate technique is disadvantageous as it requires exploration of both of the colons, and medial and lateral colon requires larger circumferential dissection of soft tissue.¹⁴ Dual plating is widely encountered with postoperative complications such as pain and irritation of the ulnar nerve.¹⁵ The incidence of ulnar neuritis has been reported up to 16% due to the exploration of the medial column and the adjacent placement of the implant near the cubital tunnel.^{16,17} Such dissection of tissue is unavoidable for intraarticular fractures, but seems to be unacceptable for extra articular shaft fractures. The studies have

Table 2
Descriptive data for fracture and plate lengths.

Patient no	Age	Gender	Fracture line distance to olecranon fossa (mm)	Fracture line distance to epikondiler axis (mm)	Distal screw	Proximal screw	Plate length (hole) ^a	Fracture pattern (AO)
1	35	F	45.9	70.0	6	5	12 + 8	C3
2	18	F	26.6	40.3	6	5	10 + 8	C3
3	28	M	35.0	48.3	6	3	8 + 8	C1
4	59	F	29.2	42.1	4	4	8 + 8	B1
5	18	M	30.0	47.0	5	5	6 + 8	B1
6	23	M	30.8	40.3	6	7	8 + 8	A1
7	20	F	22.9	37.4	5	4	6 + 8	B1
8	42	M	35.5	55.3	5	4	8 + 8	B1
9	51	M	53.0	71.0	8	5	12 + 8	B1
10	73	F	26.3	45.3	6	6	6 + 8	A3
11	27	M	37.2	55.0	6	5	10 + 8	C3
12	21	M	34.2	57.6	4	5	8 + 8	B2
13	47	M	44.2	56.4	5	4	8 + 8	B2
14	21	M	33.9	47.7	6	4	8 + 8	A1
15	53	M	23.5	38.8	8	5	12 + 8	A1
16	43	F	25.6	56.9	5	4	6 + 8	A1
17	63	F	35.1	49.9	3	5	10 + 8	C2
18	24	M	48.4	66.5	5	7	10 + 8	C3

^a 3.5 mm anatomic medial tibial plate has standart 8 distal locked screw holes.

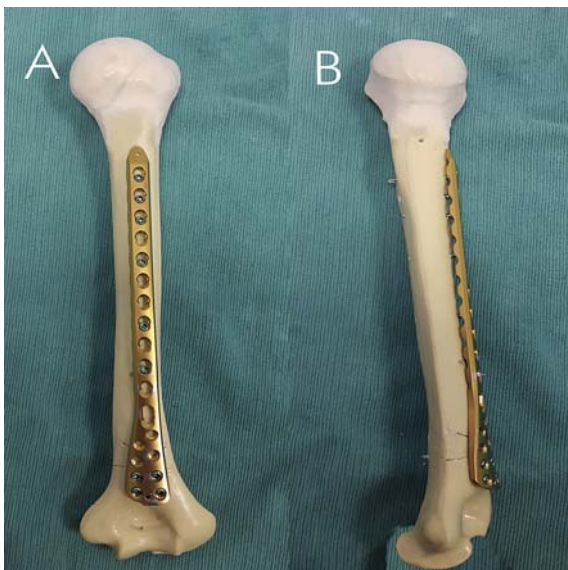


Fig. 1. Fixation with a LCP medial distal tibial plate located, posteriorly on distal humerus fracture model.

demonstrated significantly higher rates for nonunion and infection in dual plate technique besides good functions.^{18,19} The dissection of tissue, which has also adverse effects on the union of fractures, has recently been replaced by minimal dissection of tissue and stabile fixation methods.²⁰ Most authors recommended managing these fractures using a 4.5 mm low countered dynamic compression plate with 4.5 mm diameter screws and obtaining 6–8 cortices of purchase on either side of the fracture.²¹ However, it is difficult to fix distal fractures due to anteriorly curvature of the humerus with anterior approach and due to the presence of olecranon fossa with posterior approach. There is a restricted area for distal screw placement. In previous studies it has been reported that fixation of osteoporotic metaphysodiaphyseal junction fractures with standard 4.5 mm LCP plates may result in poor fixation and fixation loss in the distal metaphyseal fragment.^{18,19} The use of 3.5 mm screws instead of 4.5 mm screws in distal shaft fractures of the humerus, is advantageous in terms of the possibility of placing more screws in the distal segment of the fracture.¹⁴ Several authors have described

the single column fixation with 3.5 mm plates for non-segmental extra articular distal humerus fractures in order to minimize stripping of soft tissue and reduce the operative time and successful results have been obtained.^{11,17,22} Tejwani et al compared dual-plate technique with single column plating they found that the dual plating stiffer than the single precountered 3.5 mm locking plate in anterior, posterior and lateral bending, but found nonsignificant differences in axial compression and torsional testing between the two groups.¹¹ In a computer simulation study, compared the “Y” plate with both parallel and perpendicular plating techniques in the extra-articular distal humerus osteoporotic fractures, the authors found little difference between the three fixation methods and presented all as a viable option for the fixation of these fractures.²³ Similar to “Y” plate, the implant we used, allows fixation of both columns in extra-articular distal humerus fractures. Meloy et al compared the one column lateral plate with dual plate technique, and showed comparable rates for union, less complications, and improved range of motion in patients.¹⁵ In another study Synthes® anatomic precontoured 3.5 mm j plate used for fixation of humerus distal 1/3 extraarticular fractures, excellent results were obtained and they reported that there was no loss of fixation or olecranon impingement using this system.²⁴ The distal part of the distal medial tibia plate used in this study has a cobra shape and offers the possibility of placing 3.5 mm eight screws to the distal part of humerus. The distally extending portion of the implant is compatible with the posterior surface of the humerus, which allows for the placement of bicortical multiple screws in a limited area between the fracture line and the olecranon fossa.

The most important factor that enhances the stability of the implant against torsional forces is the bicortical application of screws as an advantage of our plate. Biomechanical studies of the humerus have shown that bicortical screw applications provide more stable fixation than unicortical screw applications.²⁵

The researchers are trying to find both a less soft tissue dissection and a more stable fixation method, so they have tried different types of implants in humeral fractures. Levy et al applied proximal lateral tibia plate and lateral column fixation by cutting the tip of the plate in distal humerus diaphysial fractures. The authors did not report implant failure in any of 15 patients, and achieved union in all the patients.²¹ The need for cutting the plate in this technique makes procedure difficult. We placed distal medial tibia plate distal to humerus through posterior approach, which has never been tried in the literature before. There are 8

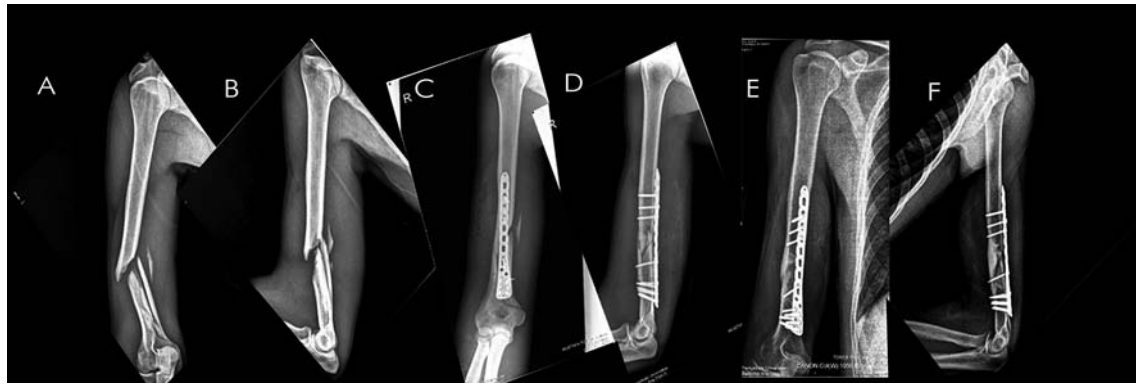


Fig. 2. 28 years old man operated for a right distal humeral fracture accordance with radial nerve injury. A, B: preoperative radiographies; C,D: postoperative radiographies; E,F: postoperative 12. month radiographies resulted with bone union.

Table 3

Pain, range of joint motion, general quality of life, and functional state of patients.

Variables	Patients (n = 18)	
	Min-Max	X \pm SD
Pain (VAS)		
Rest	0–7.60	1.9 \pm 2.5
Activity	0–9	4.5 \pm 2.7
Shoulder RJM ($^{\circ}$)		
Flexion	145–180	170.6 \pm 14.7
Extension	35–50	42.7 \pm 5.7
Abduction	100–180	159.1 \pm 31.8
Medial (outer) rotation	50–90	80.2 \pm 16.1
Lateral (inner) rotation	45–90	78.5 \pm 18.6
Elbow RJM ($^{\circ}$)		
Flexion	70–145	123.9 \pm 29.4
Extension	–20–0	–3.3 \pm 7.1
Forearm RJM ($^{\circ}$)		
Pronation	65–90	85.5 \pm 9.2
Supination	75–90	85.0 \pm 7.5
Wrist RJM ($^{\circ}$)		
Flexion	50–90	77.2 \pm 14.8
Extension	45–70	62.8 \pm 10.6
Radial deviation	10–25	21.1 \pm 5.5
Ulnar deviation	20–55	41.7 \pm 13.9
DASH-T	5–73	27.1 \pm 25.7
Mayo elbow performance scale	65–100	84.4 \pm 11.6

VAS: visual analog scale, RJM: range of joint motion.

Table 4

Findings for grasp and pinch grip force of patients.

Variables	Upper extremity of healthy side		Upper extremity of affected side		P ^a
	Min-Max	X \pm SD	Min-Max	X \pm SD	
Force for grasp (kg)	12–29	19.4 \pm 6.4	4–33	15.7 \pm 9.3	0.335
Force for pinch grip (kg)					
Pinch	0.3–7.0	3.1 \pm 2.7	0.0–4.3	1.4 \pm 1.6	0.130
II. finger pulp	2.2–12.0	5.6 \pm 2.9	1.0–9.3	3.7 \pm 2.4	0.144
II. finger lateral	2.2–16.7	8.2 \pm 5.2	2.0–12.0	4.6 \pm 3.3	0.102
III. finger lateral	1.1–13.0	5.2 \pm 3.7	0.5–7.7	3.1 \pm 2.9	0.178

^a Independent Samples Test.

holes on the head of distal medial tibia plate. Stable fixation can be achieved because multiple bicortical screws can be driven in the short distal fracture segment in distal fractures. The plate and the distal part of the humerus have similar anatomy except the concave curvature of distal part of the plate; therefore, it is not necessary to cut off except malleolar screw hole from the tip of medial tibia plate. When it is required to bend the plate to fit to

the cortex, the thinner distal portion can be easily bended. Concave contour to distal portion of the plate was reduced before placing the plate in some of our patients. Previous studies used medial tibia plate for fixation of lateral column, resulting in favorable clinical outcomes. Parmaksizoglu et al used distal tibia medial plate for fixation of anterolateral column in 23 patients, achieved stable fixation, and described it as an alternative method for distal humerus fractures.²²

In the present study, fixation was done through posterior approach; therefore, it appears to be advantageous as the radial nerve can be easily explored in cases requiring exploration of nerve. The large area on the head of the plate is applied on the expanding area of distal humerus, thus it provides resistance against rotational stress which is the main reason of failures, particularly for conventional plates. Only one of our patients had implant failure, who had been operated for osteomyelitis, in 18 patients that we operated. Union was also achieved in this patient with revision surgery. Fixation with this plate does not require opening distal muscle insertions or exploring ulnar nerve, thus complications are avoided, such as, wound site problems, irritation of ulnar nerve or paralysis. The dual plate minimizes the risk for loss of reduction, but may cause discomfort requiring removal of implant and complications of soft tissue due to wide exposure.¹⁴ No discomfort was observed that would require removal of plates in any of the patients and good functional outcomes were encountered as a result of treatment.

The limitations of this study include the small sample size and the retrospective study design. While it provides adequate fixation in fractures 2–3 cm proximal to the olecranon fossa, it is difficult to use for fixation of fractures just immediate to olecranon fossa. In the present study, the plate was placed with no protrusion of lower end of the plate on the olecranon fossa. None of the operated patients had impingement associated with plate, resulting in limitation of movement of elbow joint.

Conclusion

In distal humeral extra-articular fractures, usage of distal medial tibia plate has advantages such as providing high rates for union, low rates for complication, and early return to work with early rehabilitation, therefore it may be considered a fixation choice that can be used for distal humeral extra-articular fractures.

Declaration of conflict of interests

The authors declare that there are no conflicts of interest.

Acknowledgements

This research received no specific grant from any funding agency in the public, commercial, or not-for-profit sectors.

References

1. Tsai CH, Fong YC, Chen YH, Hsu CJ, Chang CH, Hsu HC. The epidemiology of traumatic humeral shaft fractures in Taiwan. *Int Orthop*. 2009;33(2):463–467. <https://doi.org/10.1007/s00264-008-0537-8>.
2. Elton SG, Rizzo M. Management of radial nerve injury associated with humeral shaft fractures: an evidence-based approach. *J Reconstr Microsurg*. 2008;24(8):569–573. <https://doi.org/10.1055/s-0028-1090623>.
3. Ouyang H, Xiong J, Xiang P, Cui Z, Chen L, Yu B. Plate versus intramedullary nail fixation in the treatment of humeral shaft fractures: an updated meta-analysis. *J Shoulder Elbow Surg*. 2013;22(3):387–395. <https://doi.org/10.1016/j.jse.2012.06.007>.
4. Bleeker WA, Nijsten MW, ten Duis HJ. Treatment of humeral shaft fractures related to associated injuries. A retrospective study of 237 patients. *Acta Orthop Scand*. 1991;62(2):148–153. <https://doi.org/10.3109/17453679108999244>.
5. Walker M, Palumbo B, Badman B, Brooks J, Van Gelderen J, Mighell M. Humeral shaft fractures: a review. *J Shoulder Elbow Surg*. 2011;20(5):833–844. <https://doi.org/10.1016/j.jse.2010.11.030>.
6. Prasarn ML, Ahn J, Paul O, et al. Dual plating for fractures of the distal third of the humeral shaft. *J Orthop Trauma*. 2011;25(1):57–63. <https://doi.org/10.1097/BOT.0b013e3181df96a7>.
7. Holdsworth BJ, Mossad MM. Fractures of the adult distal humerus. Elbow function after internal fixation. *J Bone Joint Surg Br*. 1990;72(3):362–365. <https://doi.org/10.1302/0301-620X.72B3.2341427>.
8. Huang TL, Chiu FY, Chuang TY, Chen TH. Surgical treatment of acute displaced fractures of adult distal humerus with reconstruction plate. *Injury*. 2004;35(11):1143–1148. <https://doi.org/10.1016/j.injury.2003.11.018>.
9. Jupiter JB, Neff U, Holzach P, Allgöwer M. Intercondylar fractures of the humerus. An operative approach. *J Bone Joint Surg Am*. 1985;67(2):226–239.
10. Price DD, McGrath PA, Raffi A, Buckingham B. The validation of visual analogue scales as ratio scale measures for chronic and experimental pain. *Pain*. 1983;17(1):45–56. [https://doi.org/10.1016/0304-3959\(83\)90126-4](https://doi.org/10.1016/0304-3959(83)90126-4).
11. Tejwani NC, Murthy A, Park J, McLaurin TM, Egol KA, Kummer FJ. Fixation of extra-articular distal humerus fractures using one locking plate versus two reconstruction plates: a laboratory study. *J Trauma*. 2009;66(3):795–799. <https://doi.org/10.1097/TA.0b013e318181e53c>.
12. Ilyas AM, Jupiter JB. Treatment of distal humerus fractures. *Acta Chir Orthop Traumatol Cech*. 2008;75(1):6–15.
13. Jeong BO, Lee DK. Treatment for type C fractures of the distal humerus with the LCP distal humerus system. *Eur J Orthop Surg Traumatol*. 2012;22(7):565–569. <https://doi.org/10.1007/s00590-011-0893-8>.
14. Kharbanda Y, Tanwar YS, Srivastava V, Birla V, Rajput A, Pandit R. Retrospective analysis of extra-articular distal humerus shaft fractures treated with the use of pre-contoured lateral column metaphyseal LCP by triceps-sparing posterolateral approach. *Strateg Trauma Limb Reconstr*. 2017;12(1):1–9. <https://doi.org/10.1007/s11751-016-0270-6>.
15. Meloy GM, Mormino MA, Siska PA, Tarkin IS. A paradigm shift in the surgical reconstruction of extra-articular distal humeral fractures: single-column plating. *Injury*. 2013;44(11):1620–1624. <https://doi.org/10.1016/j.injury.2013.07.005>.
16. Chen RC, Harris DJ, Leduc S, Borrelli JJ, Tornetta P, Ricci WM. Is ulnar nerve transposition beneficial during open reduction internal fixation of distal humerus fractures? *J Orthop Trauma*. 2010;24(7):391–394. <https://doi.org/10.1097/BOT.0b013e3181c99246>.
17. Vazquez O, Rutgers M, Ring DC, Walsh M, Egol KA. Fate of the ulnar nerve after operative fixation of distal humerus fractures. *J Orthop Trauma*. 2010;24(7):395–399. <https://doi.org/10.1097/BOT.0b013e3181e3e273>.
18. Jawa A, McCarty P, Doornberg J, Harris M, Ring D. Extra-articular distal-third diaphyseal fractures of the humerus. A comparison of functional bracing and plate fixation. *J Bone Jt Surg Am*. 2006;88(11):2343–2347. <https://doi.org/10.2106/JBJS.F.00334>.
19. Bell MJ, Beauchamp CG, Kellam JK, et al. The results of plating humeral shaft fractures in patients with multiple injuries. The Sunnybrook experience. *J Bone Joint Surg Br*. 1985;67(2):293–296. <https://doi.org/10.1302/0301-620X.67B2.3980544>.
20. Yang Q, Wang F, Wang Q, et al. Surgical treatment of adult extra-articular distal humeral diaphyseal fractures using an oblique metaphyseal locking compression plate via a posterior approach. *Med Princ Pract*. 2012;21(1):40–45. <https://doi.org/10.1159/000331791>.
21. Levy JC, Kalandiak SP, Hutson JJ, Zych G. An alternative method of osteosynthesis for distal humeral shaft fractures. *J Orthop Trauma*. 2005;19(1):43–47. <https://doi.org/10.1097/00005131-200501000-00008>.
22. parmaksızoğlu AS, Özkaya U, Bilgili F, Mutlu H, Çetin Ü. Fixation of extra-articular distal humeral fractures with a lateral approach and a locked plate: an alternative method. *Acta Orthop Traumatol Turc*. 2016;50(2):132–138. <https://doi.org/10.3944/AOTT.2015.14.0445>.
23. Sabalic S, Kodvanj J, Pavic A. Comparative study of three models of extra-articular distal humerus fracture osteosynthesis using the finite element method on an osteoporotic computational model. *Injury*. 2013;44(suppl 3). [https://doi.org/10.1016/S0020-1383\(13\)70200-6](https://doi.org/10.1016/S0020-1383(13)70200-6).
24. Fawi H, Lewis J, Rao P, Parfitt D, Mohanty K, Ghandour A. Distal third humeri fractures treated using the Synthes™ 3.5-mm extra-articular distal humeral locking compression plate: clinical, radiographic and patient outcome scores. *Shoulder Elb*. 2015;7(2):104–109. <https://doi.org/10.1177/1758573214559320>.
25. Dunlap JT, Lucas GL, Chong AC, Cooke FW, Tiruvadi V. Biomechanical evaluation of locking plate fixation with hybrid screw constructs in analogue humeri. *Am J Orthop (Belle Mead NJ)*. 2011;40(2):E20–E25.