

## ARTICLE

## Atypical Epithelial Changes and Mutant p53 Gene Expression in Ovarian Endometriosis

Hatice BAYRAMOĞLU, Ender DÜZCAN

Pamukkale University Faculty of Medicine, Department of Pathology, Denizli, Turkey

It has been reported that cases of ovarian endometriosis those with epithelial cytological atypia have potential for malignant transformation. This study was planned to determine the incidence of atypical endometriosis and its cytological criteria, to evaluate the malignant potential of atypical endometriosis via immunohistochemical methods (p53). In this study we evaluated 140 samples obtained from 120 cases of ovarian endometriosis and 10 ovarian endometrioid carcinomas that have been previously diagnosed histopathologically. We re-evaluated endometriosis cases with respect to their epithelial and stromal features, existence of acute or chronic inflammatory cells in endometriotic epithelium or stroma and other accompanying histological findings. We observed atypia in 7 (5.8%) cases; reactive atypia in 37 (30.8%) cases, no atypia in 76 (63.4%) cases. We evaluated immunohistochemical p53 expression in 7

**Keywords:** ovarian endometriosis, atypia, p53

atypical cases, 37 reactive atypical cases, and in 10 of those without atypia and in 10 endometrioid carcinoma cases. We noted no staining in cases with atypia, reactive atypia and without atypia while 3 cases of endometrioid carcinoma had positive staining for p53. We concluded that prominent nucleolus and angulation of nuclear contour could be added to criteria of atypia that were mentioned before in the literature. In our study, even though p53 expression could not be shown with immunohistochemical methods in atypical endometriotic cases; it can not be determined that atypical endometriosis lesions are not premalignant. Still, endometriosis cases should be evaluated carefully by the pathologist for foci of cytological atypia and it should be kept in mind that malignant transformation might occur in these atypical endometriosis cases. (Pathology Oncology Research Vol 7, No 1, 33-38, 2001)

### Introduction

Endometriosis is defined as the presence of endometrial tissue outside the endometrium and myometrium. The most common site of this lesion is ovary.<sup>1-4</sup> It is usually accepted as a benign process, but rarely malignant transformation is recognized in ovarian and extraovarian endometriosis.<sup>4-11</sup> Sampson, in 1925, first reported the coexistence of malignant tumors with simple endometriosis. Sampson and Scott criteria are required for establishing malignant transformation.<sup>4-7</sup> Other authors have recommended close scrutiny of cellular atypia and/or hyperplasia in ectopic endometrial tissue to define lesions that may be preneoplastic.<sup>4-7,12</sup> Severe epithelial atypia, which was first recognized by

Czernobilsky and Morris in 1979, was seen in 7 (3.6%) patients with ovarian endometriosis.<sup>12</sup>

There were a few documents in the literature which describe atypical endometriosis as a preneoplastic lesion.<sup>13,14</sup> If atypical endometriosis is pre-neoplastic, neoplastic transformation in atypical endometriosis may be demonstrated by mutant p53 tumor suppressor gene overexpression, because of positive p53 immunoreactivity in some other preneoplastic lesions.<sup>15-22</sup> In this study, the frequency of atypical endometriosis was established and criteria of cytologic atypia were looked over again. p53 overexpression was investigated immunohistochemically in cases with atypical endometriosis.

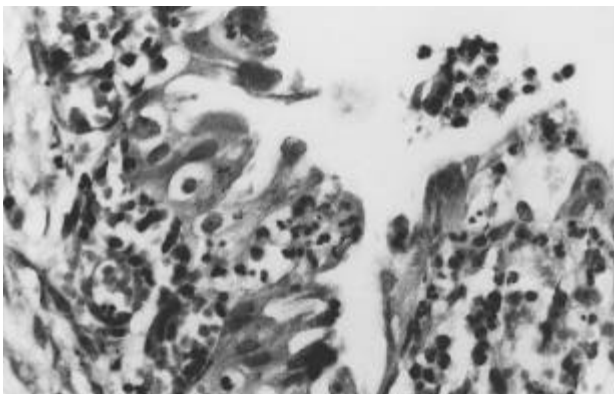
### Materials and Methods

In this retrospective study, 137 ovarian endometriosis and 10 ovarian endometrioid carcinomas which were diagnosed histopathologically were included. The tissues were fixed in buffered formalin and embedded in paraffin. The

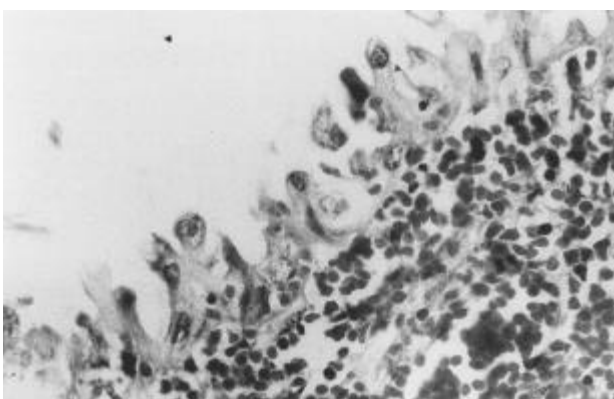
*Received:* Sep 11, 2000; *revised:* Dec 10, 2000; *accepted:* Jan 21, 2001

*Correspondence:* Associated Dr. Hatice BAYRAMOĞLU, Atakent Mh. Esnaf Sitesi, Sardunya Sk. No:17 Denizli, Turkey; Tel: 00902582420344, Fax: 00902582410040, e-mail: hbayramoglu@hotmail.com

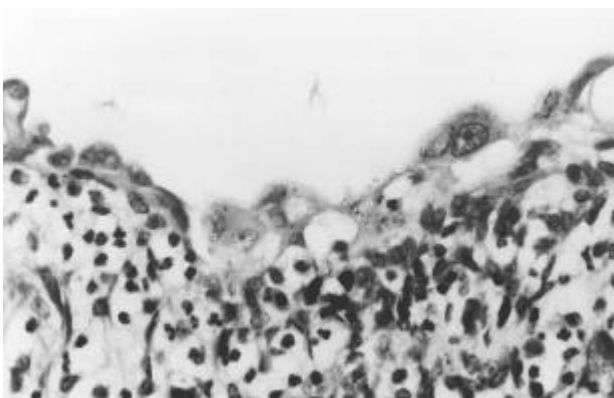
4-5 µm thick sections were routinely stained with hematoxylin and eosin (HE). The slides of all cases were reexamined. Seventeen materials without endometrial epithelium were excluded from the study and 120 cases with 140 materials (20 cases bilaterally) were studied.



**Figure 1.** Stromal and epithelial PMNL infiltration, cytoplasmic bridging and micropapillary projection (reactive atypia) (HE x400).



**Figure 2.** Hobnail cells, vesiculated nuclei with prominent nucleoli, nuclear angulation, pleomorphism and stromal PMNL infiltration (reactive atypia) (HE x400).



**Figure 3.** Nuclear pleomorphism, vesiculated nuclei with prominent nucleoli (atypia) (HE x400).

The diagnosis of atypical endometriosis was based on the histopathological criteria designated by Czernobilsky and Morris, and LeGrenade and Silverberg.<sup>5-10</sup> These features included eosinophilic cytoplasm; large hyperchromatic or pale nuclei with moderate to marked pleomorphism; increased nuclear to cytoplasmic ratio; cellular crowding and stratification or tufting. The cases which contain 3 or more of these criteria were classified as atypical endometriosis (group-I). The cases with inflammatory cells in endometriotic epithelium showing atypia were classified as reactive atypia (group-II). Finally, group III contained cases without epithelial atypia.

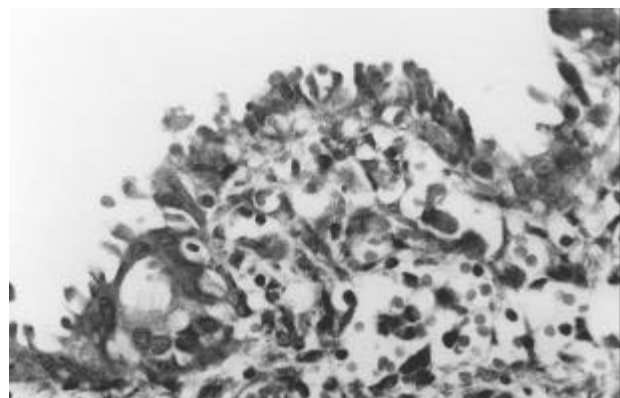
Epithelial features (stratification and crowding, micropapillary projections, tufting, metaplasia, secretory vacuolate cytoplasm, eosinophilic cytoplasm, increased nucleus/cytoplasm ratio, prominent hyperchromatic nuclei, cytoplasmic bridging effect, vesiculated nuclei, pleomorphism and nuclear angulation), stromal features (congestion, increased fibrous tissue and pigmented histiocytes) and presence of acute and chronic inflammatory cells and other histological features were re-evaluated.

Differences between ages of cases were analyzed statistically by the Kruskal-Wallis variance test. Epithelial, stromal features and localizations of diseases were analyzed statistically by 2 test.

After re-evaluation, all of the materials with atypical endometriosis and reactive atypia, 10 materials with endometriosis without atypia and 10 materials with endometrioid carcinoma were stained immunohistochemically by monoclonal anti-p53 (D7, Dako) tumor suppressor gene using streptavidin biotin peroxidase technique.

### Results

There was no atypia in 76 cases (63.4%), but reactive atypia (*Figures 1,2*) in 37 (30.8%) and atypical endometriosis (*Figures 3,4*) in 7 cases (5.8%). Two cases with reactive atypical endometriosis were bilateral. Aver-



**Figure 4.** Cytoplasmic bridging and pleomorphism (atypia) (H&E x 400).

age was 36.4 in all patients, 34.1 in patients with atypical endometriosis, 37.4 in cases with reactive atypia, 36.1 in cases with nonatypical endometriosis. There was no significant difference between all age groups. ( $p>0.05$ ). The lesions were bilateral in 20 (17%) patients, localized in the left ovary in 42 (35%) and present in the right ovary in 57 (48%) patients. There was no significant difference between the groups ( $p>0.05$ ).

All of the cases were partial or complete cystic and ranged from 0.5 to 6.5 cm in diameter. The ratio of epithelial characteristics such as stratification and crowding, micropapillary projections, tufting, prominent hyperchromatic nucleoli, vesiculated nuclei, pleomorphism and nuclear angulation, large hyperchromatic or pale nuclei with moderate to marked pleomorphism was higher in group I than the groups II and III ( $p<0.0001$ ), but there was no significant difference between group I and II ( $p>0.05$ ).

There was not significant difference between groups I and II ( $p>0.05$ ) for to hobnail cell metaplasia and eosinophilic cytoplasm, but there was statistically difference between the group I or II and III ( $p<0.05$ ). There were no significant differences between all groups for secretory vacuolate cytoplasm and ciliated cell metaplasia ( $p>0.05$ ). The incidence of epithelial and stromal changes in each group is indicated in *Table 1*.

We were able to demonstrate that the mixed inflammatory infiltration with polymorphonuclear leucocytes (PMNL) in endometriotic epithelium in 25% ( $n=35$ ) and in stroma in 29.2% of the samples ( $n=35$ ). Epithelial PMNL infiltration was detected in 27 (69.2%) samples with reactive atypia and in 8 (8.5%) samples without atypia. Stromal PMNL infiltration was found in 30 (76.9%) samples with reactive atypia and in 11 (8.5%) samples without atypia. These characteristics were statistically different between group II and the other groups especially group III ( $p<0.0001$ ). When they were examined according to

mononuclear cell infiltration (MNC), it was detected in epithelium in 10 (7.1%) samples and in stroma in 27 (19.2%) samples. Epithelial MNC infiltration was detected in 4 (10.2%) samples with reactive cytologic atypia and in 6 (6.3%) samples without atypia. Stromal MNC infiltration was detected in 8 (20.5%) samples with reactive cytologic atypia and in 17 (18%) samples without atypia. Only mild MNC stromal infiltration was seen in two (28.6%) samples with cytologic atypia. There was no difference between groups according to stromal MNC infiltration ( $p>0.05$ ).

For subepithelial congestion between groups with cytologic atypia and reactive cytologic atypia, there was no significant difference ( $p>0.05$ ), but there was difference between groups with reactive atypia and without atypia ( $p<0.001$ ). For fibrous proliferation there was no significant difference between groups ( $p>0.05$ ).

Ten cases with endometrioid carcinoma were examined by immunohistochemical methods. Mouse anti-human p53 protein, DO-7 was used and 3 samples showed positive nuclear staining. In 2 samples, staining was diffuse and strong, while it but, was focal and severe in 1 materi-

**Table 1. Epithelial and stromal features**

Feature	Group I (atypia)		Group II (reactive atypia)		Group III (without atypia)	
	n	%	n	%	n	%
<b>I-EPITHELIUM</b>						
Stratification and crowding	6	85.7	13	33.3	0	0.0
Micropapillary projection	2	28.6	8	20.5	4	4.2
Tufting	4	57.1	4	10.2	2	2.1
Hobnail cell metaplasia	2	28.6	8	20.5	3	3.1
Ciliated cell metaplasia	0	0.0	2	28.6	8	8.5
Bridging effect	2	28.6	8	20.5	4	4.2
Vacuolate cytoplasm	0	0.0	4	10.3	3	3.1
Eosinophilic cytoplasm	4	57.1	20	51.2	14	14.8
Large nuclei	7	100	22	56.4	3	3.1
Prominent nucleoli	4	57.1	13	33.3	2	2.1
Nuclear angulation	4	57.1	15	38.4	2	2.1
Hyperchromasia	3	42.8	10	25.6	4	4.2
Vesiculated nuclei	5	71.4	11	28.2	1	1.1
Pleomorphism	4	57.1	10	25.6	3	3.2
<b>II-STROMA</b>						
MNH infiltration	2	28.6	8	20.5	17	18.0
PMNL infiltration	0	0.0	30	76.9	11	11.7
Congestion	1	14.2	16	41.0	15	15.9
Fibrous proliferation	1	14.2	12	30.7	17	18.0

al. Positive nuclear staining was not seen in samples with atypia and without atypia. But in one material with reactive atypia there was cytoplasmic staining along the luminal face of cyst epithelium.

### Discussion

Endometriosis is accepted as a benign lesion. Malignant transformation is a rare, but recognized complication of gonadal and extragonadal endometriosis. The co-existence of malignant tumors with endometriosis is noted, 75% of cases with this association occur in the ovary and 25% at extraovarian sites.<sup>4,9</sup> Some authors have recommended close scrutiny of cellular atypia and/or hyperplasia in ectopic endometrial tissue to define lesions that may be pre-neoplastic.<sup>7,12</sup> Cellular atypia in endometriosis was defined by Czernobilsky and Morris in 1979. Authors reported that the lesions, showing eosinophilic cytoplasm, tufting, large hyperchromatic or pale nuclei, cellular crowding and stratification in epithelial cells were severe epithelial atypia, whereas mild eosinophilic cytoplasm, severe stromal inflammation and epithelial regeneration in epithelial cells were the indicators of mild atypia.<sup>12</sup> LaGrande and Silverberg synonymously used the term inflammatory (reactive) atypia for cases of mild atypia. They also reported 5 malignant tumors which arose in atypical endometriosis.<sup>5</sup> In 1997, Fukunaga et al. found that there were more than three features which were reported for atypical endometriosis.<sup>23</sup>

The incidence of atypical endometriosis was found to be 3.6% by Czernobilsky and Morris, 1.7% Fukunaga et al., 10.9% Erhan et al. and 32.3% by Seidmann.<sup>12,23,24,25</sup> In our study, incidence of atypical endometriosis was 5.8%. Incidence of reactive atypia, which was defined as mild cytologic atypia, was found as 22.1% by Czernobilsky and Morris.<sup>12</sup> In our study, it was found to be 30.8%.

Hobnail and ciliated cell metaplasia can be seen within endometriotic foci.<sup>1,3</sup> Since hobnail cells can be detected in Arias-Stella reaction, normal endometrium, other Mullerian organs and some benign lesions, it is not a strict criteria of cytologic atypia.<sup>12</sup> Hobnail cell metaplasia can also be seen in clear cell carcinoma.<sup>4</sup> Karseladze reported that tubal and endocervical type epithelial changes have been seen in ovarian endometriotic foci, so serous or mucinous cancer could develop from these foci. Although severe dysplasia, including focal carcinoma have been demonstrated, there was no invasion.<sup>26</sup> In our study, hobnail cells were seen in 13 (9.2%) materials. Statistical examination revealed no significant difference between group I and II ( $p>0.05$ ), but the difference between these two groups and group III was significant ( $p<0.05$ ). Ciliated cell metaplasia was seen in 12 samples, but there was no significant difference between all groups ( $p>0.05$ ). According to these findings, ciliated cell metaplasia can be seen in endomet-

riosis, supporting the pathogenetic theory of endometriosis which suggests metaplasia from celomic epithelium. Although hobnail cell metaplasia is not a criterion for the diagnosis, it must be regarded as an atypical changes.

Although it has been supposed that endometriotic papillary projections are a sign of borderline endometrioid carcinoma in ovary, they can be seen in the different organs from Mullerian origin, so they have not-been criteria of atypia.<sup>12</sup> Our results also support the impression used as that papillary projections are not criteria of atypia ( $p>0.05$ ). We found similar results for cytoplasmic bridging. These findings show that papillary projections and cytoplasmic bridging could be seen as a sign or activity of regeneration in the endometriotic epithelium.

In our study, we found that the incidence of prominent nucleoli and nuclear angulation were statistically higher in groups I and II than group III ( $p<0.0001$ ). So we can say that prominent nucleoli and nuclear angulation can be added to criteria of atypia. A number of documented cases in which atypical endometriosis was the transitional link between simple endometriosis and co-existing frank neoplasm are reported in the literature.<sup>5,7,23</sup> The most common site is ovary.<sup>4</sup> Fukunaga et al. documented the largest transformation groups from atypical endometriosis and invasive cancer. All of the cases had Scott's criteria. In this study, 224 ovarian endometriosis have been examined and only 13 cases showed this transformation.<sup>23</sup>

The spatial and chronological associations strongly suggest that foci of atypical epithelial changes encountered in endometriosis have the biologic importance of a precancerous lesion, similar to atypical hyperplasia of the endometrium as it relates to uterine adenocarcinoma. Therefore as a matter of caution, some authors have believe that foci of atypical epithelium deserve a heightened awareness by the pathologist and should be emphasized in the pathologic report and also that radical surgery should be performed.<sup>4</sup>

In the literature, there are some studies about transformation of atypical endometriosis to malignancy, but there are a few studies of the malignant potential of atypical endometriosis.<sup>13,14</sup> Chalas et al. reported that AgNOR counts were higher in the patients with atypical endometriosis than control group. In that study, three of four patients with high AgNOR values had malignant transformation and it was suggested that AgNOR values must be examined for malignancy.<sup>13</sup> Ballouk et al. reviewed that there was 50% aneuploidy in the group, which had severe atypia in the epithelium of endometriotic cysts, but there was normal DNA ploidy in the group which had mild cytologic atypia. Aneuploidy in atypical endometriosis supports potential for malignant transformation. Regarding to it is supposed that ovarian endometriotic cysts which have cytologic atypia are precursors of invasive epithelial ovarian tumors.<sup>14</sup>

p53 immunoreactivity is observed in some pre-neoplastic lesions such as dysplasia of bronchus epithelium, oral cavity, larynx, esophagus, stomach, gallbladder, colorectal adenomas and cervical intraepithelial dysplasia.<sup>20-22</sup> It can be supposed that if atypical endometriosis is a premalignant lesion, there might be p53 tumor suppressor gene overexpression.

It is well also known that p53 tumor suppressor gene mutation can be found in most of human carcinomas. However, this mutation rate differs between human carcinomas (29-80%).<sup>15-19</sup> In ovarian cancers this mutation rate was found to be 50% in Mark's study, 53% in Harlozinska's study.<sup>27,28</sup>

In the literature there are different results for different types of ovarian cancers. Koshiyama et al documented p53 tumor suppressor gene overexpression as 70% in serous carcinoma, 66.7% in mucinous carcinoma and in 40% endometrioid carcinoma.<sup>29</sup> Niwa et al found that the p53 mutation rate was 42% in serous cyst adenocarcinoma and endometrioid carcinoma.<sup>30</sup> Kappes et al found that somatic p53 mutation was most common in serous papillary carcinoma (57.1%). They used immunohistochemical methods, direct sequence, polymerase chain reaction (PCR) and temperature-gradient gel electrophoresis (TGGE). This rate was 12.5%–22.2% in endometrioid and mucinous carcinoma, respectively.<sup>3</sup> In our study 2 of 10 different graded endometrioid carcinomas showed diffuse-strong and one of them showed focal-strong p53 tumor suppressor gene expression.

There have been several reports in the literature describing benign gynecologic tissues, endometriosis and benign tumors that do not excess p53 overexpression.<sup>27,28,32,33,34</sup> Also, in our study in none of the cases without cytologic atypia, showed p53 expression. Kappes et al have suggested that p53 mutation in ovarian tumors is rare in borderline and benign tumors by technics of PCR, TGGE and immunohistochemistry.<sup>31</sup> Kupryjanczyk et al showed that p53 expression in stage-I carcinoma and borderline ovarian tumors could be a precursor of early ovarian cancer.<sup>35</sup> But in our study p53 expression could not be found in 7 samples with atypia and 39 samples with reactive atypia.

In our study, we used an anti-p53 (DO-7) antibody which stains either wild type or mutant p53.<sup>15,36</sup> Only nuclear staining is regarded as positive.<sup>20,37,38</sup> But in some studies cytoplasmic staining with nuclear staining has been estimated as overexpression.<sup>37</sup> Cytoplasmic p53 overexpression is not understood. Catoretti et al suggested that anti-p53 antibodies had cross-reaction with cytokeratin.<sup>36</sup> It is also suggested that p53 could become complex with Hsp 70 in cytoplasm and this complex creates either nuclear or cytoplasmic staining.<sup>37,39,40</sup> In our study, we observed cytoplasmic staining on luminal surface of the cyst epithelium but nuclear staining was not prominent. This staining was not evaluated as positive. False negative reactions generally occur as a result of technical problems.<sup>41</sup> The other reason

could be a large deletion in two alleles or nonsense mutation.<sup>42</sup> In our study, p53 overexpression was not found in cases with atypical endometriosis.

In our study 140 materials from 120 ovarian endometriosis cases were studied retrospectively. Cytologic atypia was detected in 5.8% of these materials. We suggest that prominent hyperchromatic nucleoli and nuclear angulation could be added to criteria of atypia. In none of cases with atypical endometriosis p53 gene overexpression could be detected by immunohistochemical methods. But we suggest that this alone is not enough to say that atypical endometriosis would not be a premalignant lesion for ovarian cancers. Consequently, atypical epithelial changes have to be carefully detected by the pathologist and should be indicated in the final report.

## References

- <sup>1</sup> *Clement PB*: Diseases of the Peritoneum, In Kurman RJ ed. Blaustein's Pathology of the Female Genital Tract. New York: Springer-Verlag, 1994, pp660-680.
- <sup>2</sup> *Gerbie AB, Merrill JA*: Pathology of endometriosis. Clin Obstet Gynecol 31:779-786, 1988.
- <sup>3</sup> *Clement PB, Young RH, Scully RE*: Peritoneum. In Sternberg SS ed. Diagnostic Surgical Pathology. New York, Raven Press Ltd., 1994, pp 2311-2315.
- <sup>4</sup> *Moll UM, Chumas JC, Chalas E, Mann WJ*: Ovarian carcinoma arising in atypical endometriosis. Obstet Gynecol 75:537-539, 1990.
- <sup>5</sup> *LaGrenade A, Silverberg SG*: Ovarian tumors associated with atypical endometriosis. Human Pathol 19:1080-1084, 1988.
- <sup>6</sup> *Heaps JM, Nieberg RK, Berek JS*: Malignant neoplasms arising in endometriosis. Obstet Gynecol 75:1023-1028, 1990.
- <sup>7</sup> *De La Cuesta RS, Eichhorn JH, Rice LW et al*: Histologic transformation of benign endometriosis to early epithelial ovarian cancer. Gynecol Oncol 60:238-244, 1996.
- <sup>8</sup> *Granai CO, Walters MD, Safai H, et al*: Malignant transformation of vaginal endometriosis. Obstet Gynecol 64:592-595, 1984.
- <sup>9</sup> *Brooks JJ, Wheeler JE*: Malignancy arising in extragonadal endometriosis. Cancer 10:3065-3073, 1977.
- <sup>10</sup> *Horiuch A, Osada R, Nakayama K, et al*: Ovarian yolk sac tumor with endometrioid carcinoma arising from endometriosis in a postmenopausal woman, with special reference to expression of alpha-fetoprotein, sex steroid receptors, and p53. Gynecol Oncol 70:295-299, 1998.
- <sup>11</sup> *Han AC, Hovenden S, Rosenblum NG, Salazar H*: Adenocarcinoma arising in extragonadal endometriosis: an immunohistochemical study. Cancer 83:1163-1169, 1998.
- <sup>12</sup> *Czernobilsky B, Morns WJ*: A histologic study of ovarian endometriosis with emphasis on hyperplastic and atypical changes. Obstet Gynecol 53:318-323, 1979.
- <sup>13</sup> *Chalas E, Chumas J, Barbien R, Mann WJ*: Nucleolar organizer regions in endometriosis, atypical endometriosis, and clear cell and endometrioid carcinoma. Gynecol Oncol 140:260-263, 1991.
- <sup>14</sup> *Ballouk F, Ross JS, Wolf BC*: Ovarian Endometriotic cysts (An analysis of cytologic atypia and DNA ploidy patterns. Am J Clin Pathol 102:415-419, 1994
- <sup>15</sup> *Nigro JM, Baker SJ, Preisinger AC, et al*: Mutations in the p53 gene occur in diverse human tumour types. Nature 342:705-708, 1989.

16. *Kawai A, Noguchi M, Beppu Y, et al:* Nuclear immunoreaction of p53 protein in soft tissue sarcomas. *Cancer* 73:2499-2505, 1994.
17. *Deb S, Jackson CT, Subler MA, Martin DW:* Modulation of cellular and viral promoters by mutant human p53 proteins found in tumor cells. *J Virol* 66:6164-6170, 1992.
18. *Harris AL:* p53 expression in human breast cancer. *Advances Cancer Res* 59:69-88, 1992.
19. *Rotter V, Prokocimer M:* p53 and human malignancies. *Advances Cancer Res* 57: 257-272, 1991.
20. *Walker C, Robertson LJ, Myskow MW, et al:* p53 expression in normal and dysplastic bronchial epithelium and in lung carcinomas. *Br J Cancer* 70:297-303, 1994.
21. *Fontanini G, Vignati S, Bigini D, et al:* Human non-small cell lung cancer: p53 protein accumulation is an early event and persists during metastatic progression. *J Pathol* 174:23-31, 1994.
22. *Bennett Wp, Hollstein MC, Metcalf RA, et al:* p53 mutation and protein accumulation during multistage human esophageal carcinogenesis. *Cancer Res* 52:6092-6097, 1992.
23. *Fukunaga M, Nomura K, Ishikawa E, et al:* Ovarian atypical endometriosis: its close association with malignant epithelial tumours. *Histopathology* 30:249-255, 1997.
24. *Seidmann JD:* Prognostic importance of hyperplasia and atypia in endometriosis. *Int J Gynecol Pathol* 15:1-9, 1996.
25. *Erhan Y, Postaci H:* Over endometriozlarında histolojik özellikler, İzmir Devlet Hastanesi Mecmuası. 21:254-261, 1983.
26. *Karseladze AI:* Ovarian endometriosis. *Arch Pathol* 52:24-29, 1990.
27. *Marks JR, Davidoff AM, Kerns BJ, et al.* Overexpression and mutation of p53 in epithelial ovarian cancer. *Cancer Res* 51:2979-2984, 1991.
28. *Harlozinska A, Bar JK, Sedlaczek P, Gerber J:* Expression of p53 protein and Ki-67 reactivity in ovarian neoplasms. *Am J Clin Pathol* 105:3340-3345, 1996.
29. *Koshiyama M, Konishi I, Mandai M, et al:* Immunohistochemical analysis of p53 protein and 72 kDa heat shock protein (HSP72) expression in ovarian carcinomas. Correlation with clinicopathology and sex steroid receptor status. *Virchows Arch* 425:603-609, 1995.
30. *Niwa K, Itoh M, Murase T, et al:* Alteration of p53 gene in ovarian carcinoma: clinicopathological correlation and prognostic significance. *Br J Cancer* 70:1191-7, 1994.
31. *Kappes S, Milde-Langosch K, Kressin P, et al:* p53 mutations in ovarian tumors, detected by temperature-gradient gel electrophoresis, direct sequencing and immunohistochemistry. *Int J Cancer* 64:52-59, 1995.
32. *Kargı HA, Sagol Ö, Özuysal S:* The immunohistochemical expression of proliferating cell nuclear antigen c-erbB2 and p53 in benign, borderline and malignant epithelial ovarian neoplasms. *Turkish J Cancer* 27:13-18, 1997.
33. *Eccles DM, Brett L, Lessek A, et al:* Overexpression of the p53 protein and allele loss at 17p13 in ovarian carcinoma. *Br J Cancer* 65:40-44, 1992.
34. *Schneider J, Jimenez E, Rodriguez F, et al:* C-myc, c-erb-B2, nm23 and p53 expression in human endometriosis. *Oncol Rep* 5:49-52, 1998.
35. *Kupryjanczyk J, Bell DA, Yandell DW et al:* p53 expression in ovarian borderline tumor and stage I carcinomas. *Am J Clin Pathol* 102:671-676, 1994.
36. *Cattoretti G, Rilke F, Andreola S, et al:* p53 expression in breast cancer. *Int J Cancer* 41:178-183, 1988.
37. *Haerslev T, Jacobsen GK:* An immunohistochemical study of p53 with correlations to histopathological parameters, c-erb-2, proliferating cell nuclear antigen, and prognosis. *Hum Pathol* 26:295-301, 1995.
38. *Akasofu M, Oda Y:* Immunohistochemical detection of in cervical epithelial lesions with or without infection of human papillomavirus types 16-18. *Virchows-Arch* 425:593-602, 1995.
39. *Martnez J, Georgoff I, Martnez J, et al:* Cellular localization and cell cycle regulation by a temperature-sensitive p53 protein. *Genes Development* 5:151-159, 1991.
40. *Iggo R, Gatter K, Bartek J, et al:* Increased expression of mutant forms of p53 oncogene in primary lung cancer. *Lancet* 335:675-679, 1990.
41. *Wynford-Thomas D:* p53 in tumour pathology: Can we trust immunocytochemistry? *J Pathol* 166:329-330, 1992.
42. *Zhao M, Zhang NX, Laissue SA, Zimmermann A:* Immunohistochemical analysis of p53 protein over expression in liver cell dysplasia and in hepatocellular carcinoma. *Virchows Archiv* 424:613-621, 1994.