

Measurements of scleral thickness and corneal optic densitometry in patients with systemic lupus erythematosus

Hüseyin Kaya, MD^{a,*}, Uğur Karasu, MD^b, Çiğdem Martin, MD^a, Murat Taşçı, MD^b, Gökhan Pekel, MD^a

Abstract

Background: This study aimed to evaluate the scleral thickness and corneal parameters of patients with systemic lupus erythematosus (SLE).

Methods: Forty-seven eyes of 47 SLE patients and 44 eyes of healthy controls were included in this cross-sectional study. Anterior segment optical coherence tomography (AS-OCT) was used to measure the corneal and scleral thickness. Scleral thickness (ST) was measured based upon the segmentation at 1000 to 5000 μm from the scleral spur. Pentacam HR was used to measure corneal parameters.

Results: There was no statistically significant difference between SLE group and control group according to age and sex ($P > .05$). The ST measurements at all distances from scleral spur were found to be thicker in patients with SLE ($P < .05$). Central corneal thickness (CCT), cornea volume (CV), corneal densitometry (CD), and peripheral corneal thickness (PCT) measurements were similar between the groups ($P > .05$).

Conclusion: ST was thicker in SLE patients compared with healthy controls. AS-OCT seems helpful in selecting optimal sites for pharmaceutical or surgical intervention in SLE patients, since it shows thickness variations in anterior sclera.

Abbreviations: AS-OCT = anterior segment optical coherence tomography, CCT = central corneal thickness, CD = corneal densitometry, CH = corneal hysteresis, CRF = corneal resistance factor, CV = cornea volume, LC = Langerhans cells, PCT = peripheral corneal thickness, SLE = systemic lupus erythematosus, SLEDAI-2K = Systemic Lupus Erythematosus Disease Activity Index 2000, SLICC = Systemic Lupus Erythematosus International Collaborating Clinics, SS = scleral spur, ST = scleral thickness.

Keywords: cornea, optical coherence tomography, peripheral corneal thickness, sclera, scleral thickness, systemic lupus erythematosus

Editor: Jenn-Haung Lai.

This study was supported by scientific research foundation of Hainan provincial health and family planning commission (14A210272).

The authors alone are responsible for the content and writing of the paper.

These data have not been previously published. The authors received no financial support for the research, authorship, and/or publication of this article.

Project number and institution responsible for the approval of the Research Ethics Committee: 20.02.18-04, Pamukkale University Ethics Committee.

The authors have no conflicts of interest to disclose.

Data sharing not applicable to this article as no datasets were generated or analyzed during the current study.

^a Ophthalmology Department, ^b Rheumatology Department, Pamukkale University, Denizli, Turkey.

* Correspondence: Hüseyin Kaya, Ophthalmology Department, Pamukkale University, Denizli, Postal code: 20070, Turkey (e-mail: hsynkaya@gmail.com).

Copyright © 2020 the Author(s). Published by Wolters Kluwer Health, Inc. This is an open access article distributed under the terms of the Creative Commons Attribution-Non Commercial License 4.0 (CCBY-NC), where it is permissible to download, share, remix, transform, and buildup the work provided it is properly cited. The work cannot be used commercially without permission from the journal.

How to cite this article: Kaya H, Karasu U, Martin Ç, Taşçı M, Pekel G. Measurements of scleral thickness and corneal optic densitometry in patients with systemic lupus erythematosus. *Medicine* 2020;99:31(e21467).

Received: 4 March 2020 / Received in final form: 21 June 2020 / Accepted: 25 June 2020

<http://dx.doi.org/10.1097/MD.00000000000021467>

1. Introduction

The worldwide prevalence of systemic lupus erythematosus (SLE) is 0.3 to 23.2 cases per 100,000.^[1] The disease is more common in women than in men.^[2] There are 11 diagnostic criteria: malar rash, discoid rash, oral ulcers, non-erosive arthritis, serositis, photosensitivity, renal disorder, neurological disorder, hematological disorder, immunological disorder, and presence of antinuclear antibodies. Four out of 11 criteria enough for diagnosis.^[3]

Eye findings may correlate with the severity of the disease in SLE. A wide range of ocular involvement can be seen, ranging from simple and treatable conditions such as corneal ocular surface disorder, conjunctivitis, episcleritis to conditions that threaten vision where the retina and optic nerve are involved.^[4] Scleritis and episcleritis were associated with diseases like connective tissue and vasculitic diseases. Disease association was observed in 35.8% of patients with scleritis and 27.1% of patients with episcleritis.^[5] In another study, 1358 cases were examined and the scleritis associated with SLE prevalence was found to be 2%.^[6]

The sclera is the outer connective tissue of the eye that protects and stabilizes the eye's contents from internal and external factors also determines the shape and size of the eye. Factors like age, refractive errors, glaucoma may affect the structure and biomechanical features of the sclera.^[7] The thickness of the sclera has been measured by AS-OCT in several studies.^[7-9] Increased thickness of the sclera was showed by AS-OCT in patients with anterior scleritis.^[10,11]

Collagen fibers (types 1 and 5) constitute the majority of the structure of the corneal stroma.^[12] Sclera consists of mainly type 1 and type 3 collagen.^[13] In this study, we examined the scleral thickness and corneal parameters of SLE patients and normal controls. We hypothesized that scleral thickness and corneal parameters may be altered in SLE patients' eyes due to collagen tissue involvement of the disease.

2. Materials and methods

Forty-seven eyes of 47 SLE patients (41 women, 6 men) and 44 eyes of 44 healthy controls (38 women, 6 men) were included in this cross-sectional study. The institutional board for ethics approved this comparative study and adhered to the standards of the Declaration of Helsinki. Informed consent was obtained from every subject participating in the study.

2.1. Study population

All SLE patients were referred from the Department of Rheumatology for their routine eye examination. The age range of subjects in the groups was between 16 and 72 years. SLE patients were diagnosed by the rheumatology department according to criteria of the American College of Rheumatology.^[3] SLE patients

in this study satisfy the Systemic Lupus Erythematosus International Collaborating Clinics (SLICC) 2012 classification criteria.

The lupus patients' disease activity was evaluated by Systemic Lupus Erythematosus Disease Activity Index 2000 (SLEDAI-2K).^[14] The duration of illness of lupus patients was recorded. The ethnicity of both SLE patients and the control group was Turkish.

All subjects in this study underwent a detailed ophthalmological examination including visual acuity testing, refractive error assessment, biomicroscopy, intraocular pressure measurement, fundus examination, ST measurements by AS-OCT, and Pentacam HR scheinpflug imaging.

Exclusion criteria for SLE patients included the presence of any ocular active surface disease (dry eye, etc), refractive errors $>\pm 2$ diopters, corneal or lenticular opacity, glaucoma, active ocular inflammation, history of ocular trauma, surgery. Chronic inflammatory diseases other than SLE that may affect the eye, current use of topical eye drops, failure of adaptation to measurement techniques were also exclusion criteria.

Seven SLE patients were excluded from the study for various reasons like active scleritis, episcleritis, dry eye, failure of adaptation, and refractive errors. There were no high myopic patients in the SLE patient group, but only 1 patient had high myopia who was excluded from study. The flow diagram of the study is shown in Fig. 1.

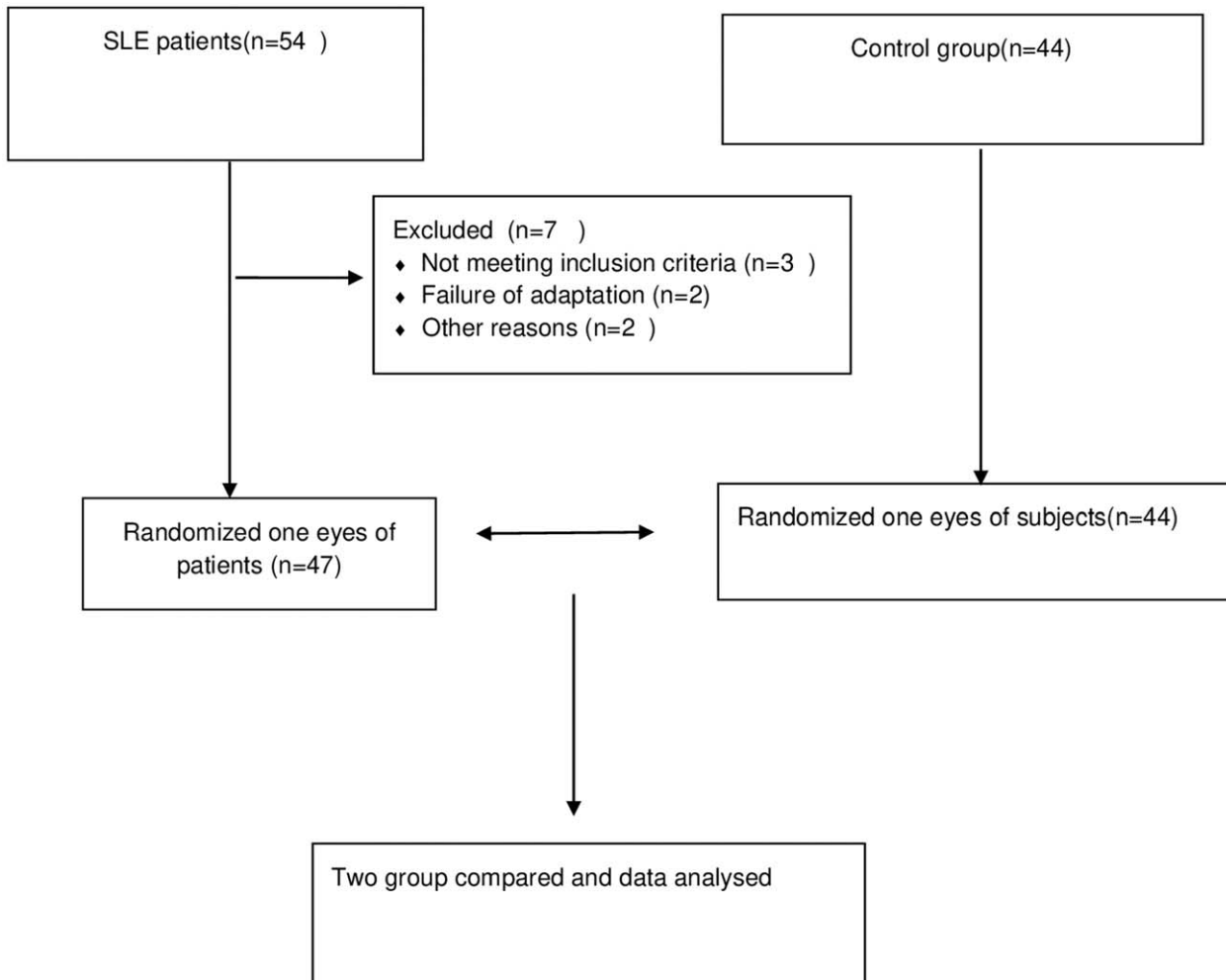


Figure 1. The flow diagram of the study.

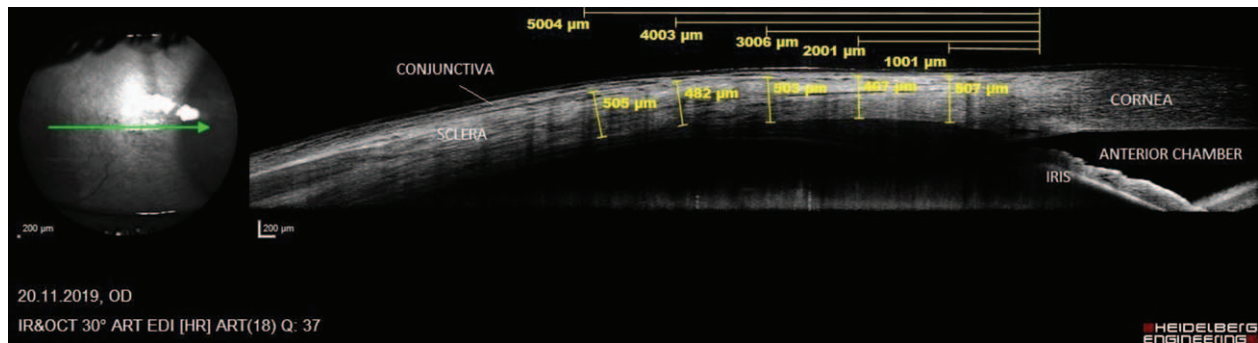


Figure 2. Illustration of the OCT imaging performed on each subject. Scleral thickness was measured by anterior segment optical coherence tomography. The external (red arrow) and internal limit (blue arrow) of the sclera were shown. OCT=optical coherence tomography.

Control subjects were selected from eye clinic who came for routine ophthalmological examination. Any ocular inflammation, history of surgery, refractive errors $>\pm 2$ diopters, any corneal and lenticular diseases, any systemic diseases (diabetes mellitus, rheumatological disease, systemic hypertension, etc), glaucoma, trauma, ocular surface diseases (dry eye, etc), current use of any systemic and topical drugs, contact lens usage were exclusion criteria for control subjects.

2.2. Measurement techniques

One eye of each subject was included in the analysis by a random selection. Randomization was done using a random number generator. The scleral thickness and corneal density were independently assessed by a masked expert. Subjects were examined by using the Spectralis Anterior Segment Module Optical Coherence Tomography (AS-OCT) (Heidelberg Engineering GmbH, Germany) for scleral thickness measurements. Scleral thickness measurements were obtained using a 45° nasal gaze fixated upon a fixation target. Measurements were repeated at least 3 times until the best image quality was achieved. The image quality was checked whether suitable for scleral thickness measurement. Inadequate images or non-cooperative patients were excluded from the study. All measurements in the study were conducted between 9 am and 11 am to avoid diurnal variations. The scleral thickness and the location of the scleral spur (SS) were marked manually. Scleral thicknesses measured based upon the segmentation at approximately 1000, 2000, 3000, 4000, and 5000 μm from the SS. The external limit of the sclera was identified by the deep episcleral vascular plexus, which seen as a thin hyporeflective space above the scleral tissue. Only temporal ST was measured. Figure 2 shows the measurement of the temporal scleral thickness on the OCT image.

The corneal parameters of the subjects were examined by Oculus Pentacam HR (Oculus, Wetzlar, Germany). Central corneal thickness (CCT) and corneal volume (CV) were shown by the Pentacam HR automatically. Corneal curvature measurements; K1, K2, Kmean, Kmax were recorded from screen of the refraction map in Pentacam HR. Also, peripheral corneal thickness (PCT) at the superior, inferior, nasal, and temporal points (at 3 mm from the apex) were shown by the Pentacam HR automatically. But corneal density was measured manually. Several measurements were taken to provide one good-quality image for corneal density calculations. The images of 90° to 270° were determined for all the subjects. The corneal densitometric

measurements were performed on the central 6.0 mm cornea by the areal selection of the stroma. Figure 3 shows the areal corneal densitometric measurements.

2.3. Statistical analysis

The Statistical Package of the Social Sciences 21.0 software was used for statistical analyses (SPSS Inc., Chicago, IL). Continuous variables were expressed as the mean \pm standard deviation, median (minimum and maximum values), and categorical variables as number and percentage. Normal distribution of the data was examined by the Shapiro Wilk test. When the parametric test assumptions were provided, the difference between 2 means test was used to compare independent group differences. Mann-Whitney *U* test was used to compare independent group differences when parametric test assumptions were not provided. When the parametric test assumptions were provided Pearson correlation test was used and Spearman correlation test was used when parametric test assumptions were not provided. Differences between categorical variables were analyzed by Chi-square analysis. $P < .05$ was considered statistically significant.

3. Results

The mean age was 37.9 ± 12.5 years in SLE group and 38.45 ± 13.76 years in control group ($P = .85$). There were 41 women and 6 men in SLE group and 38 women and 6 men in control group ($P = .149$). The mean K1, K2, Kmean, Kmax parameters were 43.47 ± 1.39 , 44.37 ± 1.49 , 43.91 ± 1.43 , 44.96 ± 1.51 diopters in SLE group and 43.20 ± 1.46 , 44.22 ± 1.55 , 43.69 ± 1.47 , 44.90 ± 1.57 diopters in control group respectively. There was no significant difference between SLE and control groups according to K1, K2, Kmean, Kmax ($P = .36$, $P = .63$, $P = .47$, $P = .84$ respectively).

The mean spherical and cylindrical refractive errors were -0.33 ± 0.82 , -0.19 ± 0.48 in SLE group and -0.14 ± 0.84 , -0.08 ± 0.29 in control group respectively. There was no significant difference between SLE and control group according to spherical and cylindrical refractive errors ($P = .29$, $P = .21$ respectively). Eleven of 47 eyes were ametropic in the SLE group, and 12 of 44 eyes were ametropic in the control group. The other eyes in the study were emmetropic. Refractive errors in all eyes included in the study were in the range of ± 1.50 .

The mean \pm standard deviation (μm) ST 1 to 5 mm distances from the scleral spur were shown in Table 1. The ST of SLE group

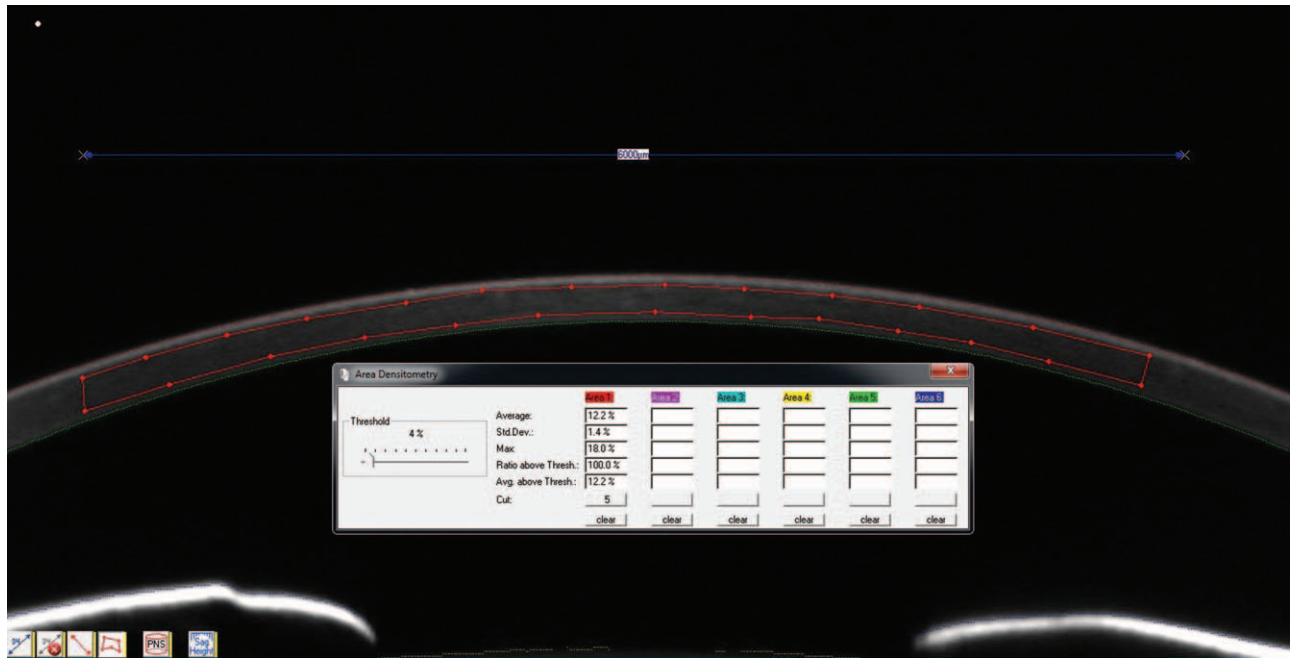

Figure 3. Areal corneal densitometric measurement screen of Pentacam HR.

were thicker than control group. This difference was found significant at all distances ($P = .009, P = .004, P = .039, P = .019, P = .005$ respectively).

The corneal parameters; CCT, CD, CV, and PCT of SLE group and control group were shown in Table 2. There was no statistically significant difference between groups according to CCT, CV, CD ($P = .348, P = .516, P = .081$ respectively). There was no statistically significant difference between SLE and control groups according to PCT measurements at temporal, superior, inferior, and nasal points ($P = .06, P = .1, P = .17, P = .06$ respectively).

The mean SLEDAI-2K score of Lupus patients was 5.62 ± 5.65 (0–26). The mean disease year was 6.97 ± 6.05 (1–30). There was no significant correlation between ST, corneal parameters, and SLEDAI-2K score or disease year ($P > .05$).

Twenty-six out of 47 SLE patients were on low-dose (4–8 mg/d) steroid therapy. Twenty-one patients were not receiving steroid treatment. When patients with and without steroid therapy were compared in terms of ST and corneal parameters, no statistically

significant difference was found between the patient groups ($P > .05$). Table 3 shows ST measurements and corneal parameters of SLE patients with and without steroid treatment.

4. Discussion

The outcomes of the present study showed that ST was thicker in the SLE patients. Although several recent studies have investigated scleritis and episcleritis in SLE patients, to our knowledge this study provides the first report of the ST in SLE patients.^[5,6] Also, there are some studies about superficial keratitis and dry eye but to our knowledge, there is no study of CD, CV, and PCT in SLE patients in the literature according to our knowledge.^[15,16]

Scleritis is an inflammatory eye disease characterized by edema and inflammatory cell infiltration.^[17] Some clinical changes may be seen like refractive changes and scleral thickening because of scleritis.^[10,18] Shoughy et al^[10] showed that patients with active anterior scleritis showed an increased thickness of the sclera measured by OCT. Scleral thickness was measured by AS-OCT in

Table 1
Scleral thickness 1000–5000 μ distances from scleral spur.

| | SLE group | Control group | P values |
|--------|------------------|------------------|----------|
| ST1000 | 587.46 ± 49.22 μ | 561.93 ± 41.81 μ | .009* |
| ST2000 | 573.40 ± 45.39 μ | 544.61 ± 47.47 μ | .004* |
| ST3000 | 586.34 ± 45.39 μ | 565.50 ± 42.16 μ | .039* |
| ST4000 | 607.72 ± 47.03 μ | 585.75 ± 39.82 μ | .019* |
| ST5000 | 627.14 ± 48.59 μ | 600.81 ± 45.90 μ | .005* |

Group1: SLE group, Group 2: healthy controls. ST = scleral thickness. ST1000: scleral thickness at a distance of 1000 μ from scleral spur (SS). ST2000: scleral thickness at a distance of 2000 μ from SS. ST3000: scleral thickness at a distance of 3000 μ from SS. ST4000: scleral thickness at a distance of 4000 μ from SS. ST5000: scleral thickness at a distance of 5000 μ from SS. Results are defined as mean ± standard error of mean. $P < .05$ statistically significant. μ = micron.

*Statistically significant.

Table 2
The pachymetric measurements, CD and CV measurements of patients and controls.

| | SLE group | Control group | P values |
|-----------------------------|------------------|------------------|----------|
| CD | 12.16 ± 1.01 | 12.48 ± 0.68 | .08 |
| CV | 58.98 ± 3.04 | 59.40 ± 2.94 | .51 |
| Pachymetric measurements, μ | | | |
| CCT | 535.10 ± 27.46 μ | 540.97 ± 31.88 μ | .34 |
| 3 mm temporal | 585.76 ± 33.10 μ | 599.93 ± 36.12 μ | .06 |
| 3 mm superior | 642.44 ± 44.07 μ | 657.25 ± 42.28 μ | .10 |
| 3 mm inferior | 604.68 ± 32.31 μ | 614.13 ± 32.80 μ | .17 |
| 3 mm nasal | 620.91 ± 39.80 μ | 635.81 ± 32.72 μ | .06 |

Group1: SLE group, Group 2: healthy controls. CCT = central corneal thickness, CD = corneal densitometry, CV = corneal volume. $P < .05$ statistically significant, results are defined as mean ± standard error of mean. μ = micron.

Table 3**The ST and corneal parameters of SLE patients with and without steroid treatment.**

| | With steroid (N:26) | Without steroid (N:21) | P values |
|---------------|---------------------|------------------------|----------|
| ST1000 | 585.76 ± 47.75 μ | 589.57 ± 52.08 μ | .79 |
| ST2000 | 574.61 ± 34.06 μ | 571.90 ± 57.30 μ | .84 |
| ST3000 | 588.19 ± 50.30 μ | 584.04 ± 54.93 μ | .78 |
| ST4000 | 608.53 ± 46.62 μ | 606.71 ± 48.68 μ | .89 |
| ST5000 | 620.42 ± 52.86 μ | 635.47 ± 42.50 μ | .29 |
| 3 mm temporal | 584.23 ± 34.48 μ | 587.66 ± 32.06 μ | .72 |
| 3 mm superior | 639.53 ± 48.78 μ | 646.04 ± 38.32 μ | .62 |
| 3 mm inferior | 603.38 ± 34.86 μ | 606.28 ± 29.61 μ | .75 |
| 3 mm nasal | 617.46 ± 44.43 μ | 625.19 ± 33.77 μ | .51 |

ST1000: scleral thickness at a distance of 1000 μ from scleral spur (SS). ST2000: scleral thickness at a distance of 2000 μ from SS. ST3000: scleral thickness at a distance of 3000 μ from SS. ST4000: scleral thickness at a distance of 4000 μ from SS. ST5000: scleral thickness at a distance of 5000 μ from SS. 3 mm temporal: 3 mm temporal corneal thickness from the corneal apex. 3 mm superior: 3 mm superior corneal thickness from the corneal apex. 3 mm inferior: 3 mm superior corneal thickness from the corneal apex. 3 mm nasal: 3 mm nasal corneal thickness from the corneal apex. Results are defined as mean ± standard error of mean. *P* < .05 statistically significant. μ = micron.

some recent studies.^[7,8] Buckhurst et al^[8] measured ST at 1 to 6 mm distances from the scleral spur in the normal population. Also, Read et al^[7] measured scleral and conjunctival thickness based on the segmentation at 0, 1, 2, 3, 4 mm from the scleral spur in children and young adults. Similar to these studies, in our study scleral thicknesses were measured at 1 to 5 mm (1 mm intervals) distances from scleral spur and all of the 5 measurements were significantly different from normal subjects. Scleral thicknesses of the SLE group were thicker than the healthy group. There were no signs of active scleritis in eyes of the SLE patients participated in our study. So, the thicker scleral measurements in the SLE group may suggest subclinical inflammation and collagen tissue involvement. AS-OCT may be a useful tool for detection of subclinical inflammation.

Interestingly, there was no correlation between the SLEDAI-2K score or disease year and scleral thickness and other corneal parameters. This result shows that the effect of SLE on connective tissue is independent of disease activity and disease year. The difference between sclera thicknesses was between 21 and 30 μm with the normal group. This difference is lower than the cases with scleritis shown in previous studies.^[10,19] This suggested that there was a subclinical effect on the scleral thickness in SLE.

A study suggested that local antigen/antibody reaction is the main pathology of collagen tissue disorders.^[20] This reaction starts several cellular and biomechanical responses that results from lysis of the corneal collagen and corneal thinning in the collagen tissue disorders.^[20] Peripheral ulcerative keratitis and superficial punctate keratitis may be seen in SLE.^[8] Also, Resch et al^[16] examined Langerhans cells (LC) and dry eye in SLE patients. According to this study, they conclude that SLE alters LC density and morphology; it subsequently modifies corneal homeostasis and might contribute to the development of the dry eye. The biomechanical properties of the cornea were evaluated in patients with SLE in Yazici et al's study. Corneal parameters such as corneal hysteresis (CH), corneal resistance factor (CRF), CCT were found significantly different between SLE and healthy controls. CCT was found lower in the SLE group than the control group.^[20] Similarly in our study; CCT in the SLE patient group were lower than the control group. Also, CV and CD lower than the control group. But there was no significant difference between groups according to CCT, CD, and CV. In our study the number

of lupus patient was 47 but only 30 patients in Yazici et al's study. This difference may cause different results.

The peripheral cornea is well vascularized and available for the deposition of circulating immune complexes. For this reason, the pathological manifestations are more likely to be present in the periphery.^[21] It has been shown in previous studies that rheumatic diseases may affect the periphery of the cornea.^[8,22] For example, peripheral corneal thickness has been shown to decrease in patients with rheumatoid arthritis.^[22] In our study there was no significant difference between SLE and control groups according to PCT measurements at 4 points.

Some SLE patients in our study were using low-dose steroids (4 mg/d). The suppressive effects of steroid use on inflammation are known.^[23] It can be thought that ST and corneal parameters may be affected due to this effect. Therefore in our study, SLE patients were divided into 2 groups according to steroid use. There was no statistically significant difference according to all parameters between the 2 groups. In this study, the steroid dose used by the patients was very low. However, high dose systemic steroid treatment such as 40 to 60 mg applied in the treatment of scleritis.^[24,25] Therefore, ST may not be affected in patients under low dose therapy due to low anti-inflammatory activity.

5. Limitations

As the SLE is seen more frequently in women than in men between 2 and 15 times, the majority of the patients included in the study were women, which makes it difficult to assess male sex.^[26,27] Because of the cross-sectional nature of the study, it was not possible to follow up whether the patients showed signs of active scleritis later. This requires a longer follow-up of patients. Another limitation of the study is that the ST is examined only on the temporal side. The Radius of the scleral curvature was found different from the different sides of the sclera.^[28] Also, the ST varies between different quadrants.^[29]

6. Conclusion

SLE is multi-organs involved systemic disease. Ocular involvement in SLE may cause serious problems. Early detection of damage is very important. In conclusion, patients with SLE present with thicker ST values than controls in this study. The increase in ST has been demonstrated in patients without clinically active scleritis or episcleritis. This suggests that ST may be increased due to connective tissue involvement and subclinical inflammation in SLE. AS-OCT may be a useful tool for detection of subclinical inflammation in eyes of SLE patients and can provide early diagnosis and treatment. AS-OCT may be helpful in selecting optimal sites for pharmaceutical or surgical intervention in SLE patients, since it shows thickness variations in anterior sclera. Ocular damage induced by SLE should be taken seriously and treat accordingly at early stage.

Author contributions

Conceptualization: Hüseyin Kaya, Uğur Karasu, Murat Taşçı, Gökhan Pekel.

Data curation: Hüseyin Kaya, Uğur Karasu, Çiğdem Martin, Murat Taşçı.

Formal analysis: Hüseyin Kaya, Çiğdem Martin, Murat Taşçı.

Investigation: Hüseyin Kaya, Uğur Karasu, Çiğdem Martin, Murat Taşçı.

Methodology: Hüseyin Kaya, Uğur Karasu, Çiğdem Martin, Murat Taşçı.

Project administration: Hüseyin Kaya, Uğur Karasu, Çiğdem Martin.

Resources: Murat Taşçı.

Software: Murat Taşçı.

Supervision: Uğur Karasu, Gökhan Pekel.

Validation: Çiğdem Martin, Gökhan Pekel.

Visualization: Çiğdem Martin.

Writing – original draft: Hüseyin Kaya.

Writing – review & editing: Hüseyin Kaya, Gökhan Pekel.

References

- [1] Rees F, Doherty M, Grainge MJ, et al. The worldwide incidence and prevalence of systemic lupus erythematosus: a systematic review of epidemiological studies. *Rheumatology (Oxford)* 2017;56:1945–61.
- [2] Ward MM. Prevalence of physician-diagnosed systemic lupus erythematosus in the United States: results from the third national health and nutrition examination survey. *J Womens Health (Larchmt)* 2004;13:713–8.
- [3] Yu C, Gershwin ME, Chang C. Diagnostic criteria for systemic lupus erythematosus: a critical review. *J Autoimmun* 2014;48–49:10–3.
- [4] Silpa-archa S, Lee J, Foster CS. Ocular manifestations in systemic lupus erythematosus. *Br J Ophthalmol* 2016;100:135–41.
- [5] Sainz De La Maza M, Molina N, Gonzalez-Gonzalez LA, et al. Clinical characteristics of a large cohort of patients with scleritis and episcleritis. *Ophthalmology* 2012;119:43–50.
- [6] Héron E, Gutzwiller-Fontaine M, Bourcier T. Scleritis and episcleritis: diagnosis and treatment. *Rev Med Interne* 2014;35:577–85.
- [7] Read SA, Alonso-Caneiro D, Vincent SJ, et al. Anterior eye tissue morphology: scleral and conjunctival thickness in children and young adults. *Sci Rep* 2016;6:1–0.
- [8] Buckhurst HD, Gilmartin B, Cubbidge RP, et al. Measurement of scleral thickness in humans using anterior segment optical coherent tomography. *PLoS One* 2015;10:1–0.
- [9] Read SA, Alonso-Caneiro D, Free KA, et al. Diurnal variation of anterior scleral and conjunctival thickness. *Ophthalmic Physiol Opt* 2016;36:279–89.
- [10] Shoughy SS, Jaroudi MO, Kozak I, et al. Optical coherence tomography in the diagnosis of scleritis and episcleritis. *Am J Ophthalmol* 2015;159:1045.e1–9.e1.
- [11] Axmann S, Ebnetter A, Zinkernagel MS. Imaging of the sclera in patients with scleritis and episcleritis using anterior segment optical coherence tomography. *Ocul Immunol Inflamm* 2016;24:29–34.
- [12] Holmes DF, Gilpin CJ, Baldock C, et al. Corneal collagen fibril structure in three dimensions: structural insights into fibril assembly, mechanical properties, and tissue organization. *Proc Natl Acad Sci USA* 2001;98:7307–12.
- [13] Coudrillier B, Pijanka J, Jefferys J, et al. Collagen structure and mechanical properties of the human sclera: analysis for the effects of age. *J Biomech Eng* 2015;137:041006.
- [14] Gladman DD, Ibañez D, Urowitz MB. Systemic lupus erythematosus disease activity index 2000. *J Rheumatol* 2002;29:288–91.
- [15] Messmer EM, Foster CS. Vasculitic peripheral ulcerative keratitis. *Surv Ophthalmol* 1999;43:379–96.
- [16] Resch MD, Marsovszky L, Nemeth J, et al. Dry eye and corneal langerhans cells in systemic lupus erythematosus. *J Ophthalmol* 2015;2015:543835.
- [17] Jabs DA, Mudun A, Dunn JP, et al. Episcleritis and scleritis: clinical features and treatment results. *Am J Ophthalmol* 2000;130:469–76.
- [18] Arellanes-Garcia L, del Carmen Preciado-Delgado M, Garza-Leon M. Refractive changes in patients with autoimmune scleritis. *J Ophthalmic Inflamm Infect* 2011;1:173–5.
- [19] Axmann S, Ebnetter A, Zinkernagel MS. Imaging of the sclera in patients with scleritis and episcleritis using anterior segment optical coherence tomography. *Ocul Immunol Inflamm* 2016;24:1:29–34.
- [20] Yazici AT, Kara N, Yüksel K, et al. The biomechanical properties of the cornea in patients with systemic lupus erythematosus. *Eye (Lond)* 2011;25:1005–9.
- [21] Cao Y, Zhang W, Wu J, et al. Peripheral ulcerative keratitis associated with autoimmune disease: pathogenesis and treatment. *J Ophthalmol* 2017;2017:7298026.
- [22] Gunes A, Inal EE, Tok L, et al. Evaluation of central and peripheral corneal thicknesses in patients with rheumatoid arthritis. *Arq Bras Oftalmol* 2015;78:236–40.
- [23] Cain DW, Cidlowski JA. Immune regulation by glucocorticoids. *Nat Rev Immunol* 2017;17:233–47.
- [24] Smith JR, Mackensen F, Rosenbaum JT. Therapy insight: scleritis and its relationship to systemic autoimmune disease. *Nat Clin Pract Rheumatol* 2007;3:219–26.
- [25] Beardsley RM, Suhler EB, Rosenbaum JT, et al. Pharmacotherapy of scleritis: current paradigms and future directions. *Expert Opin Pharmacother* 2013;14:411–24.
- [26] Michet CJ, McKenna CH, Elveback LR, et al. Epidemiology of systemic lupus erythematosus and other connective tissue diseases in Rochester, Minnesota, 1950 through 1979. *Mayo Clin Proc* 1985;60:105–13.
- [27] Flower C, Hennis AJM, Hambleton IR, et al. Barbados National Lupus Registry Group. Systemic lupus erythematosus in an African Caribbean population: incidence, clinical manifestations, and survival in the Barbados National Lupus Registry. *Arthritis Care Res* 2012;64:1151–8.
- [28] Kasahara M, Shoji N, Morita T, et al. Comparative optical coherence tomography study of differences in scleral shape between the superonasal and superotemporal quadrants. *Jpn J Ophthalmol* 2014;58:396–401.
- [29] Ebnetter A, Häner NU, Zinkernagel MS. Metrics of the normal anterior sclera: imaging with optical coherence tomography. *Graefes Arch Clin Exp Ophthalmol* 2015;53:1575–80.