



Clinicopathological profile of gastrointestinal tuberculosis: a multinational ID-IRI study

Alpaslan Tanoglu¹ · Hakan Erdem² · Jon S. Friedland³ · Fahad M. Almajid⁴ · Ayse Batirel⁵ · Sholpan Kulzhanova⁶ · Maiya Konkayeva⁶ · Zauresh Smagulova⁶ · Filiz Pehlivanoglu⁷ · Sophia de Saram⁸ · Serda Gulsun⁹ · Fatma Amer¹⁰ · Ilker Inanc Balkan¹¹ · Recep Tekin¹² · Antonio Cascio¹³ · Nicolas Dauby¹⁴ · Fatma Sirmatel¹⁵ · Meltem Tasbakan¹⁶ · Aysegul Erdem¹⁷ · Ahmed Ashraf Wegdan¹⁸ · Ozlem Aydin¹⁹ · Salih Cesur²⁰ · Secil Deniz²¹ · Seniha Senbayrak²² · Affan Denk²³ · Tolga Duzenli¹ · Soline Siméon²⁴ · Ahsen Oncul²⁵ · Burak Ozseker²⁶ · Tolga Yakar²⁷ · Necati Ormeci²⁸

Received: 20 September 2019 / Accepted: 24 October 2019
© Springer-Verlag GmbH Germany, part of Springer Nature 2019

Abstract

Data are relatively scarce on gastro-intestinal tuberculosis (GITB). Most studies are old and from single centers, or did not include immunosuppressed patients. Thus, we aimed to determine the clinical, radiological, and laboratory profiles of GITB. We included adults with proven GITB treated between 2000 and 2018. Patients were enrolled from 21 referral centers in 8 countries (Belgium, Egypt, France, Italy, Kazakhstan, Saudi Arabia, UK, and Turkey). One hundred four patients were included. Terminal ileum ($n = 46$, 44.2%), small intestines except terminal ileum ($n = 36$, 34.6%), colon ($n = 29$, 27.8%), stomach ($n = 6$, 5.7%), and perianal (one patient) were the sites of GITB. One-third of all patients were immunosuppressed. Sixteen patients had diabetes, 8 had chronic renal failure, 5 were HIV positive, 4 had liver cirrhosis, and 3 had malignancies. Intestinal biopsy samples were cultured in 75 cases (78.1%) and TB was isolated in 65 patients (86.6%). PCR were performed to 37 (35.6%) biopsy samples and of these, 35 (94.6%) were positive. Ascites samples were cultured in 19 patients and *M. tuberculosis* was isolated in 11 (57.9%). Upper gastrointestinal endoscopy was performed to 40 patients (38.5%) and colonoscopy in 74 (71.1%). Surgical interventions were frequently the source of diagnostic samples (25 laparoscopy/20 laparotomy, $n = 45$, 43.3%). Patients were treated with standard and second-line anti-TB medications. Ultimately, 4 (3.8%) patients died and 2 (1.9%) cases relapsed. There was a high incidence of underlying immunosuppression in GITB patients. A high degree of clinical suspicion is necessary to initiate appropriate and timely diagnostic procedures; many patients are first diagnosed at surgery.

Keywords Tuberculosis · Immune-suppression · Gastro-intestinal · Endoscopy · Treatment

Introduction

Tuberculosis (TB) remains a global problem with substantial morbidity [1, 2]. An estimated 54 million lives were saved through TB diagnosis and treatment between 2000 and 2017 [3]. It has been reported that the gastrointestinal tract is the sixth most prevalently encountered extra-pulmonary region of TB infection [4]. Before anti-TB drugs were developed, autopsy studies showed that the gastrointestinal system was involved in over 90% cases [5]. Gastrointestinal tuberculosis (GITB) can be a primary focus of concern, or a secondary

tuberculosis infection may co-exist with a TB infection at another primary site [6]. Over the past two decades, the incidence of GITB is reported to have continuously increased, in part due to increasing incidence of HIV infection and the frequent use of immunosuppressive drugs [2, 7], although the impact of improved diagnostic microbiological and histological methodology is unknown. However, recent data is extremely scarce GITB in the literature.

GITB is likely to be significantly under-diagnosed by physicians and may present first to surgeons who may not think of TB in association with bowel symptoms. GITB is a great mimic of other diseases including malignancy, inflammatory bowel disease, and appendicitis [8]. Many reports of GITB are limited either in the number of cases included or in the focus on a local geographic area and others pre-date current diagnostic and treatment protocols. Therefore, in this multinational

✉ Hakan Erdem
hakanerdem1969@yahoo.com

Extended author information available on the last page of the article

study, we aimed to assess the clinical, radiological, laboratory and endoscopic profiles of GITB in order to provide insights to diagnosis and timely treatment of the disease in the twenty-first century.

Methods

Study design

This study was a retrospective cohort design. Local ethics committee approval was obtained before the data collection. Patients were enrolled from 21 referral centers in 8 countries including Belgium, Egypt, France, Italy, Kazakhstan, Saudi Arabia, UK, and Turkey.

Patient selection

All centers on the ID-IRI network were contacted to participate and 21 had sufficient records and volunteered to be involved. This study included all consecutive patients treated at the participating centers with GITB between 2000 and 2018. Adult patients (> 18 years of age) were included. Other inclusion criteria comprised patients with one of the following:

- a) The presence of typical histopathological findings consistent with intestinal tuberculosis.
- b) (1) Recovery of *M. tuberculosis* in intestinal tissue and/or ascitic fluid culture (solid Lowenstein Jensen media), (2) acid fast bacteria (AFB) positivity in the tissue/ascitic fluid specimens, and (3) PCR positivity for *M. tuberculosis* in the tissue/ascitic fluid specimens.

Data collection

A questionnaire in word format and a complementary excel file were sent to the all participating centers. Data was collected on sociodemographic patterns, presenting complaints, clinical features, comorbid conditions, laboratory parameters, and imaging findings including abdominal ultrasonography, computed tomography (CT), and magnetic resonance imaging (MRI). The results of endoscopic and colonoscopic interventions, surgical intervention, and subsequent histopathological analysis were documented. Microbiological culture of all specimens was detailed. In addition, where performed, PCR testing of the biopsy specimen and serological analysis were documented. Finally, details of patient treatment were collected.

Research centers submitted their data as an excel document and the final database was produced by merging these excel sheets.

The normal values for blood tests used in investigation of tuberculosis were hemoglobin [14.0–17.5 g/dL for males and 12.3–15.3 g/dL for females] [9], white blood cells [WBC (4000–11,000/mm³)] [10], and erythrocyte sedimentation rate [ESR (0–22 mm/h for men, 0–29 mm/h for women)] [11]. The cut-off value of ADA in ascitic fluid was > 39 IU/L [12].

Results

A total of 122 patients were reported from the centers but 18 patients were excluded due to missing data. Hence, 104 patients from 21 centers were analyzed in this study. Patients had a mean age of 39.5 ± 13.9 years. Fifty-four cases (51.9%) were females. Patient characteristics are presented in Table 1. Forty-five (43.3%) patients were potentially immunosuppressed. Diabetes mellitus, chronic renal failure, HIV infection, Chron's disease, malignancy, cirrhosis, rheumatoid diseases, and immunosuppressive drug use were the reasons of potential immunosuppression (Table 1). Most commonly used immunosuppressive medications were cyclophosphamide, steroids, azathioprine, and biological agents. Symptoms and clinical findings of patients with GITB are presented in Table 2. The coexistence of systemic symptoms fever, night sweats, malaise, or loss of appetite were as follows: none ($n = 2$, 1.9%), one of them ($n = 3$, 1.9%), two ($n = 16$, 1.9%), three ($n = 35$, 1.9%), and all of them ($n = 47$, 1.9%).

Sites of involvement

Terminal ileum ($n = 46$, 44.2%), small intestines (except terminal ileum) ($n = 36$, 34.6%), colon ($n = 29$, 27.8%), stomach ($n = 6$, 5.7%), and perianal region (only one patient) were the sites of GITB in descending order of frequency (Fig. 1). Forty-one patients (39.5%) had a second co-existing focus of TB

Table 1 Patient's characteristics of cases with intestinal tuberculosis

Patient characteristics	Cases ($n = 104$)	Percent (%)
Previous TB history	20	19.2
Potential contact with a TB patient	18	17.3
Diabetes mellitus	16	15.3
Immunosuppressive drug use*	13	
Regular or social drinker	9	8.6
Chronic renal failure	14	7.6
Rheumatoid diseases	7	6.7
HIV positivity	5	4.8
Cirrhosis	4	3.8
Crohn's disease	3	2.8
Malignancy **	4	2.8

Tb tuberculosis, *M* male, *F* female, * Including systemic steroids, ** 2 Lymphomas, gastric cancer, prostate cancer

Table 2 Clinical presentation on hospital admission

Symptoms	Cases (<i>n</i> = 104)	Percent (%)
Non-specific symptoms		
Loss of appetite	94	90.2
Weakness	91	87.5
Night sweating	70	67.3
Fever	69	66.3
Weight loss	52	50
Specific symptoms		
Abdominal pain	80	76.9
Abdominal distension	60	57.7
Nausea/vomiting	46	44.2
Diarrhea	25	24
Constipation	22	21.2
Back pain	15	14.2
Bloody defecation	11	10.6
Clinical signs		
Mean temperature	37.67 ± 0.96 °C	
Ascites	26	25
Hepatomegaly	20	19.3
Palpable abdominal mass in		
• Right lower quadrant	20	19.3
• Right iliac fossa	20	19.3
Splénomegaly	15	14.2
Palpable lymphadenopathies	14	13.5
Perianal fistula	1	0.9

infection. The location of the second site of infection was pulmonary TB in 29 patients (27.8%), peritoneal TB in 8 cases (7.6%), genitourinary TB in 3 patients (2.8%), hepatobiliary TB in 2 patients (1.9%), and in one case there was confirmed, concurrent central nervous system TB.

Biochemical tests

Blood hematological and biochemical tests are presented in Table 3. Ninety-four (90.4%) cases were anemic. Fifteen (14.4%) patients had leucopenia and 17 (16.3%) had leukocytosis, and ESR was elevated in 72 (69.2%) cases.

Diagnostic tests

Median adenosine deaminase (ADA) level was 86 U/L (range 14–119 U/L) in ascitic sampling materials. Interferon gamma release assay (IGRA) tests were performed in 14 patients (13.5%); of these, 12 were positive (86%). Tuberculin skin test was performed to 50 patients (48%); 44 of them were positive in GITB (88%).

Microbiological data

Ninety-three (89.4%) patients had one positive microbiological diagnosis. Intestinal biopsy was performed in 93 patients and biopsy samples were cultured in 81 (87.1%) cases. TB was isolated in 63 (78.8%) of the biopsy specimens. Rectal discharge/smear culture was performed in 26 patients and TB was isolated in 10 cases (38.4%) cases. Ascites samples were cultured in 19 (18.3%) patients and *M. tuberculosis* was isolated in 11 (57.9%) ascitic fluid samples cultured. EZN staining positivity was as follows: biopsy specimens (*n* = 18, 20%), sputum (*n* = 7), rectal discharge (*n* = 4), ascitic fluid (*n* = 1), and lymph node (*n* = 1). PCR were performed in 37 (35.6%) biopsy samples and of these, 35 (94.6%) samples were positive for TB.

Histopathological sampling

Intestinal biopsy materials were obtained by either endoscopic sampling, percutaneous biopsy, or surgical interventions. Main histopathological findings were caseation (*n* = 52/82, 63.4%) and granuloma formation (*n* = 30/82, 36.6%).

- Endoscopic interventions: Upper gastrointestinal endoscopy was performed to 43 patients (41.3%). The distribution of upper endoscopic findings was as follows: Gastritis (*n* = 11, 25.5%), gastric ulcer (*n* = 7, 16.2%), gastric mass (*n* = 5, 11.6%), esophageal ulcer (*n* = 5, 11.6%), esophagitis (*n* = 2, 4.7%), esophageal mass (*n* = 1, 2.3%), duodenitis (*n* = 3, 6.9%), and duodenal stricture (*n* = 1, 2.3%). Colonoscopy was performed in 96 cases (92.3%). The distribution of colonoscopic findings was as follows: terminal ileal inflammation/edema (*n* = 31, 32.3%), terminal ileal ulcer (*n* = 29, 30.2%), terminal ileal stenosis (*n* = 15, 15.6%), colonic ulcers (*n* = 21, 21.9%), and colonic nodules/polyps (*n* = 4, 4.2%).
- Invasive procedures: Surgical interventions (*n* = 50, 48.1% patients) reported were 32 laparoscopic procedures and 20 laparotomies (combined = 2). There were 12 percutaneous procedures (11.5%) performed to provide diagnostic samples. Terminal ileum edema (*n* = 14, 31.1%), enlarged mesenteric lymph nodes (*n* = 10, 22.2%), dilated bowel loops (*n* = 9, 20%), ascites (*n* = 8, 17.8%), and peritoneal thickening (*n* = 7, 15.6%) were the findings reported following surgical interventions.

Radiological assessment

The results of abdominal ultrasonography (USG) and CT scanning are presented in Table 4. The main findings were of hepato-splenomegaly, ascites, para-aortic lymphadenopathy, and increased intestinal wall thickness together with

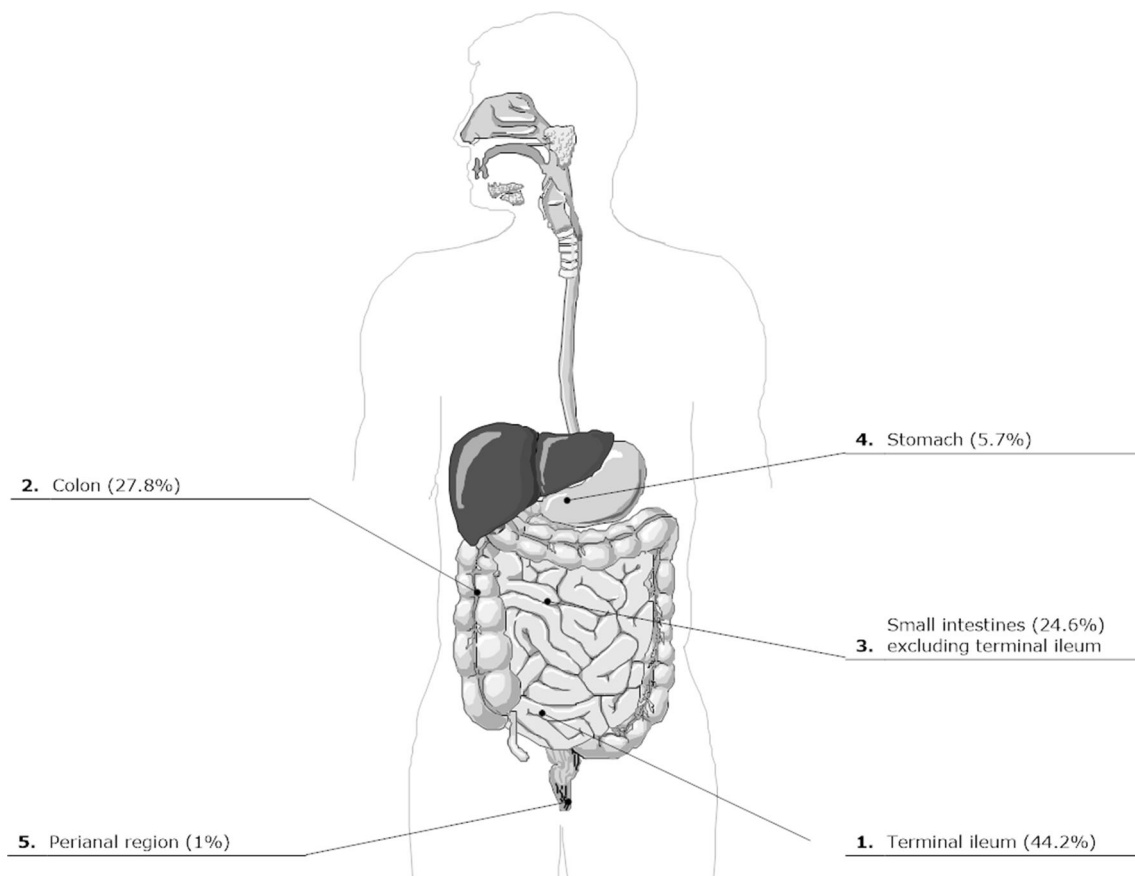


Fig. 1 Distributions of intestinal tuberculosis lesions

irregularity. MRI imaging was performed in just 10 (9.6%) cases and was not presented due to scarcity of the MRI data.

Treatment modalities

Median time elapsing from the onset of symptoms to hospital admission was 60 days (range 8 days to 28 months) and to initiation of tuberculosis treatment was 70 days (range 10 days to 30 months). Although 103 participants were given anti-TB

treatment, one died before the start of anti-TB medications. Response to therapy was followed basically in clinical and laboratory terms. The median (interquartile range, IQR) treatment duration was 7 months (6–9 months). Anti-TB medications used were as follows: Isoniazid ($n = 96$), rifampicin ($n = 96$), pyrazinamide ($n = 96$), ethambutol ($n = 96$), streptomycin ($n = 7$), ofloxacin ($n = 4$), morfozinamid ($n = 3$), moxifloxacin ($n = 3$), oral rifabutin ($n = 1$), amikacin ($n = 3$), rimactazide ($n = 1$), prothionamide ($n = 2$), cycloserine ($n = 3$), linezolid ($n = 1$), para-aminosalicylic acid ($n = 1$), and bedaquiline ($n = 1$).

Table 3 Biochemical parameters of the patients

Variable	Data (mean \pm SD or median)
Hemoglobin (mg/dL)	9.03 \pm 3.54
Leucocyte count (/mm ³)	6900 (1800–24,300)
Platelet count (/mm ³)	274,000 (70000–950,000)
Erythrocyte sedimentation rate (mm/h)	53.5 \pm 37.5
C-reactive protein (mg/dL)	21.3 (0.2–403)
Alanine aminotransferase (IU/L)	35 (4–347)
Aspartate aminotransferase (IU/L)	38 (7–390)
Creatinine (mg/dL)	0.98 (0.5–6.14)
Albumin (mg/dL)	3.11 \pm 0.74
Total protein (mg/dL)	6.32 \pm 0.96

Outcomes

Relapse of TB occurred in 2 (1.9%) cases, 1.5, and 12 months after the end of initial therapy. Relapsers were treated with the standard anti-TB medications. Finally, 4 patients were reported to have died. Two cases were likely to die of military tuberculosis. Third case with chronic renal failure and ascites experienced toxic hepatitis and subsequently died. Fourth patient with HIV infection (CD⁺ count 24/ml) died of postoperative complications after intestinal repair due to perforation. Complications observed after the hospitalization were toxic hepatitis ($n = 7$, 6.7%), ileus and/or subileus ($n = 6$, 5.7%),

Table 4 Abdominal ultrasonography and computerized tomography findings of cases

	USG (<i>n</i> = 92, %)		CT (<i>n</i> = 80, %)	
Hepatomegaly and other liver findings	30	32.6	25	31.2
Ascites	30	32.6	26	32.5
Enlarged para-aortic lymph nodules	27	29.3	23	28.8
Splenomegaly	19	20.3	16	20
Terminal ileum thickness and irregularity	15	14.2	26	32.5
Asymmetric wall thickness of intestine	13	14.1	12	15
Intra-abdominal abscess	3	3.2	3	3.8

intestinal perforation and/or fistula (*n* = 5, 4.8%), and death (*n* = 4, 3.8%).

Discussion

To the best of our knowledge, this current study is the first multinational research on GITB and it the largest case series to date. It is also the first to report in the era of modern diagnostic tests for GITB. The data show very high levels of underlying immune-suppression in the current cohort of patients. However, we found that GITB was a relatively benign and an easily curable disease with standard medications. The terminal ileum was the most frequent site of involvement in GITB followed by the rest of small intestines. A second focus of TB involvement was observed in up to two-fifths of the patients. Endoscopic and surgical interventions were the principal procedures to provide diagnostic samples in GITB patients. GITB appears to have combined the systemic symptoms of TB and the mechanical intestinal disease.

GITB-related symptoms are thought to be non-specific in several scientific papers [13–15], and in our patient group, loss of appetite, weakness, abdominal pain, night sweating, fever, abdominal distension, weight loss, and nausea/vomiting were the frequent complaints while ascites, hepatomegaly, palpable abdominal mass, spleen enlargement, and palpable lymph nodes were common clinical signs. Thus, there are a mixture of symptoms and signs relating to systemic infection and to local disease pathology. Although all these findings are not specific to GITB, their combination may be helpful in strengthening the clinical suspicion of GITB. In the current study, it was striking that many of the GITB patients had underlying comorbid conditions and 43.3% were immune-suppressed for diverse reasons. The importance of altered immune function in driving GITB has not previously been described. Over 15% GITB patients were diabetic, which is now an established risk factor for tuberculosis [16], and 10% had renal failure or hepatic cirrhosis. Nineteen percent of patients had experienced TB previously, which is high and may reflect reactivation or re-infection.

Although HIV infection was infrequent in our population (< 5%), low median CD4 count of the cases may have contributed to the development of GITB [17]. Coexistence of Crohn's disease and GITB (2.8%) was reported which is important as inflammatory bowel disease is often considered in the differential diagnosis, and these may easily be confounded by the examining physicians [18].

TB may affect any part of the gastrointestinal tract. Its clinical picture may imitate a wide range of other intestinal disorders, both in an overt or covert manner [19]. Our present study was consistent with previously published data confirming that the terminal ileum/ileocecal region was the most commonly affected area in GITB [13, 20]. This part of intestinal system is a site of physiological stasis, which extends duration of contact between TB bacilli and the mucosa. The rest of small intestines, colon, stomach, and perianal region were the other sites of GITB in descending order. An interesting observation in the present study was the concurrent finding of extra-intestinal TB involvement in 40% of cases, with pulmonary TB being the most common but many other sites also involved. Extra-intestinal TB involvement was noted in earlier reports with a diversity of 15–40% in different regions of the world [1, 4, 21, 22].

Colonoscopy and endoscopy can help health professionals locate and investigate GITB [21]. In our current research, 38.5% of the patients underwent endoscopy and 71.1% experienced colonoscopy. During colonoscopy, terminal ileal inflammation/edema and terminal ileal ulcers were diagnosed in 40% patients followed by terminal ileal stenosis, colonic ulcers, and colonic masses. These findings were similar to previous reports [13, 19, 23] and confirm that such endoscopic appearances may have diagnostic value for GITB although biopsies are essential. Regarding radiological imaginary modalities, abdominal USG and CT were the most frequently used diagnostic methods. Different rates of radiological features of GITB were reported in previous papers with small case series [1, 23, 24]. Approximately one-third of the cases in this study presented with thickness and irregularity at terminal ileum, ascites, enlarged para-aortic lymph nodules, and spleen and liver enlargement indicating probable TB.

Ultrasound scans appeared as useful as CT in terms of delineating lesions for biopsy which may reflect the fact that TB patients tend to be relatively cachectic.

Most patients were anemic but neither this nor leukocyte count which was raised as often as it was suppressed, were helpful in diagnosis. The majority of patients had evidence of systemic inflammation with a raised ESR, CRP, and leukocytosis. ADA was frequently elevated. IGRA tests were negative in 14% patients, and similarly tuberculin skin tests were negative in 12% patients due to immunosuppression, despite the presence of active TB disease. Intestinal biopsy was the major diagnostic approach with subsequent microbiological tests. Laboratory culture of infected biopsy material yielded the majority of diagnoses although both stool and ascitic fluid cultures were useful. Two-thirds of the histopathological analyses in this study showed caseous necrosis, which is strongly indicative of TB [25]. However, detection of granuloma formation alone is not ideal and requires microbiological confirmation of diagnosis since granulomas are found in other intestinal disorders like inflammatory bowel diseases [26].

Exact diagnosis of GITB cases is generally delayed since clinical presentation is usually insidious, and radiological imaging and laboratory test results may be inconclusive. In addition, the diverse physicians and surgeons to whom these patients present, may not consider the diagnosis of GITB at an early stage. In this current study, the time elapsing from the onset of symptoms to hospital admission and the start of treatment varied greatly indicating the subtle behavior of the disease; we observed a mean of 70 days delay from symptoms to start of the treatment. Unfortunately, one patient in this study died before receiving anti-TB medications.

The major limitation of this current research is its retrospective design but in practice, it is very hard to gather such data from so many centers over such a long period prospectively. In part for this reason, it is also not possible to get a definitive estimate of the frequency of GITB in the population from our study. In addition, since this study covers a 19-year period and includes various centers, antibiotic susceptibility testing was done in a small group of cases. Thus, we could not provide data for multidrug resistance tuberculosis cases.

In conclusion, GITB generally presents in either sex most often during middle age, and frequently in patients who are either overtly immune-suppressed or who have conditions such as diabetes mellitus or chronic renal failure which impair immune system function. GITB cases often presents with non-specific symptoms and signs which are easily confused with malignancies and inflammatory bowel diseases [27, 28]. Thus, diagnosis is initially dependent on a high index of suspicion. Misdiagnosed and delayed presentations of patients are of major concern, and may result in unnecessary medical or surgical interventions and in mortality. In order to make a diagnosis, targeted endoscopic or percutaneous biopsies following use of ultrasound scans is probably the best approach

which may avoid surgery in many patients. Relatively low mortality (3.8%) in our cohort given standard anti-TB treatment indicates the importance of accurate diagnosis and timely treatment in GITB cases.

Compliance with ethical standards

Conflict of interest The authors declare that they have no conflict of interest.

Ethical approval Turkish Health Sciences University Non-interventional Studies Ethical Counsel in Istanbul approved the study (06/07/2018; 18/19).

Informed consent Not applicable.

References

- Gan H, Mely M, Zhao J, Zhu L (2016) An analysis of the clinical, endoscopic, and pathologic features of intestinal tuberculosis. *J Clin Gastroenterol* 50:470–475. <https://doi.org/10.1097/MCG.0000000000000514>
- Daley CL (2019) The global fight against tuberculosis. *Thorac Surg Clin* 29:19–25. <https://doi.org/10.1016/j.thorsurg.2018.09.010>
- Tuberculosis [Internet]. World Heal. Organ. [cited 2019 20]. <https://www.who.int/en/news-room/fact-sheets/detail/tuberculosis>
- Marshall J (2000) Tuberculosis of the gastrointestinal tract and peritoneum. *Am J Gastroenterol* 88:989–999
- Granet E (1934) Intestinal tuberculosis. A clinical, roentgenological and pathological study of 2086 patients affected with pulmonary tuberculosis. *Am J Dig Dis Nutr* 2:209–214
- Jung HJ, Kim YH, Kim YS, Jeong SY, Park SW, Seo JY et al (2016) Differences in clinical manifestations according to the positivity of interferon-assay in patients with intestinal tuberculosis. *Gut Liver* 10:649–652. <https://doi.org/10.5009/gnl15439>
- Yamane T, Umeda A, Shimao H (2014) Analysis of recent cases of intestinal tuberculosis in Japan. *Intern Med* 53:957–962. <https://doi.org/10.2169/internalmedicine.53.1862>
- De Saram S, Friedland JS (2019) Gastrointestinal and peritoneal tuberculosis. In: Senar A, Erdem H (eds) *Extrapulmonary tuberculosis*. Springer, Switzerland, pp 25–42
- Vajpayee N, Graham S, Bem S (2011) Basic examination of blood and bone marrow. In: McPherson R, Pincus M (eds) *Henry's clinical diagnosis and management by laboratory methods*. Elsevier Co, Philadelphia, pp 509–535
- Kim AH, Lee W, Kim M, Kim Y, Han K (2014) White blood cell differential counts in severely leukopenic samples: a comparative analysis of different solutions available in modern laboratory hematology. *Blood Res* 49:120–126. <https://doi.org/10.5045/br.2014.49.2.120>
- Sed rate (erythrocyte sedimentation rate) [Internet]. [cited 2019 20]. <https://www.mayoclinic.org/tests-procedures/sed-rate/about/pac-20384797>
- Riquelme A, Calvo M, Salech F, Valderra S, Pattillo A, Arellano M et al (2006) Value of adenosine deaminase (ADA) in ascitic fluid for the diagnosis of tuberculous peritonitis: a meta-analysis. *J Clin Gastroenterol* 40:705–710
- Patel B, Yagnik VD (2018) Clinical and laboratory features of intestinal tuberculosis. *Clin Exp Gastroenterol* 11:97–103

14. Alvares J, Devarbhavi H, Makhija P, Rao S, Kottoor T (2006) Clinical, colonoscopic, and histological profile of colonic tuberculosis in a tertiary hospital. *Endoscopy* 37:351–356
15. Villanueva S, Martinez H, ATFJ F, Valdes O (2002) Colonic tuberculosis. *Dig Dis Sci* 47:2045–2048
16. Dooley KE, Chaisson RE (2009) Tuberculosis and diabetes mellitus: convergence of two epidemics. *Lancet Infect Dis* 9:737–746. [https://doi.org/10.1016/S1473-3099\(09\)70282-8](https://doi.org/10.1016/S1473-3099(09)70282-8)
17. Tornhem J, Dooley K (2017) Tuberculosis Associated with HIV Infection. *Microbiol Spectr* 5:(1). <https://doi.org/10.1128/microbiolspec>
18. Onal IK, Kekilli M, Tanoglu A, Erdal H, Ibis M, Arhan M (2015) Tuberculosis and Crohn's disease revisited. *J Coll Physicians Surg Pak* 25:443–448
19. Shi XC, Zhang LF, Zhang YQ, Liu XQ, Fei GJ (2016) Clinical and laboratory diagnosis of intestinal tuberculosis. *Chin Med J* 129:1330–1333. <https://doi.org/10.4103/0366-6999.182840>
20. Ouyang Q, Tandon R, Goh K, Ooi C, Ogat AH, Fiocchi C (2005) The emergence of inflammatory bowel disease in the Asian Pacific region. *Curr Opin Gastroenterol* 21:408–413
21. Bhargava D, Kushwaha A, Dasarathy S, Chopra P (1992) Endoscopic diagnosis of segmental colonic tuberculosis. *Gastrointest Endosc* 38:571–574
22. Wani M, Parvez M, Kumar SH, Naikoo GM, Jan M, Wani HA (2015) Study of surgical emergencies of tubercular abdomen in developing countries. *Indian J Surg* 77:182–185. <https://doi.org/10.1007/s12262-012-0755-6>
23. Wang J, Cheng W, Zhang S, Li Y, Li J (2019) Intestinal tuberculosis: clinico-pathological profile and the importance of a high degree of suspicion. *Tropical Med Int Health* 24:81–90. <https://doi.org/10.1111/tmi.13169>
24. Sinan T, Sheikh M, Ramadan S, Sahwney S, Behbehani A (2002) BMC Medical Imaging CT features in abdominal tuberculosis: 20 years experience. *BMC Med Imaging* 2:1–7 <https://www.ncbi.nlm.nih.gov/pmc/articles/PMC139990/pdf/1471-2342-2-3.pdf>
25. Grosset J (2003) Mycobacterium tuberculosis in the extracellular compartment: an underestimated adversary. *Antimicrob Agents Chemother* 47:833–836. <https://doi.org/10.1128/AAC.47.3.833>
26. Molnár T, Tiszlavicz L, Gyulai C, Nagy F, Lonovics J (2005) Clinical significance of granuloma in Crohn's disease. *World J Gastroenterol* 11:3118–3121. <https://doi.org/10.3748/wjg.v11.i20.3118>
27. Kedia S, Das P, Madhusudhan KS, Dattagupta S, Sharma R, Sahni P et al (2019) Differentiating Crohn's disease from intestinal tuberculosis. *World J Gastroenterol* 25:418–432. <https://doi.org/10.3748/wjg.v25.i4.418>
28. Liu Y-Y, Chen M-K, Cao Z, Liu S-Z, Ding B-J (2014) Differential diagnosis of intestinal tuberculosis from Crohn's disease and primary intestinal lymphoma in China. *Saudi J Gastroenterol* 20:241–247. <https://doi.org/10.4103/1319-3767.136979>

Publisher's note Springer Nature remains neutral with regard to jurisdictional claims in published maps and institutional affiliations.

Affiliations

Alpaslan Tanoglu¹ · Hakan Erdem²  · Jon S. Friedland³ · Fahad M. Almajid⁴ · Ayse Batirel⁵ · Sholpan Kulzhanova⁶ · Maiya Konkayeva⁶ · Zauresh Smagulova⁶ · Filiz Pehlivanoglu⁷ · Sophia de Saram⁸ · Serda Gulsun⁹ · Fatma Amer¹⁰ · Ilker Inanc Balkan¹¹ · Recep Tekin¹² · Antonio Cascio¹³ · Nicolas Dauby¹⁴ · Fatma Sirmatel¹⁵ · Meltem Tasbakan¹⁶ · Aysegul Erdem¹⁷ · Ahmed Ashraf Wegdan¹⁸ · Ozlem Aydin¹⁹ · Salih Cesur²⁰ · Secil Deniz²¹ · Seniha Senbayrak²² · Affan Denk²³ · Tolga Duzenli¹ · Soline Siméon²⁴ · Ahsen Oncul²⁵ · Burak Ozseker²⁶ · Tolga Yakar²⁷ · Necati Ormeci²⁸

¹ Department of Gastroenterology, Sultan Abdülhamid Han Training and Research Hospital, Istanbul, Turkey

² ID-IRI, Ankara, Turkey

³ St. George's University of London, London SW17 0RE, UK

⁴ Department of Medicine, Infectious Diseases Division, King Saud University, Riyadh, Saudi Arabia

⁵ Department of Infectious Diseases and Clinical Microbiology, University of Health Sciences, Dr. Lutfi Kirdar Training and Research Hospital, Istanbul, Turkey

⁶ Department of Infectious Diseases, Astana Medical University, Astana, Kazakhstan

⁷ Department of Infectious Diseases and Clinical Microbiology, Haseki Training and Research Hospital, Istanbul, Turkey

⁸ North Middlesex University Hospital NHS Trust, London, UK

⁹ Department of Infectious Diseases and Clinical Microbiology, Diyarbakir Training and Research Hospital, Diyarbakir, Turkey

¹⁰ Department of Medical Microbiology and Immunology, Faculty of Medicine, Zagazig University, Zagazig, Egypt

¹¹ Department of Infectious Diseases and Clinical Microbiology, Cerrahpasa School of Medicine, Istanbul University-Cerrahpasa, Istanbul, Turkey

¹² Department of Infectious Diseases and Clinical Microbiology, Dicle University Faculty of Medicine, Diyarbakir, Turkey

¹³ Department of Health Promotion Sciences, Maternal and Infant Care, Internal Medicine and Medical Specialties (PROMISE) - Infectious Disease Unit, Policlinico "P. Giaccone", University of Palermo, Palermo, Italy

¹⁴ Department of Infectious Diseases, Centre Hospitalier Universitaire Saint-Pierre, Université libre de Bruxelles (ULB), 322 rue Haute, 1000 Brussels, Belgium

¹⁵ Department of Infectious Disease and Clinical Microbiology, Izzet Baysal University School of Medicine, Bolu, Turkey

¹⁶ Department of Infectious Disease and Clinical Microbiology, Ege University School of Medicine, Izmir, Turkey

¹⁷ Department of Pathology, Kecioren Training and Research Hospital, Ankara, Turkey

¹⁸ Department of Medical Microbiology and Immunology, Faculty of Medicine, Fayoum University, Fayoum, Egypt

- ¹⁹ Department of Infectious Diseases and Clinical Microbiology, Goztepe Training and Research Hospital, Istanbul, Turkey
- ²⁰ Department of Infectious Diseases and Clinical Microbiology, Ankara Training and Research Hospital, Ankara, Turkey
- ²¹ Department of Infectious Diseases and Clinical Microbiology, Pamukkale University School of Medicine, Denizli, Turkey
- ²² Department of Infectious Diseases and Clinical Microbiology, Health Sciences University, Haydarpasa Numune Training and Research Hospital, Istanbul, Turkey
- ²³ Department of Infectious Diseases and Clinical Microbiology, Firat University School of Medicine, Elazig, Turkey
- ²⁴ Department of Infectious and Tropical Diseases, University Hospital of Pointe-à-Pitre, Guadeloupe, France
- ²⁵ Department of Infectious Diseases and Clinical Microbiology, Sisli Hamidiye Etfal Training and Research Hospital, Istanbul, Turkey
- ²⁶ Department of Internal Medicine, Division of Gastroenterology, Mugla Sitki Kocman University Faculty of Medicine, Mugla, Turkey
- ²⁷ Department of Gastroenterology, Medical Park Hospital, Mersin, Turkey
- ²⁸ Department of Gastroenterology, Ankara University School of Medicine, Ankara, Turkey