



Acquired lung cysts in a premature neonate with congenital cytomegalovirus infection

Konjenital sitomegalovirüs enfeksiyonu olan prematüre bir yenidoğanda kazanılmış akciğer kistleri

Özmert M. A. Özdemir¹, Ceren Çıralı¹, Hacer Ergin¹, Ebru Nevin Çetin², Ateş Kara³

¹Division of Neonatology, Department of Pediatrics, Pamukkale University Faculty of Medicine, Denizli, Turkey

²Department of Ophthalmology, Pamukkale University Faculty of Medicine, Denizli, Turkey

³Division of Pediatric Infectious Diseases, Department of Pediatrics, Hacettepe University Faculty of Medicine, Ankara, Turkey

The known about this topic

Congenital cytomegalovirus infection is the most common intrauterine infection in neonates. There are rarely neonatal case reports of lung cysts in perinatally acquired congenital cytomegalovirus infection.

Contribution of the study

Based on the presented patient congenital congenital cytomegalovirus infection may be also caused lung cysts in neonates during the patients' clinical follow-up. The lung cysts may be shown by X-ray and these cystic changes may completely improve after appropriate therapy.

Abstract

We report a preterm newborn diagnosed as having congenital cytomegalovirus infection who developed lung cysts during her clinical follow-up. The lung cysts were shown in chest X-ray, and confirmed by thoracic computed tomography. A few weeks after starting ganciclovir therapy, we observed that the cystic lung changes of the patient were completely improved. No adverse effects of antiviral therapy were observed. Based on this presented patient, it should be kept in mind that congenital cytomegalovirus infection may cause lung cysts.

Keywords: Congenital, cytomegalovirus, lung cyst, newborn

Öz

Burada, doğuştan sitomegalovirüs enfeksiyonu tanısı konulan ve klinik izleminde akciğer kistleri gelişen erken doğmuş bir yenidoğanı sunulmuştur. Göğüs grafisinde saptanan akciğer kistleri bilgisayarlı tomografi ile doğrulandı. Gansiklovir tedavisinden birkaç hafta sonra, hastanın kistik akciğer değişikliklerinin tamamen düzeldiği görüldü. Antiviral tedaviye bağlı herhangi bir yan etki saptanmadı. Bu hasta sunumuyla, doğuştan sitomegalovirüs enfeksiyonunun akciğer kistlerine neden olabileceği akıld tutulmalıdır.

Anahtar sözcükler: Akciğer kisti, doğuştan, sitomegalovirüs, yenidoğan

Cite this article as: Özdemir ÖMA, Çıralı C, Ergin H, Çetin EN, Kara A. Acquired lung cysts in a premature neonate with congenital cytomegalovirus infection. Turk Pediatri Ars 2020; 55(3): 309–11.

Introduction

The most common intrauterine infection in neonates is caused by congenital cytomegalovirus (CMV), its prevalence ranges from 0.2% to 2.2%. Early clinical symptoms are not observed in nearly 90% of infants with congenital CMV infections, and their long-term outcomes are much better than those of infants with clinically apparent

infections. The most common long-term sequela of this infection is hearing loss (1). In the literature, there are rare case reports of lung cysts in perinatally acquired CMV infection (2, 3).

In this article, we reported a premature neonate diagnosed with congenital CMV infection related to acquired lung cysts.

Corresponding Author/Sorumlu Yazar: Özmert M.A. Özdemir E-mail/E-posta: drozmert@gmail.com

Received/Geliş Tarihi: 25.07.2018 **Accepted/Kabul Tarihi:** 06.12.2018

©Copyright 2020 by Turkish Pediatric Association - Available online at www.turkpediatriarsivi.com

©Telif Hakkı 2020 Türk Pediatri Kurumu Derneği - Makale metnine www.turkpediatriarsivi.com web adresinden ulaşılabilir.

DOI: 10.14744/TurkPediatriArs.2018.99907

OPEN ACCESS This work is licensed under a Creative Commons Attribution-NonCommercial 4.0 International License.



Case

A female neonate was born to a 22-year-old healthy primigravida woman at 35 gestational weeks by cesarean section due to fetal distress. Fetal echogenic bowel was determined in an antenatal ultrasound (US) examination at 18 weeks' gestation; however, fetal magnetic resonance-imaging (MRI) revealed no abnormalities. A maternal serologic examination was negative for rubella, *Toxoplasma gondii*, and cytomegalovirus (CMV) immunoglobulin (Ig)-M. Amniocentesis revealed normal fetal karyotype. Cranial ventriculomegaly was seen using re-performed antenatal US and fetal-MRI (atrial diameter of left ventricle 12.4 mm, right ventricle 13 mm) at 34 gestational weeks. She was admitted to our neonatal intensive care unit because of the ventriculomegaly and prematurity. Her weight was 1870 g (10th percentile), height 44 cm (10–50th percentile), and head circumference 32 cm (50–90th percentile). On physical examination, she appeared well, there was no abnormality except for hepatosplenomegaly (palpable 3 cm below costal-margin). Cranial US performed in the first hour after birth showed mild ventriculomegaly and grade I germinal matrix hemorrhage. Four hours later, widespread petechiae appeared over the entire body of the patient. The blood count [except for thrombocytopenia (19,000/mm³)] and other biochemical and hematologic parameters were within normal values.

The patient's CMV IgM was positive in the blood test. An ophthalmologic assessment revealed bilateral chorioretinitis. Cranial computed tomography (CT) showed ventriculomegaly with no calcifications. The patient failed auditory brainstem response testing. On postnatal day 7, CMV polymerase chain reaction (PCR) was positive in the patient's blood; therefore, she was diagnosed as having a symptomatic congenital CMV infection. The patient's mother's CMV PCR was negative in the blood. At this time, the patient had no respiratory distress symptoms and the initial chest X-ray was normal. Intravenous ganciclovir therapy (12 mg/kg/d, divided into two doses) was started. After two platelet transfusions, platelet counts returned to normal values on the 12th day postnatally.

An abdomen X-ray was performed because of the abdominal distension and feeding intolerance on postnatal day 20. Interestingly, we detected a regular-shaped cystic lesion in the left lower lung zone. This cystic lesion was also seen in a chest X-ray. Afterwards, a thoracic CT confirmed multiple cystic areas in the left lower lung lobe (Fig. 1 a, b). At that time, the patient had no respiratory distress symptoms, additionally, C-reactive protein (CRP) and blood cultures were negative. On the 35th day of ganciclovir therapy, no cystic lung lesions were

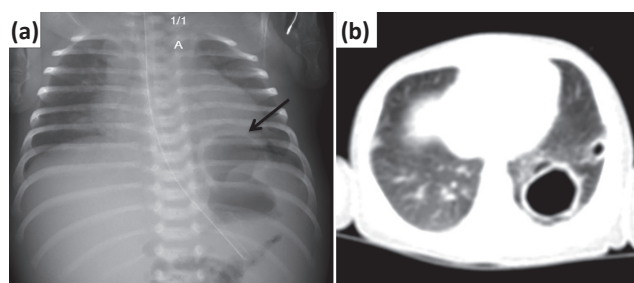


Figure 1. (a) Shows cystic like hyperlucent area on the left posterior-basal segment of the lung (arrow). (b) Thoracic computed tomography confirms cystic changes in the left lower lobe, the largest of them is located in the left lower lobe posterior basal segment

detected on follow-up chest X-ray. On postnatal day 55, she was discharged with oral valganciclovir therapy (32 mg/kg/d, divided into two doses). We did not observe any adverse effects of anti-viral therapy. At the 6th month of therapy, her weight, height, and head-circumference were in normal percentiles. On repeated ophthalmologic examination, macular scars were detected in both eyes; however, reactivation was not observed. Cranial MRI showed bilateral periventricular cysts. Cochlear implantation was planned because of severe sensorineural hearing loss. Informed consent was obtained from her parents.

Discussion

Neonatal lung disease linked to CMV infection can take a variety of forms (4). Pneumonitis may develop in 15–25% of CMV-infected neonates, particularly in premature neonates (5). Other lung involvements such as congenital lobar emphysema, Wilson-Mikity syndrome, and cystic lung disease are rarely reported in neonates with CMV infection (2–4, 6, 7). Herein, we present a premature neonate with congenital CMV infection who developed lung cysts.

The relationship between cystic lung disease and acquired CMV infection was first described by Bradshaw and Moore in 2003 (2). They reported a male premature neonate born at 30 weeks, who, after initial negative serology, acquired CMV infection postnatally and developed multiple lung cysts in the left upper lobe, left lingual lobe, and in the perihilar region on the right, on postnatal day 19. This infant, who had no antiviral therapy, showed gradual clinical improvement and significant resolution of the cystic changes (2). Kumar et al. (3) also reported a female premature infant born at 31 weeks who developed multiple cystic changes in the lower zone of left lung due to acquired CMV infection. Because this patient's CMV PCR was not performed in the postnatal first week,

the authors reported that it could not be definitely said whether CMV was acquired transplacentally or perinatally. The authors also reported that the patient was asymptomatic at birth and her first chest X-ray was normal. Afterwards, complete resolution of the cystic changes was shown by serial chest X-rays of the patient, who had no antiviral therapy (3). Our patient's fetal MRI, performed due to bowel hyperechogenicity on fetal US examination, and initial chest X-rays were normal. Cranial US and CT showed ventriculomegaly with no calcifications. On post-natal day 7, ganciclovir therapy was started because of the congenital CMV infection. Two weeks after beginning the therapy, a cystic lung lesion was incidentally determined in the basal part of left lobe on her chest X-ray. Thoracic CT confirmed the lung cysts. The patient had no signs of respiratory distress at this time, also CRP and blood cultures were negative. Fortunately, patient's lung cysts improved completely without any complications such as pneumothorax, and she was discharged with oral valganciclovir therapy.

Carrol et al. (6) presented a premature patient with congenital lobar emphysema diagnosed with antenatal and related to congenital CMV infection. We agree with Carrol et al.'s report that pulmonary CMV infection leading to inflammation in the bronchi and bronchial obstruction may have caused the development of the lung cysts, such as lobar emphysema.

In conclusion, based on the presented case and previous reports, it should be kept in mind that congenital or perinatal CMV infection may cause lung cysts or emphysematous changes.

Informed Consent: Written informed consent was given by the patient's parents.

Peer-review: Externally peer-reviewed.

Author Contributions: Concept - Ö.M.A.Ö., H.E.; Design - Ö.M.A.Ö., C.Ç.; Supervision - Ö.M.A.Ö., H.E.; Funding - Ö.M.A.Ö., C.Ç., E.N.Ç.; Materials - Ö.M.A.Ö., C.Ç., E.N.Ç.; Data Collection and/or Processing - Ö.M.A.Ö., C.Ç., E.N.Ç., A.K.; Analysis and/or Interpretation - Ö.M.A.Ö., C.Ç., H.E.; Literature Review - Ö.M.A.Ö., C.Ç.; Writing - Ö.M.A.Ö.; Critical Review - Ö.M.A.Ö., C.Ç., H.E., E.N.Ç., A.K.

Conflict of Interest: No conflict of interest was declared by the authors.

Financial Disclosure: The authors declared that this study has received no financial support.

Hasta Onamı: Yazılı hasta onamı hastanın ebeveynlerinden alınmıştır.

Hakem Değerlendirmesi: Dış bağımsız.

Yazar Katkıları: Fikir - Ö.M.A.Ö., H.E.; Tasarım - Ö.M.A.Ö., C.Ç.; Denetleme - Ö.M.A.Ö., H.E.; Kaynaklar - Ö.M.A.Ö., C.Ç., E.N.Ç.; Malzemeler - Ö.M.A.Ö., C.Ç., E.N.Ç.; Veri Toplanması ve/veya İşlenmesi - Ö.M.A.Ö., C.Ç., E.N.Ç., A.K.; Analiz ve/veya Yorum - Ö.M.A.Ö., C.Ç., H.E.; Literatür Taraması - Ö.M.A.Ö., C.Ç.; Yazıyı Yazan - Ö.M.A.Ö.; Eleştirel İnceleme - Ö.M.A.Ö., C.Ç., H.E., E.N.Ç., A.K.

Çıkar Çatışması: Yazarlar çıkar çatışması bildirmemişlerdir.

Mali Destek: Yazarlar bu çalışma için mali destek almadıklarını beyan etmişlerdir.

References

1. Britt W. Cytomegalovirus. In: Wilson CB, Remington JS, Nizet V, Klein JO, Maldonado YA, editors. Remington and Klein's infectious diseases of the fetus and newborn infant. Philadelphia: Elsevier Saunders; 2016.p.724–81.
2. Bradshaw JH, Moore PP. Perinatal cytomegalovirus infection associated with lung cysts. J Paediatr Child Health 2003; 39: 563–6.
3. Kumar M, Santhanam S. Acquired lung cyst in a newborn baby with cytomegalovirus infection. Indian Pediatrics 2015; 52: 996.
4. Staunton BH, Crabbe D, Cullinane C, Smith D. Congenital cytomegalovirus infection associated with development of neonatal emphysematous lung disease. BMJ Case Rep 2012; 2012: bcr0220125737.
5. Coclite E, Di Natale C, Nigro G. Congenital and perinatal cytomegalovirus lung infection. J Matern Fetal Neonatal Med 2013; 26: 1671–5.
6. Carrol ED, Campbell ME, Shaw BN, Pilling DW. Congenital lobar emphysema in congenital cytomegalovirus infection. Pediatr Radiol 1996; 26: 900–2.
7. Reiterer F, Dornbusch HJ, Urlesberger B, et al. Cytomegalovirus associated neonatal pneumonia and Wilson-Mikity syndrome: a causal relationship? Eur Respir J 1999; 13: 460–2.