

A Huge Aneurysm of Popliteal Arteriovenous Fistula Occured Secondary to Trauma: Case Report

Travmatik Dev Popliteal Arteriyovenöz Fistül

İhsan ALUR,^a
Yusuf İzzettin ALİHANOĞLU,^b
Ali Baran BUDAK,^c
Bekir Serhat YILDIZ,^d
Bülent ÇÜMEN^a

Clinics of

^aCardiovascular Surgery,

^cCardiology,

Denizli State Hospital,

^bDepartment of Cardiology,

Pamukkale University Faculty of Medicine,
Denizli

^dClinic of Cardiovascular Surgery,

Ankara Numune Hospital, Ankara

Geliş Tarihi/Received: 03.12.2012

Kabul Tarihi/Accepted: 28.12.2012

Yazışma Adresi/Correspondence:

İhsan ALUR

Denizli State Hospital,

Clinic of Cardiovascular Surgery, Denizli,

TÜRKİYE/TURKEY

alur_i@hotmail.com

ABSTRACT Although the relatively high frequency of popliteal injuries following war and civilian traumas, a late development of an arteriovenous fistula can be considered as a rare complication. A huge left popliteal arteriovenous fistula causing the aneurysm of the iliac artery, iliac vein and also the abdominal aorta was diagnosed in a 72-year-old male patient applying with leg pain that had progressively increased during the last year. We would like to present this aneurysm of popliteal arteriovenous fistula occurred secondarily to the gunshot wound 38 years ago.

Key Words: Popliteal injury; popliteal aneurysm; fistula; trauma

ÖZET Savaş ve sivil travmalardan sonra popliteal yaralanmalar nispeten sık olmasına rağmen, arteriyovenöz fistül gelişmesi nadir bir komplikasyon olarak kabul edilebilir. Son bir yılda giderek artan bacak ağrısıyla başvuran 72 yaşında erkek hastada dev sol popliteal arteriyovenöz fistüle bağlı dev anevrizma, eşzamanlı iliak arter, ven ve abdominal aort anevrizması tespit edildi. Otuz sekiz yıl önce ateşli silah yaralanmasına bağlı popliteal arteriyovenöz fistüle bağlı dev anevrizmayı sunmak istedik.

Anahtar Kelimeler: Popliteal yaralanma; popliteal anevrizma; fistül; travma

Damar Cer Derg 2013;22(1):93-6

Arteriovenous fistula is an abnormal communication between an artery and a vein. It may be congenital, which usually affects smaller vessels, or acquired as a result of trauma with a bullet or stab wound, or occur after the erosion of an arterial aneurysm into an adjacent vein. It may cause symptoms and signs of arterial insufficiency such as ulceration due to reduced arterial flow or ischemia and chronic venous insufficiency due to high-pressure arterial flow in the affected veins such as peripheral edema, varicose veins and stasis pigmentation. Emboli causing ulceration may pass from the venous to the arterial circulation, although pressure differences make this unusual.¹ A mass can be felt if the fistula is near the surface. The affected area is usually swollen and warm with distended and pulsating superficial veins. A thrill can be palpated over the fistula, and murmur can be heard during auscultation. High-output heart failure may rarely develop if a significant portion of cardiac output is diverted through the fistula to the right heart.²

doi: 10.9739/uvcd.2012-32965

Copyright © 2013 by
Ulusal Vasküler Cerrahi Derneği

CASE REPORT

A 72-year-old male patient has been complaining of swelling and pain of the left leg after exposing to the gunshot wound 38 years ago. Cardio-respiratory examination revealed a grade 3/6 ejection systolic murmur loudest at the left sternal edge which did not vary with posture and there was no radiation. His gastrointestinal system examination was normal. His peripheric pulsations were palpable. Extensive edema of the left lower extremity and trophic skin lesions were determined on

the physical examination. There was no thromboembolic event and his respiratory function test was in normal limits. On echocardiographic evaluation, only moderate tricuspid regurgitation was detected. First, left popliteal arteriovenous fistula was detected by Doppler ultrasonography. Then, a huge left popliteal arteriovenous fistula causing aneurysmatic dilatation of the iliac artery, iliac vein and also the abdominal aorta was diagnosed with computed tomography angiography (Figures 1 to 5). The patient was informed about the surgical or endovascular treatment alternatives, howe-

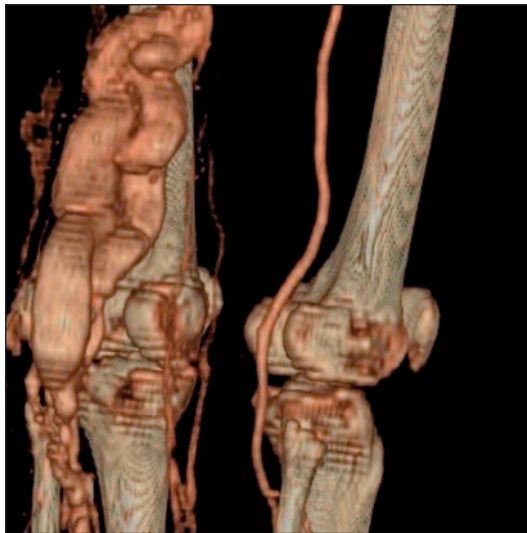


FIGURE 1: Left popliteal arteriovenous fistula (posterior view).

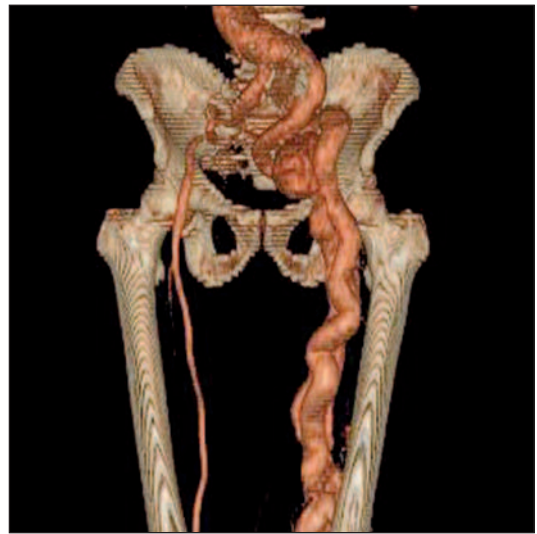

FIGURE 2: Aneurysm of the abdominal aorta, iliofemoral artery and vein (anterior view).

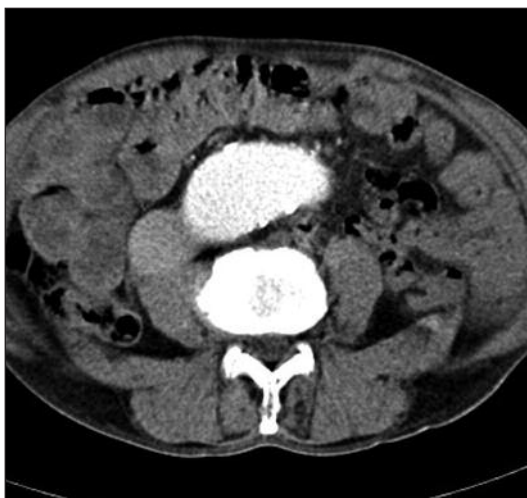

FIGURE 3: The Abdominal Aorta Aneurysm (Transverse section).

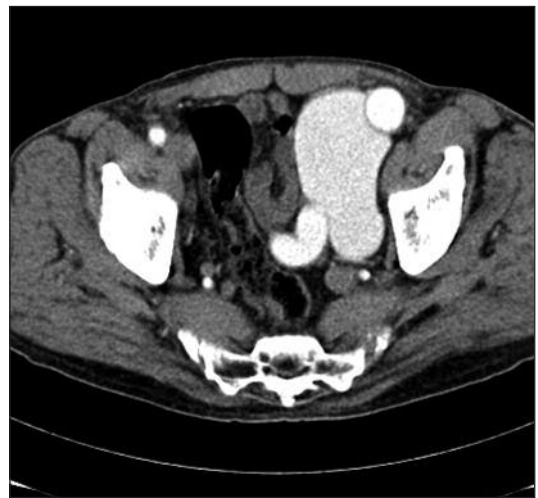


FIGURE 4: The iliofemoral artery and vein aneurysm (Transverse section).

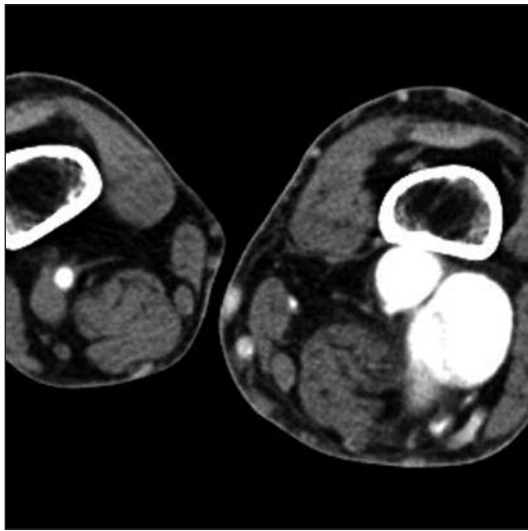


FIGURE 5: Left popliteal A-V fistula (Lower transverse section.)

ver he was not persuaded for any of these invasive procedures. Optimal medical treatment including silostazol, asetilsalisilic acid, warfarin and furosemide was administered to the patient.

DISCUSSION

Peripheral arterial aneurysms are abnormal dilations of peripheral arteries caused by weakening of the arterial wall. While about 70% of peripheral arterial aneurysms are popliteal aneurysms, 20% are iliofemoral aneurysms. Aneurysms at these segments usually accompany abdominal aortic aneurysms, and >50% are bilateral. Rupture is relatively rare, but these aneurysms may cause thromboembolism. They occur in men much more often than women (>20:1); mean age at presentation is 65 years. Aneurysms in arm arteries are relatively infrequent, they may cause limb ischemia, distal embolism and stroke. Peripheral arterial aneurysms are usually asymptomatic at the time of diagnosis. Thrombosis or embolism and rarely aneurysm rupture cause extremities to be painful, cold, pale, paresthetic, or pulseless. In addition, infectious aneurysms may cause local pain, fever, malaise and weight loss.³

Primary venous aneurysms are not as common as arterial aneurysms. Venous aneurysms have been generally detected in the popliteal, jugular and

saphenous veins, however they are rarely observed in other veins such as the visceral veins.⁴

The etiology of popliteal venous aneurysm (PVA) is not clearly known, however congenital factors, inflammation, trauma and degenerative changes are thought to be the main causes responsible.⁵ PVA is occasionally characterized by local signs and symptoms, and it is usually non-palpable on physical examination. PVA is commonly recognised with chronic venous insufficiency symptoms (76%) such as leg swelling or skin lesions. However, it notably may cause fatal complications such as pulmonary embolism and other thromboembolic episodes (24%), if it remains undiagnosed or untreated.⁶ The definitive diagnosis can be made by imaging tests such as ultrasonography, magnetic resonance angiography, or computed tomography angiography. Baker's cyst and tibio-fibular cyst should be considered in the differential diagnosis of PVA.⁷

A retrospective analysis of the 25 patients identified that 24% of the cases had pulmonary embolism, and 76% of PVAs were found during an investigation for chronic venous disease. Through the widespread use of venous duplex scanning, PVAs are increasingly found in patients with deep or superficial vein insufficiency.⁸

Untreated huge arteriovenous fistulae may also cause to ischemic steal syndrome. Ischemic steal syndrome associated with an arteriovenous fistula is rare but can result in severe complication like extremity ischemia. It is manifested by pain, weakness, pallor, and in severe cases, ulceration and tissue loss. Pathophysiology may be explained as inadequate arterial collateral inflow due to occlusive disease or high flow in a fistula exceeding the inflow capacity in the absence of intrinsic occlusive disease. Operative intervention for ischemic steal syndrome successfully resolves ischemia in 80% to 95% of the patients.⁹

Rupture risk of extremity aneurysms is low (<5% for popliteal and 1 to 14% for iliofemoral aneurysms). Surgical repair is therefore often elective for leg artery aneurysms. It is indicated when the

arteries are twice normal size or when the patient is symptomatic. However, surgical repair is indicated for all arm artery aneurysms because serious complications like thromboembolism are a greater risk. Tangential aneurysmectomy, lateral venorrhaphy, resection with side by side anastomosis, resection with graft interposition, and ligation of the vein from both proximal and distal segment are the main surgical techniques. Limb salvage rate after surgical repair is 90 to 98% for asymptomatic patients and 70 to 80% for symptomatic patients. In certain patients, an endovascular-covered stent-graft is another option for repair.³

We thought in our patient that this popliteal arteriovenous aneurysm as well as iliofemoral arteriovenous dilatation depending on retrograde excessive blood flow developed secondarily to the untreated left popliteal arteriovenous fistula which occurred after exposing to the gunshot wound 38 years ago. Additionally, abdominal aort aneurysm may be resulted from the progression of the iliofe-

moral arteriovenous dilatation or degenerative process related to aging.

CONCLUSION

Early diagnosis and treatment of popliteal arteriovenous aneurysm is important for preventing the serious complications such as thromboembolic event, extremity ischemia or rupture of the aneurysm. Due to the fact that we detected critical leg ischemia resulting from a huge aneurysm of popliteal arteriovenous fistula, surgical or endovascular interventional treatment strategies were planned to be performed, however our patient was not persuaded for any of these invasive procedures. Eventually, we had to administer optimal medical treatment to the patient, which comprised silostazol, asetilsalisilic acid, warfarin and furosemide.

Conflict of Interest

Authors declared no conflict of interest or financial support.

REFERENCES

1. http://www.merckmanuals.com/professional/cardiovascular_disorders/peripheral_venous_disorders/arteriovenous_fistula.html. Accessed December 1, 2012.
2. http://www.merckmanuals.com/professional/cardiovascular_disorders/heart_failure/heart_failure_hf.html. Accessed December 1, 2012.
3. http://www.merckmanuals.com/professional/cardiovascular_disorders/peripheral_arterial_disorders/peripheral_arterial_aneurysms.html. Accessed December 1, 2012.
4. Sfyroeras GS, Antoniou GA, Drakou AA, Karathanos C, Giannoukas AD. Visceral venous aneurysms: clinical presentation, natural history and their management: a systematic review. *Eur J Vasc Endovasc Surg*. 2009; Oct, 38(4):498- 505.
5. Friedman SG, Krishnasastry KV, Doscher W, Deckoff SL. Primary venous aneurysms. *Surgery* 1990;108(1):92-5.
6. Sessa C, Nicolini P, Perrin M, Farah I, Magne JL, Guidicelli H. Management of symptomatic and asymptomatic popliteal venous aneurysms: a retrospective analysis of 25 patients and review of the literature. *J Vasc Surg* 2000;32(5):902-12.
7. Bergqvist D, Björck M, Ljungman C. Popliteal venous aneurysm--a systematic review. *World J Surg* 2006;30(3):273-9.
8. Sessa C, Nicolini P, Perrin M, Farah I, Magne JL, Guidicelli H. Management of symptomatic and asymptomatic popliteal venous aneurysms: a retrospective analysis of 25 patients and review of the literature. *J Vasc Surg* 2000; 32(5):902-12.
9. Suding PN, Wilson SE. Strategies for management of ischemic steal syndrome. *Semin Vasc Surg* 2007;20(3):184-8.