

## Infected mullerian adenocarcinoma: Report of a case and review of the literature

*Enfekte müllerian adenokarkoma: Olgu sunumu ve literatürün gözden geçirilmesi*

*Banuhan Şahin\*, Aysun Karabulut\*, Nevzat Karabulut\*\*, Mehmet Gündoğan\*\*\*, Metin Akbulut\*\*\**

*\*Pamukkale Üniversitesi Tıp Fakültesi, Kadın Hastalıkları ve Doğum AD, Denizli*

*\*\*Pamukkale Üniversitesi Tıp Fakültesi, Radyoloji AD, Denizli*

*\*\*\*Pamukkale Üniversitesi Tıp Fakültesi, Patoloji AD, Denizli*

### Özet

Müllerian adenokarkom daha çok postmenapozal dönemdeki kadınları etkileyen nadir bir tümördür. Patolojik olarak düşük gradeli endometrial stromal sarkom ve çoğunlukla benign, ama bazen de atipik glandüler epitelden oluşur. Hastalar çoğunlukla karın ağrısı, huzursuzluk ve uterus kanama şikayetiyle başvururlar. Bu yazıda abse formasyonu ile komplike olan ve postoperatif dönemde sepsis gelişen bir Müllerian adenokarkom olgusunu sunmayı amaçladık. Müllerian adenokarkomlar rölâtif olarak iyi prognoza sahip nadir görülen tümörler olmakla birlikte klinik tablo nekroza sekonder gelişen enfeksiyon, abse gelişimi ve postoperatif sepsisle komplike olabilmektedir.

*Pam Tıp Derg 2015;8(1): 79-81*

**Anahtar sözcükler:** Müllerian adenokarkoma, abse, sepsis.

### Abstract

Müllerian adenocarcinoma is a rare tumor usually affecting postmenopausal women. Patients generally present with abdominal pain, discomfort and uterine bleeding. A mixture of low grade endometrial stromal sarcoma, and benign but sometimes atypical glandular epithelium is detected in the histopathologic examination. Herein, we present an unusual case of Müllerian adenocarcinoma complicated with abscess formation leading to sepsis postoperatively. Müllerian adenocarcinomas are uncommon tumors with relatively good prognosis, however necrosis and secondary infection may lead to abscess formation and complicate the clinical picture with postoperative sepsis.

*Pam Med J 2015;8(1):79-81*

**Key words:** Müllerian adenocarcinoma, abscess, sepsis.

### Introduction

Müllerian adenocarcinoma is a rare tumor usually affecting postmenopausal women [1,2]. It shows a mixture of low grade endometrial stromal sarcoma, and benign but sometimes atypical glandular epithelium. Patients generally present with abdominal pain, discomfort and uterine bleeding. Herein, we present an unusual case of Müllerian adenocarcinoma complicated with abscess formation leading to sepsis postoperatively.

### Case report

A 66-year-old female presented with postmenopausal bleeding of two to three pads and a foul smelling vaginal discharge for 2-3 weeks. Sonographic examination showed an enlarged uterus with two myomas around 1-2 cm, and a large intracavitary polypoid mass. Pelvic magnetic resonance examination demonstrated a 5x6 cm contrast enhancing polypoid mass filling the endometrial cavity, and an accompanying subendometrial hemorrhage (Fig 1). Histopathologic examination of endometrial curettage material showed endometrial polyp. Intraoperatively, the uterus

Banuhan Şahin

Yazışma Adresi: Pamukkale Üniversitesi Tıp Fakültesi, Kadın Hastalıkları ve Doğum AD, Denizli

e-mail: banuhansahin@gmail.com

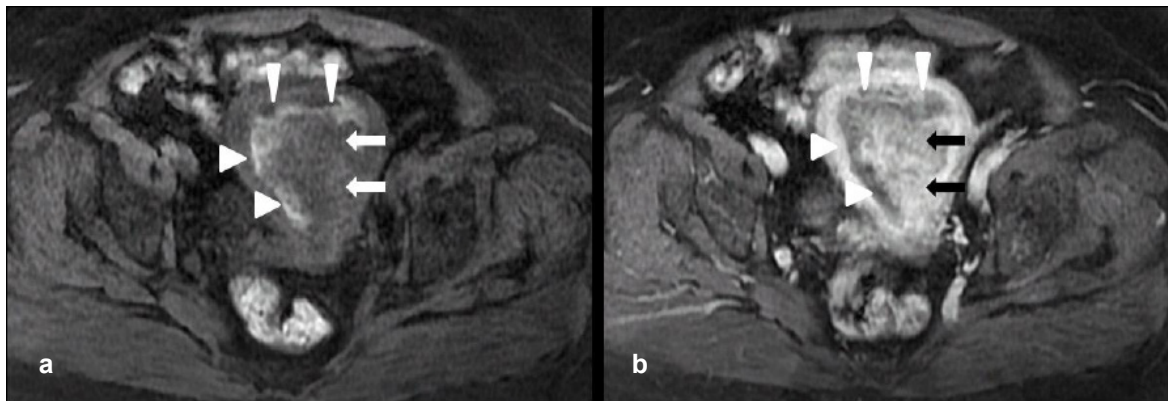
Gönderilme tarihi: 22.05.2014

Kabul tarihi: 08.12.2014

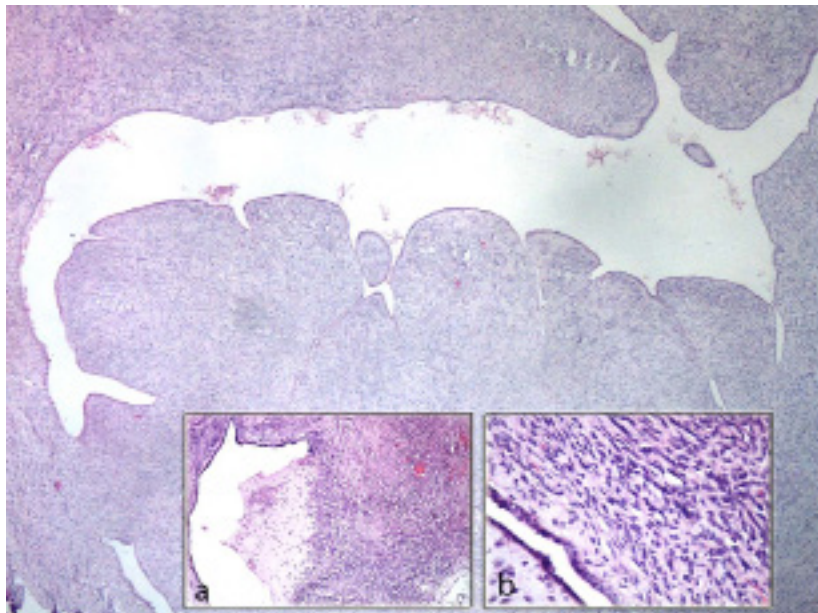
was enlarged around 18-20 weeks of gestation, and filled with purulent material during the operation. Total abdominal hysterectomy and bilateral salphyngooforectomy was performed along with peritoneal washing. In the postoperative period, the patient had a fever of 39°C, WBC increased to 16800/mm<sup>3</sup> with neutrophil predominance, CRP was 17 mg/dl, and sedimentation rate was 39 mm/hour. Intensive parenteral antibiotic therapy was administered for both anaerobes and gram-negative bacteria for 10 days. Laboratory values

progressively turned to normal and the patient was discharged on the 11<sup>th</sup> day postoperatively.

Histopathologic examination showed a 6x5x5cm mass filling the endometrial cavity with areas of necrosis and hemorrhage. Hyperplastic glandular endometrial cells were detected between sarcomatous cell clusters leading to a diagnosis of Müllerian adenosarcoma (Fig 2). The tumoral mass was limited to the endometrium without evidence of myometrial invasion and lymphovascular involvement.



**Figure 1.** T1 weighted MR images before (A) and after contrast administration (B) demonstrate enhancing polypoid mass in the endometrial cavity (arrows) with accompanying subendometrial blood (arrowheads).



**Figure 2.** Müllerian adenosarcoma: sarcomatous areas formed by spindle shaped cells in form of crevasse in some places and hyperplastic endometrial glandular structures. (H&E, x4; a, x10; b, x40).

## Discussion

Mullerian adenosarcoma is a slowly progressive low grade neoplasm with benign epithelial and malignant sarcomatous components [1,3]. The malignant component is low grade endometrial stromal sarcoma in almost all the cases [3]. The usual clinical presentation is abdominal pain, discomfort and uterine bleeding [3]. Similarly, our patient also presented with postmenopausal bleeding, but she also had a malodorous seroanginous vaginal discharge originating from the abscess within the endometrial cavity. Endometrial sampling is important for the diagnosis, however, in our case histopathologic examination of the endometrial curettage material revealed an endometrial polyp.

Magnetic resonance imaging (MRI) is a useful modality providing information on soft tissue intensity. However, MRI features of adenosarcoma have been described in only a few cases. Usually it manifests as a heterogeneous mass encompassing solid and cystic components filling the endometrial cavity of an enlarged uterus. The mass enhances similar to the myometrium [4]. In our case, the mass was predominantly solid and exhibited slightly lesser enhancement compared to the myometrium. There was also accompanying subendometrial blood. Bilateral salpingooferectomy besides hysterectomy has traditionally been recommended in the treatment of adenosarcoma. Recurrences are rare in the absence of sarcomatous overgrowth and myometrial invasion [5,6].

In conclusion, Mullerian adenosarcomas are uncommon tumors with relatively good prognosis. Because of intracavitary growth, they usually generate symptoms and are diagnosed at the early stages. Necrosis and secondary infection may lead to abscess formation complicating the clinical picture. Mullerian adenosarcomas must be kept in mind in cases with endometrial masses filling the enlarged uterus and presenting with postmenopausal bleeding, and they may also be associated with postoperative sepsis.

**Conflict of interest:** The authors declared no conflict of interest.

## References

1. Clement PB, Scully RE. Müllerian adenosarcoma of the uterus. A clinicopathologic analysis of ten cases of a distinctive type of müllerian mixed tumor. *Cancer* 1974;34:1138–1149.
2. Clement PB, Scully RE. Uterine tumors with mixed epithelial mesenchymal elements. *Semin Diagn Pathol* 1988;5:199–222.
3. Gallardo A, Prat J. Mullerian Adenosarcoma; A clinicopathologic and immunohistochemical study of 55 cases challenging the existence of adenofibroma. *Am J Surg Pathol* 2009;33:278–288
4. Yoshizako T, Wada A, Kitagaki H, Ishikawa N, Miyazaki K. MR imaging of uterine adenosarcoma: case report and literature review. *Magn Reson Med Sci* 2011;10:251–254.
5. Nam JH. Surgical treatment of uterine sarcoma. *Best Pract Res Clin Obstet Gynaecol* 2011; 25:751–760.
6. McCluggage WG. Mullerian adenosarcoma of the female genital tract. *Adv Anat Pathol* 2010;17:122–129.