

Surgical repair with palatal mucosal graft in subglottic stenosis caused by Wegener's granulomatosis

Wegener granülomatozisine bağlı subglottik darlıkta damak mukoza grefti ile cerrahi onarım

Ümit Aydoğmuş, Figen Türk, Gökhan Yuncu

Department of Thoracic Surgery, Medical Faculty of Pamukkale University, Denizli, Turkey

ABSTRACT

A 56-year-old female patient had Wegener's granulomatosis with lung involvement. Patient was being treated with steroids and was directed to our clinic for gradually increasing shortness of breath. The radiological examination showed a 2 cm stenosis in the subglottic area. We decided to operate on the patient according to the bronchoscopic findings which showed dense granulation tissue in the subglottic area which could only be dilated partially. The 15 mm narrow trachea segment under the cricoid level was resected. A palate mucosal graft was applied to the subglottic area. A Montgomery T-tube was inserted with its proximal end reaching the vocal cords from the distal trachea. The ends of trachea were joined through anastomosis. There were no postoperative complications. The T-tube was removed on the sixth postoperative month and the patient is currently in the 12th month of follow-up (after removal of T-tube) without any stenosis. The treatment of Wegener's granulomatosis patients with subglottic stenosis who do not respond to steroid therapy is controversial. We believe that surgical treatment can be successful in appropriate patients.

Keywords: Palatal mucosal graft; subglottic stenosis; Wegener's granulomatosis.

Wegener's granulomatosis (WG) is a multisystem vasculitis that involves small and medium-sized vessels and may appear in systemic or limited forms. Respiratory system findings can range from an asymptomatic nodule to fulminant alveolar hemorrhage,^[1] and upper respiratory tract involvement is often destructive, which distinguishes WG from other vasculitides.

ÖZ

Elli altı yaşında kadın hastada akciğer tutulumu ile Wegener granülomatozisi var idi. Steroidler ile tedavi edilen hasta artan solunum sıkıntısı nedeni ile kliniğimize yönlendirildi. Radyolojik incelemede subglottik alanda 2 cm'lik bir darlık olduğu görüldü. Subglottik alanda kısmen dilate edilebilen yoğun granülasyon dokusu gösteren bronkoskopik bulgulara göre hastanın ameliyat edilmesine karar verildi. Krikoid düzey altındaki 15 mm'lik dar trakea segmenti rezeke edildi. Subglottik alana bir damak mukoza grefti uygulandı. Proksimal ucu distal trakeadan ses tellerine uzanacak şekilde bir Montgomery T tüp yerleştirildi. Trakeanın uçları anastomoz ile birleştirildi. Ameliyat sonrası komplikasyon yoktu. T tüp ameliyat sonrası altıncı ayda çıkarıldı ve hasta şu anda herhangi bir darlık olmaksızın takibin 12. ayındadır (T tüpün çıkarılmasını takiben). Steroid terapisine yanıt vermeyen subglottik darlığı olan Wegener granülomatozisi hastalarının tedavisi tartışmalıdır. Uygun hastalarda cerrahi tedavinin başarılı olabileceğini düşünüyoruz.

Anahtar sözcükler: Damak mukoza grefti; subglottik darlık; Wegener granülomatozisi.

The extent of subglottic stenosis (SGS) and its response to medical treatment appear to be important when deciding on the best treatment for WG. Endoscopic methods (e.g., laser, dilatation, balloon, etc.) may be successful in some patients, but surgical procedures are sometimes preferable because of the need for frequent and lifelong repetition of the endoscopic procedures and possible stent malpositioning. In addition, applying



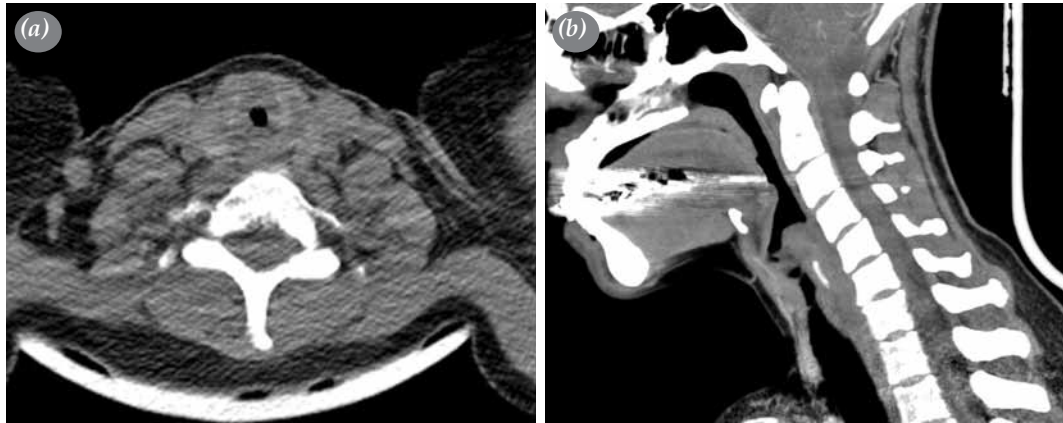

Figure 1. Cervical computed tomographic view showing (a) the transverse plane and (b) the sagittal plane.

these treatments can be particularly difficult when the granulation tissue is very close to the vocal cords in the subglottic area.^[2-4] Herein, we present a case involving the use of a palatal mucosal graft to treat SGS in a WG patient.

CASE REPORT

A 56-year-old female patient had been followed up for 10 years due to sinusitis and a saddle nose deformity that had developed seven years earlier. She had been complaining of shortness of breath and weakness for 18 months, and a physical examination had revealed a rhonchus that was more prominent on the left side together with a bilateral stridor. The forced expiratory volume in one second (FEV1) was 1,390 mL (59%) on her pulmonary function test, and thoracic computed tomography (CT) showed a

nodular lesion measuring approximately 25x23 mm with spiculated extensions on the anterior aspect and inferior lingular segment periphery in the upper lobe of the left lung. There was also another nodular lesion measuring 12x5 mm in the lower lobe posterior segment of the right lung and subsegmental atelectasis in the lingula inferior and middle lobe. However, no active infiltration or consolidation was seen in the lung parenchyma. In addition, a thickening with regular contours of up to 7.5 mm at its thickest part was seen in the subglottic area, and this was causing concentric stenosis in the lumen (Figure 1). Furthermore, her radiological findings revealed a 77.5% reduction in the cross-sectional area of the subglottis (Myer-Cotton grade III).

The patient’s blood tests revealed a C-reactive protein (CRP) level of 0.17 mg/dL, an erythrocyte

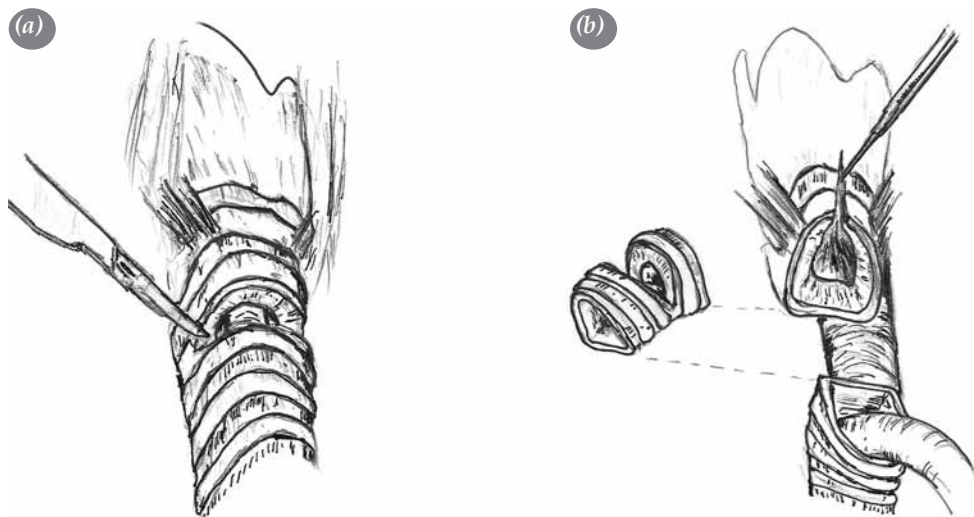


Figure 2. A resection of the narrowing tracheal segment shows (a) the tracheal incision while (b) shows the removal of the narrowing segment of trachea up to the intact tracheal segment.

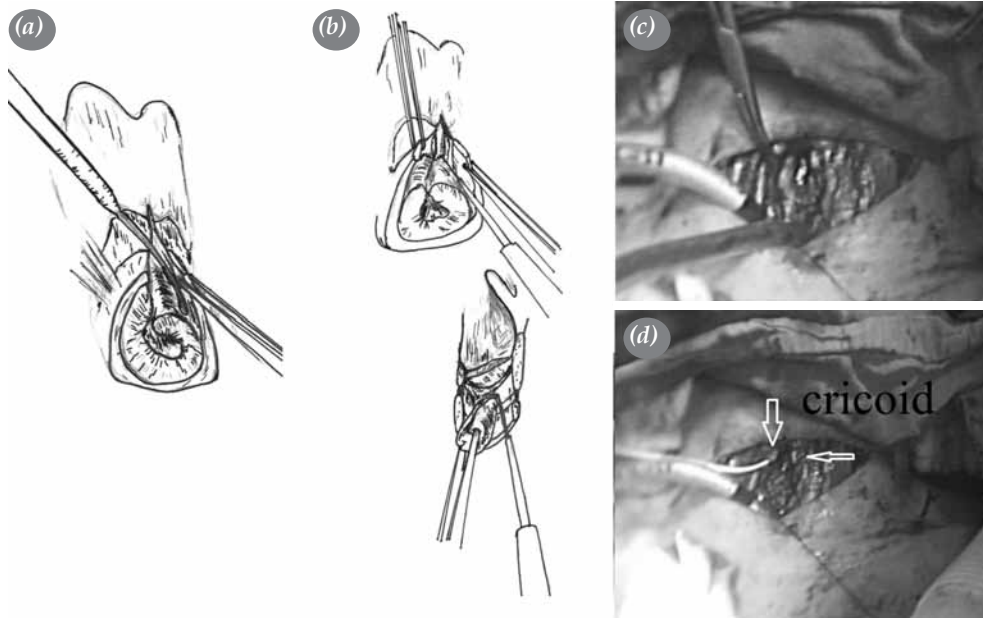


Figure 3. Preparation of the cricoid showing (a) the vertical incision from the anterior of the cricoid to the thyroid cartilage, (b) the removal of granulation tissue on the cricoid cartilage, (c) the dissection of the granulation tissue on the cricoid, and (d) the prepared cricoid cartilage.

sedimentation rate (ESR) of 38 mm/L per hour, and a leukocyte count of 8,760/mm³. Moreover, she tested positive for the antinuclear antibody (ANA) but negative for the cytoplasmic antineutrophil antibody (c-ANCA). The patient also tested negative for c-ANCA two more times during her treatment.

Rheumatologists treated the patient twice with pulse steroids (30 mg/kg/dose/i.v. for three days), but she was then referred to our clinic when there was no response. Her radiological examination showed stenosis extending along a 2 cm segment in the subglottic area and partial stenosis in the left main

bronchus. Therefore, we decided that the patient should undergo dilatation. We then informed her about the various treatment options and possible complications and obtained her written informed consent to have the procedure.

The dilatation was performed via a rigid bronchoscopy under general anesthesia. Only partial dilatation could be achieved because the area of tracheal stenosis had hardened significantly, but the bronchial stenosis in the left main bronchus could be dilated since it consisted of soft, reticulated granulation tissue. Additionally, the dense granulation tissue in the

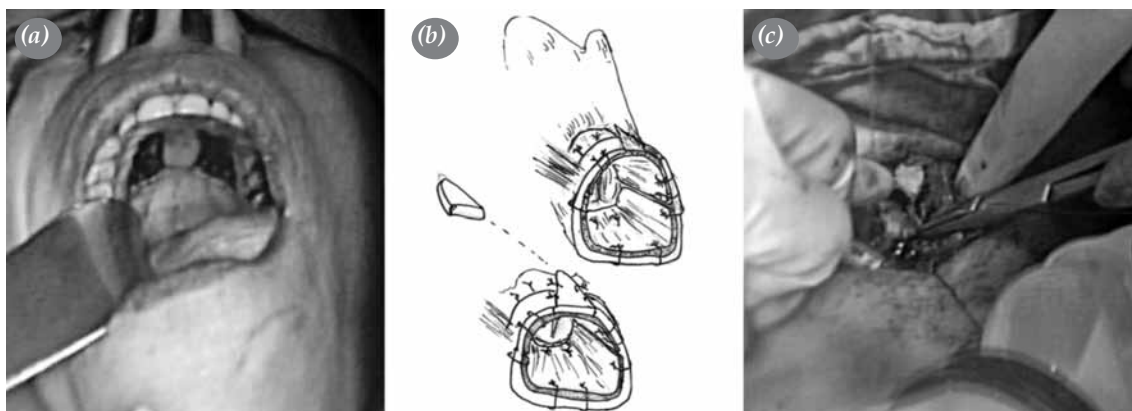


Figure 4. (a) Photographs showing the taking of the palatal graft and (b, c) the fixing of the circumferential palatal and triangular costal cartilage grafts to the cricoid ring.

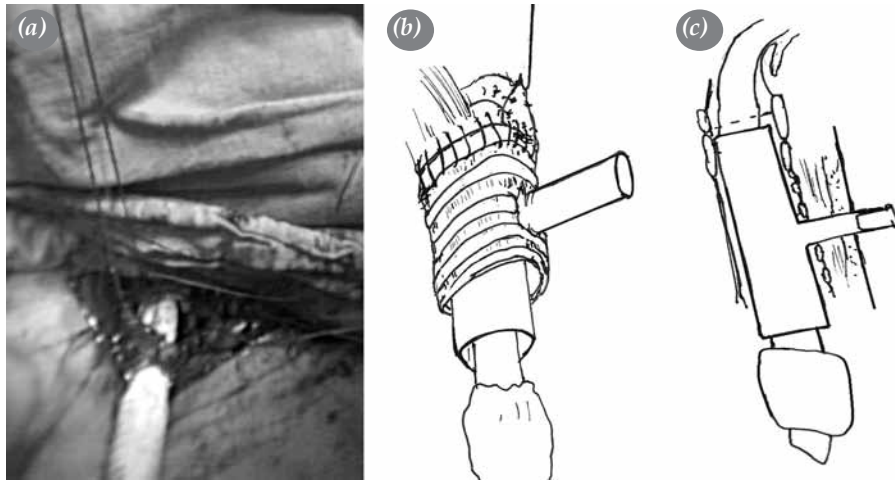


Figure 5. (a) A photograph shows the placement of the T-tube, (b) and drawings display the end-to-end anastomosis between the cricoid and intact tracheal segment and (c) the upper end of the T-tube just below the vocal cords.

subglottic area could only be dilated partially, so we decided that surgical treatment was needed. The patient was intubated with a no. 6 cuffed endotracheal tube in the same session, and then we began the operation.

First, the narrow tracheal segment was removed (Figure 2), and an incision was made from the anterior surface of the cricoid to the thyroid cartilage. Then the granulation tissue in the cricoid was dissected using a thin periosteal elevator (Figure 3). However, the anterior cricoid arch was not resected, and the posterior cricoid lamina and all of its joints were fully protected. Next, we removed the palatal mucosa graft and used it to circumferentially cover the inner surface of the cricoid (Figure 4). Then the cricoid ring was expanded by placing a triangular costal cartilage graft on the

incised anterior cricoid area (Figure 4), and traction sutures were used on the lateral wall of the larynx and trachea. Afterwards, a Montgomery® Safe-T-Tube™ standard no. 13 (Boston Medical Products, Inc. MA, USA) was inserted after the posterior surface of the larynx, and the trachea was sutured with a single row of 4/0 continuous vertical mattress sutures made of a glycolide and caprolactone polymer. The same sutures were used in the anterior aspect as well. The patient's neck was then flexed, and the traction sutures were tied followed by the anastomotic sutures. The end-to-end anastomosis was then completed (Figure 5). The location of the T-tube was checked via a bronchoscopy during surgery and with lateral graphs postoperatively (Figure 6).

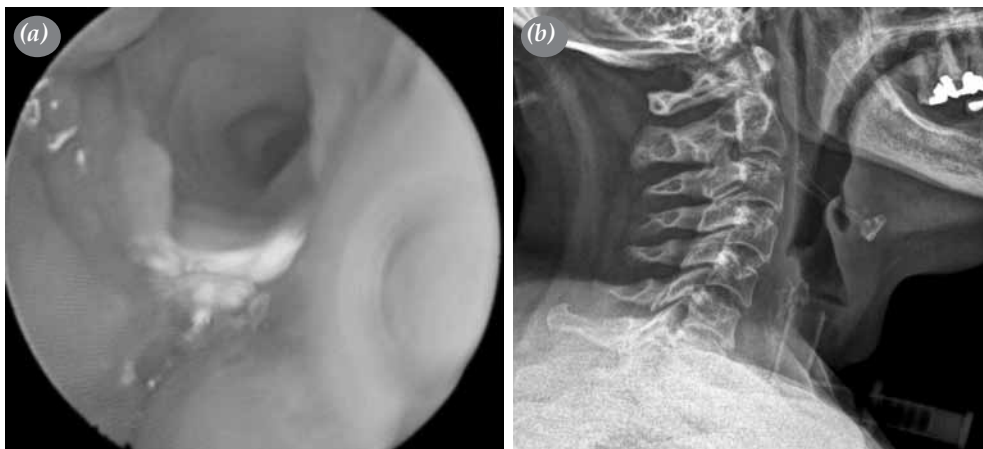


Figure 6. (a) Endoscopic view showing the checking of the T-tube in the perioperative period and (b) a radiological view showing the T-tube in the postoperative period.

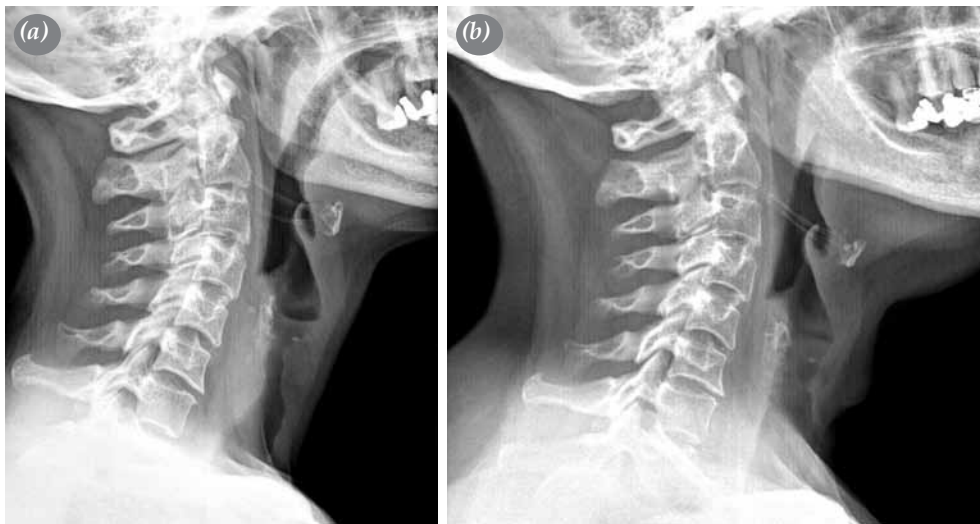


Figure 7. (a) A preoperative lateral cervical radiographic view of the area of subglottic stenosis and (b) a postoperative lateral cervical radiographic view of the patent subglottic area 12 months after the removal of the T-tube.

There were no postoperative complications, and the T-tube was removed in the sixth postoperative month. The patient is currently in the 12th month of follow-up after the removal of the T-tube and has no stenosis (Figure 7).

DISCUSSION

Subglottic stenosis occurs in just 1-6% of WG patients,^[1] and upper airway involvement has been reported in 7-23%.^[1,2] A number of treatments have been tried on WG patients with SGS, and approximately 20% have responded favorably to medical treatment. Gouveris et al.^[4] found that the administration of endoscopic dilatation and local mitomycin C had to be repeated between two and seven times to remain effective. Furthermore, because of the frequency of late restenosis, long-term monitoring is recommended for those who undergo endoscopic treatment. Moreover, the repeated procedures may also cause new tracheal damage, making surgical intervention difficult or even impossible.^[3] Permanent tracheostomies have been used in elderly patients with WG,^[1] but nonsurgical treatments usually provide the best option for palliation when SGS is involved.^[2,3] The greatest advantage of a correctly chosen surgical treatment is that it renders a positive, long-lasting result.^[3] In fact, because of the relapses in patients who receive endoscopic treatment, surgical treatment has been recommended for the patients who have WG with SGS.^[3]

Montgomery^[5] described a technique which employed open scar excision via a mucosal advancement flap for

glottic stenosis in which the healthy mucosa served as an important component in the scarless healing of the trachea. Moreover, Grillo et al.^[6] utilized a broad-based flap of membranous trachea for this same purpose. Our modified technique featuring a palatal mucosal flap has three advantages. First, there is no need to remove the extra intact tracheal cartilage. Secondly, the palatal mucosa, which is thicker than the buccal mucosa, provides better support in the early days of anastomosis. It also is histologically identical to the keratinized attached mucosa of the alveolar ridge, and it provides a comfortable tissue base with regard to the resilience and quantity of the epithelium. Moreover, the donor area recovers spontaneously, rapidly, and independently of the tracheal healing. The third advantage is that the integrity of the palatal mucosa graft is better protected during removal and insertion.

Recurrent laryngeal nerve palsy is an intrinsic complication of trachea surgery, but the use of intraoperative neuromonitoring allows for the preservation of the anatomical structure and the functional integrity of the nerve. In addition, the lesions, which are not visible, can also be detected via this type of monitoring. However, neuromonitoring was not needed for our patient because we utilized the method described by Grillo et al.^[6] in which the dissection of the lateral margins of the trachea is performed by hugging the trachea to avoid the recurrent laryngeal nerves.

In conclusion, diagnosis and treatment of WG may be delayed when it occurs in the local form. While

controversial still surrounds the best treatment options for WG patients with SGS who do not respond to steroid therapy, we believe that surgical treatment could prove to be the best choice for those patients who are eligible.

Declaration of conflicting interests

The authors declared no conflicts of interest with respect to the authorship and/or publication of this article.

Funding

The authors received no financial support for the research and/or authorship of this article.

REFERENCES

1. Morales-Angulo C, García-Zornoza R, Obeso-Agüera S, Calvo-Alén J, González-Gay MA. Ear, nose and throat manifestations of Wegener's granulomatosis (granulomatosis with polyangiitis). *Acta Otorrinolaringol Esp* 2012;63:206-11.
2. Bilgin M, Oğuzkaya F, Hasdıraz L, Özkaya M. Trakeal stenozlar: Cerrahi tedavi ve sonuçları. *Turk Gogus Kalp Dama* 2006;14:212-5.
3. Morcillo A, Wins R, Gómez-Caro A, Paradela M, Molins L, Tarrazona V. Single-staged laryngotracheal reconstruction for idiopathic tracheal stenosis. *Ann Thorac Surg* 2013;95:433-9.
4. Gouveris H, Karaiskaki N, Koutsimpelas D, Chongolwatana C, Mann W. Treatment for adult idiopathic and Wegener-associated subglottic stenosis. *Eur Arch Otorhinolaryngol* 2013;270:989-93.
5. Montgomery WW. Posterior and complete laryngeal (glottic) stenosis. *Arch Otolaryngol* 1973;98:170-5.
6. Grillo HC, Mathisen DJ, Wain JC. Laryngotracheal resection and reconstruction for subglottic stenosis. *Ann Thorac Surg* 1992;53:54-63.