

# Solution Seeking for Arteriovenous Fistula Formation in End-Stage Renal Failure Patients: A New Trial: Surgical Technique

## Son Evre Böbrek Yetersizliği Olan Hastalarda Arteriovenöz Fistül Oluşturulmasında Çözüm Arayışları: Yeni Bir Deneme

Bülent ÇÜMEN,<sup>a</sup>  
İhsan ALUR,<sup>a</sup>  
Yusuf İzzettin ALİHANOĞLU,<sup>b</sup>  
Ali Baran BUDAK,<sup>c</sup>  
Bekir Serhat YILDIZ<sup>b</sup>

<sup>a</sup>Department of Cardiovascular Surgery,  
Denizli State Hospital,

<sup>b</sup>Department of Cardiology,  
Pamukkale University Faculty of Medicine,  
Denizli

<sup>c</sup>Department of Cardiovascular Surgery,  
Numune Training and Research Hospital,  
Ankara

Geliş Tarihi/Received: 13.03.2013

Kabul Tarihi/Accepted: 05.12.2013

Yazışma Adresi/Correspondence:

İhsan ALUR

Denizli State Hospital,

Department of Cardiovascular Surgery,

Denizli,

TÜRKİYE/TURKEY

alur\_i@hotmail.com

**ABSTRACT** Some problems have been encountered during creation of arteriovenous fistulae in hemodialysis-dependent end stage renal failure patients. Patient-related factors such as insufficient blood flow due to atherosclerosis of the arterial bed, insufficiency of venous vessel diameters and phlebotic or thrombotic veins play an important role in these problems. The quality of the surgical anastomosis is a must. In chronic renal failure patients, when the radial artery is atherosclerotic, it becomes more difficult to create an arteriovenous fistula in the forearm. First, the radial artery blood flow must be resolved. To resolve the blood flow of the radial artery, we performed brachio-radial bypass with an autogenous saphenous vein graft in 4 patients, and then created a simultaneous graft-saphenous arteriovenous fistula. In the postoperative follow-up, the fistulae were seen to be patent, and thrill was positive. Patients continued to undergo hemodialysis. We suggest that this technique can be performed in patients with advanced radial artery atherosclerosis.

**Key Words:** Arteriovenous fistula; brachio-radial bypass; atherosclerosis

**ÖZET** Hemodiyalize bağımlı son evre böbrek yetmezliği olan hastalarda arteriovenöz fistül oluşturulmasında bazı problemlerle karşılaşılmaktadır. Arteriyel yatağın aterosklerotik olmasına bağlı kan akımının yetersiz olması, venöz damar çaplarının yetersizliği ve venlerin flebitik veya trombotik olması gibi hastaya ait faktörler önemli rol oynar. Cerrahi anastomozun kalitesi de olmazsa olmaz koşuldur. Kronik böbrek yetmezlikli hastalarda radial arter aterosklerotik olduğunda önkolda arteriovenöz fistül oluşturmak güçleşir. Öncelikle radial arter kan akımının düzeltilmesi gerekir. Biz 4 hastada otojen safen ven grefti ile "brakio-radial bypass" yaparak, radial arter kan akımını düzelttikten sonra eş zamanlı grefto-sefalik arteriovenöz fistül oluşturduk. Postoperatif izlemlerde fistüller patent, trill pozitif idi. Hastalar hemodiyalize devam etmektedir. İleri derecede radial arter ateroskleroza olan hastalarda bu tekniğin uygulanabileceğini düşünüyoruz.

**Anahtar Kelimeler:** Arteriovenöz fistül; brakio-radial bypass; ateroskleroz

**Damar Cer Derg 2016;25(2):94-6**

**H**emodialysis-dependent chronic renal failure patients (CRF) require a venous-arterial access path with an adequate flow (at least 300 ml/minute). The access path is the double lumen dialysis catheter or arteriovenous fistula (AVF), and because of the ease of access to dialysis and suitability for constant use in hemodialysis-dependent CRF patients, autogeneous AVF is the most preferred one.<sup>1</sup> For the first time in the history of medicine, Brescia and colleagues have described the application AVF for hemodialysis.<sup>2</sup> For an effectively working AVF (to be able to perform

doi: 10.9739/uvcd.2013-35180

Copyright © 2016 by  
Ulusal Vasküler Cerrahi Derneği

dialysis at least with a 300 ml/min flow for 4 hours) sufficient arterial flow and a good quality vein are needed.<sup>3,4</sup>

## PREOPERATIVE EXAMINATION

On the physical examination of 4 patients who had presented to our clinic for formation of AVF for hemodialysis, the radial artery pulses were not palpated bilaterally. On the upper extremity arterial color Doppler ultrasonography (CDUS) evaluation, the radial artery blood flow was determined to be less than 300 ml/minute. The patients had previously undergone repeated AVF attempts.

The patients were operated following physical examination and upper extremity CDUS evaluation. During the CDUS evaluation, deep venous system, axillary and subclavian vein patencies were also evaluated. In the clinical examination, we evaluated whether a saphenous vein graft (SVG) could be suitable or not.

## OPERATIVE TECHNIQUE

In our clinic, we prefer the non-dominant arm of the patient for AVFs. We give antibiotic prophylaxis with 1<sup>st</sup> generation cephalosporins (Iespor 1 gr. IV), 1 hour preoperatively. The patients had general anesthesia. As the SVG was prepared, the brachial and the radial arteries were freed and suspended. Two minutes before placement of the plastic bulldog clamps, 50-100 U/kg heparin was administered intravenously. Using SVG and 7/0 prolene, a brachio-radial bypass was performed by the 'End-to-side' anastomosis technique (Figure 1). Radial artery blood flow was observed to be resolved. Then, the Cephalic vein was freed and anastomosed to the bypass graft with 7/0 prolene by the 'end-to-side' anastomosis technique, and the graft-cephalic arteriovenous fistula was formed.

## FINDINGS

We did not encounter any problems in 2- year- follow up of patients in whom the radio-cephalic AVF had been created after the brachio-radial bypass. Three patients were males and 1 patient was female. The mean age was 60 years; the average duration of

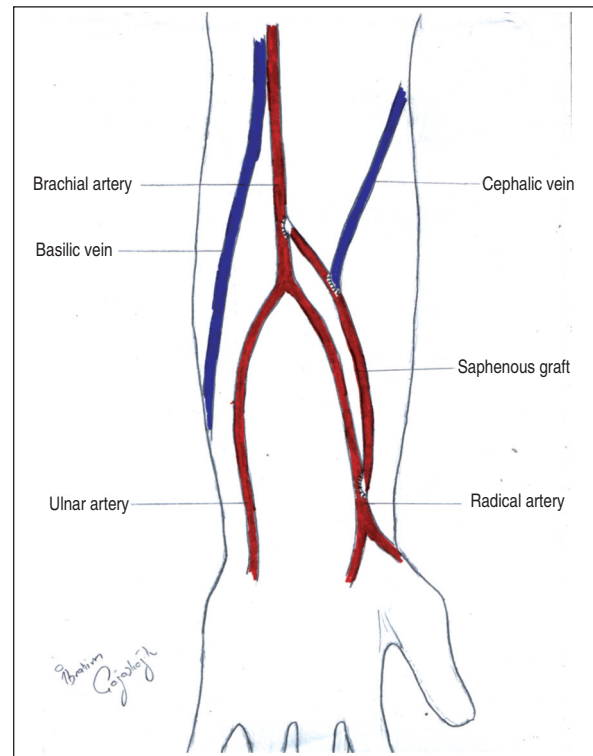


FIGURE 1: Schematic view of the operative technique.

TABLE 1: Co-morbid disorders of the patients.

	N	%
Hypertension	3	75
Diabetes mellitus	4	100
Dyslipidemia	3	75
Peripheral arterial disease	2	50

hemodialysis was 12 years. On control CDUS, we determined the fistula blood flow to be a mean of 420 ml/min. Previously formed mean AVF number of the patients was 4. The rates of co-morbid disorders were respectively, hypertension (HT) in 75% (3/4), diabetes mellitus (DM) in 100% (4/4), peripheral arterial disease in 50% (2/4) and dyslipidemia in 75% (3/4), as presented in Table 1. Postoperative early mortality (30 days) was not observed.

## DISCUSSION

Chronic renal failure patients (CRF) require a venous-arterial access path with adequate flow (at least 300 ml/minute) for hemodialysis. The most commonly preferred vessel access path in these patients is

autogenous AVF.<sup>5-7</sup> Hemodialysis-dependent end-stage renal failure patients require hemodialysis from an effectively working AVF until they get the chance of renal transplantation. Persistence of the patency of this AVF for a long period, to have an ideal blood flow and to provide optimum benefit to the patient with the fewest complications (ischemic steal syndrome, high-output heart failure, etc.) should be provided.<sup>8,9</sup> The most commonly used anatomical locations of AVF for CRF patients are the radio-cephalic and brachio-cephalic AVFs in the upper extremities. In these patients, in general, there is inadequate vessel quality due to predisposing factors such as advanced age, DM, HT, dyslipidemia, metabolic syndrome and smoking. On physical examination, the radial artery pulse may not be palpated due to radial artery atherosclerosis. Compared to the synthetic grafts, AVFs that are formed by autogenous SVG have been reported to remain patent in 60-80% of cases.<sup>10</sup>

In CRF patients, when the radial artery is atherosclerotic, it becomes more difficult to create an arteriovenous fistula in the forearm. First, the radial artery blood flow must be resolved. In 4 patients, we determined that the radial artery blood flow was less than 300 mL/minute on the upper extremity on CDUS.

We performed brachio-radial artery bypass with autogenous SVG, and resolved the blood flow of the radial artery, then created a simultaneous graft-saphenous arteriovenous fistula. In 2-year follow ups, the fistulae were seen to be patent, and thrill was positive. The patients are still undergoing hemodialysis.

We think that the method that we used has advantages when the patients who are continuously undergoing hemodialysis due to chronic renal failure have thrombosis in the distal cephalic vein in the forearm, or when the post-phlebitis or radial artery is atherosclerotic.

Radio-cephalic arterio-venous fistula complications due to brachial artery punctures are less common compared to when the cephalic vein is in the lateral side of the arm where the basilica vein is used in the A-V fistula.

In situations where the distal cephalic vein is not used (trombophlebitis, etc.) and an AV fistula is created between the brachio-radial artery bypass graft and the cephalic vein (grafto-cephalic arteriovenous fistula), the elbow joint will be proximal to the fistula and dorsal flexion of the elbow will not affect the fistula (Figure 1).

We suggest that ischemic steal syndrome in the forearm will occur less frequently by creating a grafto-cephalic arteriovenous fistula by brachio-radial artery bypass graft and the cephalic vein technique, because the brachio-radial artery bypass increases the radial artery blood flow, and the formed fistula is distal to the brachial artery.

### Conflict of Interest

*Authors declared no conflict of interest or financial support.*

## REFERENCES

1. Turkish Society of Nephrology. Registry of the Nephrology, Dialysis and Transplantation in Turkey. Registry 2004. Omega CRO. İstanbul, Turkey: Turkish Society of Nephrology; 2005 June.
2. Brescia MJ, Cimino JE, Appel K, Hurwicz BJ. Chronic hemodialysis using venipuncture and a surgically created arteriovenous fistula. *N Engl J Med* 1966;275(20):1089-92.
3. Mardan M, Özgür B, Kürşat S, Sakarya A, Erhan Y, Aydede H. Vascular accesses for chronic hemodialysis. *Turkish J Thorac Cardiovasc Surg* 2001;2:38-47.
4. Cassiouris D, Fatouros MS, Siamopoulos KC, Giannoukas AD. Short- and long-term evaluation of arteriovenous fistulas for chronic hemodialysis. *Microsurgery* 1992;13(5):236-7.
5. Fitzgerald JT, Schanzer A, Chin AI, McVicar JP, Perez RV, Troppmann C. Outcomes of upper arm arteriovenous fistulas for maintenance hemodialysis access. *Arch Surg* 2004;139(2):201-8.
6. Goodkin DA, Pisoni RL, Locatelli F, Port FK, Saran R. Hemodialysis vascular access training and practices are key to improved access outcomes. *Am J Kidney Dis* 2010;56(6):1032-42.
7. Kim HS, Park JW, Chang JH, Yang J, Lee HH, Chung W, et al. Early vascular access blood flow as a predictor of long-term vascular Access patency in incident hemodialysis patients. *J Korean Med Sci* 2010;25(5):728-33.
8. Suding PN, Wilson SE. Strategies for management of ischemic steal syndrome. *Semin Vasc Surg* 2007;20(3):184-8.
9. Murphy GJ, White SA, Nicholson ML. Vascular access for hemodialysis. *Br J Surg* 2000;87(10):1300-15.
10. Huber TS, Carter JW, Carter RL, Seeger JM. Patency of autogenous and polytetrafluoroethylene upper extremity arteriovenous hemodialysis accesses: a systematic review. *J Vasc Surg* 2003;38(5):1005-11.