



Stomach metastasis of low grade endometrial stromal sarcoma

Serdar Kirmizi¹, Bercis Imge Ucar², Demet Aydoğan Kirmizi³, Sevda Yılmaz⁴

1 Gastroenterology Surgery, Yozgat City Hospital, Yozgat 66100, Turkey, ORCID: 0000-0001-9385-1450

2 General Surgery, Yozgat City Hospital, Yozgat 66100, Turkey ORCID: 0000-0003-0229-5589

3 Department of Obstetrics and Gynaecology, Bozok University School of Medicine, Yozgat 66200, Turkey ORCID: 0000-0001-7849-8214

4 Department of Surgery, Pamukkale University School of Medicine, Denizli 20100, Turkey ORCID: 0000-0002-1309-0805

Received: 27.03.2019; Revised: 03.05.2019; Accepted: 30.07.2019

Abstract

Endometrial stromal sarcomas (ESS) are rare mesenchymal tumors of the uterus. Low-grade endometrial stromal sarcoma (LGESS) constitutes approximately two-thirds of ESS. Metastasis of LGESS can be seen after many years. In the endoscopic examination, a 57-year-old female patient with dyspeptic complaints was diagnosed with mesenchymal originated tumor located in the antrum of the stomach. It is reported that the patient underwent a hysterectomy and unilateral oophorectomy 15 years ago due to vaginal bleeding.

A mass in the stomach approximately 5 cm in diameter was detected in the abdominal contrast-enhanced computed tomography. She underwent subtotal gastrectomy and omentectomy, and immunohistological examination was reported as LGESS. As far as we know, it is the first case reported as a LGESS metastasis to stomach so far. We should bear in mind that metastasis of LGESS may be seen after many years. It should be included in differential diagnosis of gastrointestinal stromal tumors.

Key words: Endometrial stromal sarcoma, gastrointestinal stromal tumor, stomach, metastasis

DOI: 10.5798/dicletip.545723

Yazışma Adresi / Correspondence: Serdar Kirmizi, MD, Gastroenterology Surgery, Yozgat City Hospital, Yozgat 66100, Turkey
e-mail: drserdarkirmizi@hotmail.com

Düşük dereceli endometrialstromal sarkomun mideye metastazı

Öz

Endometrial stromal sarkomlar (ESS) nadir karşılaşılan uterusun mezenkimal tümörleridir. Low Grade Endometrial Stromal Sarkom (LGESS) ESS'lerin yaklaşık üçte ikisini oluşturur. LGESS metastazı çok uzun yıllar sonra görülebilir. Dispeptik şikayetler nedeniyle yapılan tetkiklerde 57 yaşındaki bayan hastanın endoskopik incelenmesinde mide antrumunda mezenşimal tümör saptandı.

Hastanın vajinal kanama nedeniyle onbeş yıl önce histerektomi ve unilater aloferektomi yapıldığı ve LGESS tanısı aldığı öğrenildi. Kontrastlı bilgisayarlı tomografide (BT) mide de yaklaşık 5 cm çapında kitle saptandı. Subtotal gastrektomi ve omentektomi uygulandı, immuno histolojik incelemede LGESS olarak raporlandı. Bildiğimiz kadarıyla primeruterus kaynaklı LGESS'in mideye metastazı saptanan ilk olgu olma özelliği taşımaktadır. LGESS'in çok uzun yıllar sonra midenin gastrointestina lstromal tümörleriyle karışabilecek metastatik kitle ile karşımıza çıkabileceği akılda tutulmalıdır.

Anahtar kelimeler: Endometrial stromal sarkom, gastrointestinal stromal tümör, mide, metastaz.

INTRODUCTION

Endometrial stromal sarcom (ESS) are rarely seen tumors that constitute 0.2% of uterine malignities¹. It has several subgroups categories accoring to their pathological and anatomical features such as low-grade ESS (LGESS), high-grade ESS (HGESS) and undifferentiated ESS. This classification is made according to cytological pleomorphism, nuclear atypia degree and the presence of tumor cell necrosis rather than number of mitosis of the tumor. LGESS constitutes two-thirds of uterus sarcoma.

These tumors may cause metastasis even 20-25 years later. LGESS tends to metastasis to abdomen, pelvis and lungs. ESS may both develop in endometriosis tissue from gastrointestinal system or extra gastrointestinal tissue². For stomach metastasis, a case with extra uterine ESS origin was reported in the literature. However, as far as we know the presented case is the first case that revealed metastasis of LGESS to stomach 15 years later.

CASE PRESENTATION

A 57-year-old female patient with dyspeptic complaints was diagnosed with mesenchymal originated tumor located in the antrum of the

stomach after endoscopic biopsy was performed. It is reported that the patient underwent a hysterectomy and unilateral (right) oophorectomy 15 years ago due to vaginal bleeding and had a medical history of asthma. Laboratory findings showed no abnormalities. The mass located in the junction of big curvature antrum-corporus with a size of 55 mm x 42 mm was detected in the abdominal contrast-enhanced computed tomography (Figure 1 A,1 B). Informed consent was obtained from patient and relatives of the patient. She underwent subtotal gastrectomy and omentectomy, and immunohistological examination was reported as LGESS.

Positron Emmision Computerized Tomography (PET-CT) showed pathological FDG uptake in the mass which indicated malignancy (Figure 2). Immuno histopathological examination was reported as neoplastic lesion dyed with vimentin (+), smooth muscle actin (+), s-100 (-), CD34 (-), CD31 (-), pansitokeratin (-), CD117 (-). The lesion was described by pathologist as fusiform cells in submucosal area and total excision of the lesion was recommended in order to decide whether the lesion is benign or malignant. Informed consent was obtained from patient and relatives of the patient. Laparoscopic wedge gastric resection was performed with a pre-diagnosis of

gastrointestinal stromal tumor (GIST) of the stomach. One month later subtotal gastrectomy and omentectomy was performed as the histopathological examination of the previous specimen revealed positive surgical margin and the final report of the immunohistochemical examination was reported as LGESS with a diameter of 1.4cm and 18 reactive lymphadenopathy in total. Lymphovascular invasion of the tumor was detected. Yet, no perineural invasion was seen. Immunohistochemical examination of the tumor revealed estrogen receptor positivity (ER+), progesterone receptor positivity (PR+), Bcl-2 positivity. Patient was discharged without any problem on the 5th postoperative day. She was prescribed Megestrol acetate 160 mg (once a day). During 6 month-follow-up no sign of recurrence or metastasis was detected.

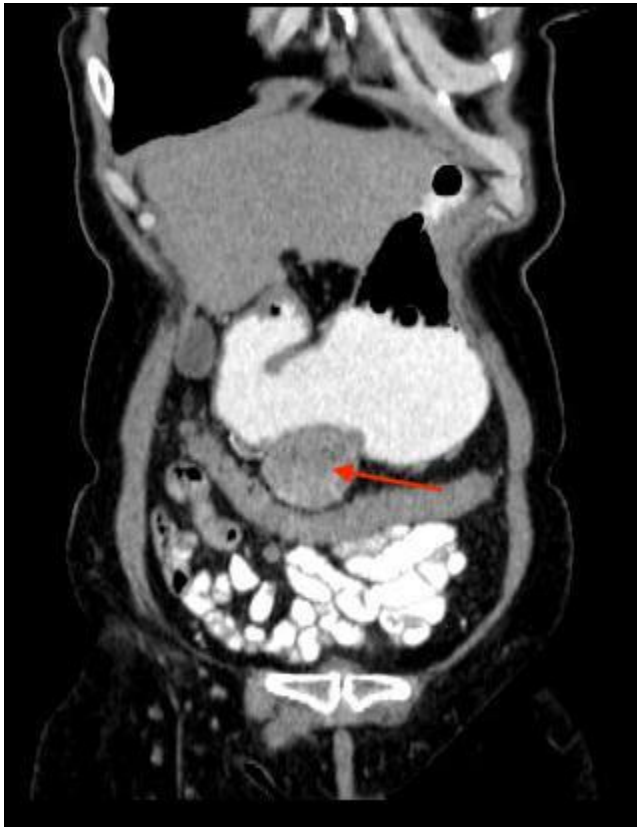

Figure 1 A: Coronal CT image of the mass (Red arrow).

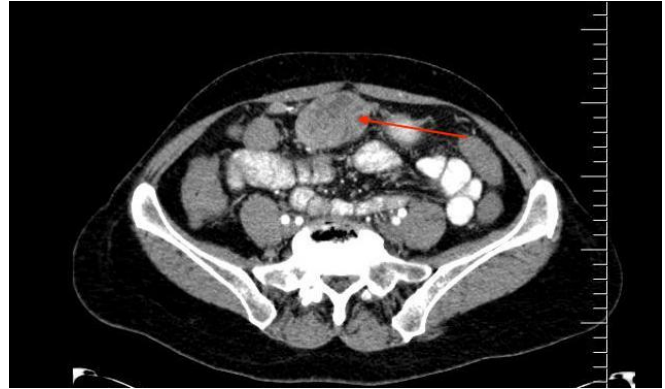


Figure 1 B: Sagittal Computed tomography image of the mass (Red arrow).

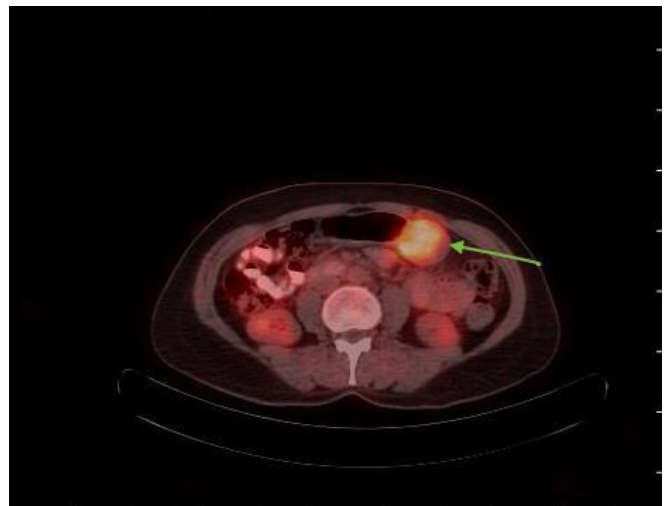


Figure 2: Axial PET image of the mass (Green arrow).

DISCUSSION

ESS is a tumor constitute 0.2% of uterine malignancies (1). Mostly two-thirds of ESS cases are LGESS. LGESS can be seen in women at the age between 15 and 96 years and 50-88% of the patients diagnosed with LGESS are premenopausal. It is suggested that LGESS is associated with hyperestrogenism caused by exogenous estrogen intake, assisted reproduction or endometriosis. 48-72% of the patients have abnormal uterine bleeding (intermenstrual bleeding, menorrhagia, postmenopausal bleeding)³.

LGESS has a rather good prognosis. Disease stage is the most important prognostic factor. Surgery has a great importance in diagnosis

and treatment of ESS. Negative surgical margin is an important prognostic factor. There is a general consensus on the issue that lymphadenectomy has no effect on prognosis. Sparing the ovaries may increase the rate of recurrence and the risk of metastasis with no effect on survival. In early stages of LGESS, clinical observation can be sufficient if the patient is postmenopausal or underwent bilateral oophorectomy. Otherwise, estrogen blockage treatment (megestrol, medroxyprogesterone, aromatase inhibitors, gonadotropin-releasing hormone (GnRH)) should be a part of the complete treatment⁴.

It is also suggested that extra uterine LGESS may be originated from endometriosis tissue. However, malignant transformation of endometriosis tissue is a rare condition and it has a prevalence is of 1%. Most of them are carcinomas, whereas sarcomas are scarce⁵. In the present case, the patient was diagnosed with LGESS 15 years ago, and as it is known that these tumors tends to e many years after on-set and no endometriosis was detected in the histopathological examination of the surgical specimen, it is considered as a metastatic gastric lesion of LGESS rather than a primary gastric tumor.

Two-thirds of mesenchymal tumors of stomach are GISTs which have malignant potential. Biopsy results are usually reported as insufficient as the lesions are located in the submucosal layer of the stomach. Total excision of the mass may be required in order to conclude the diagnosis. GIST can easily be confused with ESS due to its macroscopic and microscopic features. The specimen should be assessed by an expert pathologist and the case should be referred to a more advanced center, as in our case, to increase the accuracy in diagnosis. Immunohistochemical markers are the most important diagnostic parameters in these cases. While CD 117 and CD34 are positive and diffusely dyed in GIST, CD 10, estrogen and progesterone receptors are

positive in ESS. Strong 18F-fluorodeoxyglucose (FDG) uptake is detected in GIST. FDG PET-CT is a very valuable to reduce the diagnostic ambiguity seen in CT and magnetic resonance imaging (MRI) and its specificity is around 86-98%⁶.

Recurrent and metastatic lesions of ESS are generally tend to grow slowly. Liver, lungs, bone, heart and retroperitoneal metastasis of LGESS were reported previously^{7,8}. A LGESS in diameter of 5 cm detected in endometriosis located in the ileocecal area and the mesentery of 35-year-old patient was reported by Kentu SR et al. Hysterectomy and bilateral salpingo-oophorectomy were performed, the tumor was diagnosed as stromal sarcoma of uterus. In the postoperative follow-ups, endoscopic examination revealed a 2 cm sub-epithelial lesion at the antrum of the stomach and wedge resection was performed. Histopathological examination noted that the lesion in the stomach was also LGESS⁹. This case was probably an extra-uterine LGESS developed on the base of the endometriosis tissue which metastasized to the stomach. We should bear in mind that metastasis of LGESS may be seen after many years. It should be included in differential diagnosis of gastrointestinal stromal tumors.

Conflicts of interest: The authors have no conflict of interests to declare.

Financial Disclosure: The authors declared that this study has received no financial support.

REFERENCES

1. Amant F, Coosemans A, Debiec-Rychter M, Timmerman D, Vergote I. Clinical management of uterine sarcomas. *Lancet Oncol* 2009; 10: 1188-98.
2. Kim L, Choi SJ, Park IS, et al. Endometrial stromal sarcoma of the small bowel. *Ann Diagn Pathol* 2008; 12: 128-33.

3. Bai H, Yang J, Cao D, et al. Ovary and uterus sparing procedures for low-grade endometrial stromal sarcoma: A retrospective study of 153 cases. *Gynecologic oncology* 2014; 132: 654–60.
4. Koh WJ, Abu-Rustum NR, Bean S, et al. Uterine neoplasms, version 1.2018, NCCN clinical practice guidelines in oncology. *Journal of the National Comprehensive Cancer Network* 2018; 16: 170-99.
5. Heaps JM, Nieberg RK, Berek JS. Malignant neoplasms arising in endometriosis. *Obstetrics and Gynecology* 1990; 75: 1023–28.
6. Kalkmann J, Zeile M, Antoch G, et al. Consensus report on the radiological management of patients with gastrointestinal stromal tumours (GIST): recommendations of the German GIST Imaging Working Group. *Cancer Imaging* 2012; 12: 126–35.
7. Zhu Q, Sun YQ, Di X Q, Huang B, Huang, J. Metastatic low-grade endometrial stromal sarcoma with sex cord and smooth muscle differentiation: A case report. *World journal of clinical cases* 2019; 7: 221.
8. Argadjendra M, Ahmadi N, Varol C. A Case of Retroperitoneal Metastases That Occur 14 Years After Surgery. *Urology case reports* 2016; 9: 21-3.
9. Kethu SR, Zheng S, Eid R. Metastatic low-grade endometrial stromal sarcoma presented as a subepithelial mass in the stomach was diagnosed by EUS-guided FNA. *Gastrointestinal endoscopy* 2005; 62: 814-6.