

Analysis of digital panoramic imaging findings of completely edentulous patients applying for prosthetic treatment

 Sezgi Cinel Sahin¹,  Melih Ozdede²

¹Department of Prosthodontics, Faculty of Dentistry, Pamukkale University, Denizli, Turkey

²Department of Dentomaxillofacial Radiology, Faculty of Dentistry, Pamukkale University, Denizli, Turkey

Copyright © 2020 by authors and Annals of Medical Research Publishing Inc.

Abstract

Aim: The aim of this study is determination of the prevalence and clinical significance of random findings detected in digital panoramic images of complete edentulism patients, applied for prosthetic treatment.

Material and Methods: Of the 382 images, 189 digital panoramic images (49.5%) matching the study criteria were included in the study. The positive findings were evaluated, such as impacted teeth, residual roots, radiolucent lesions, radiopaque (RO) lesions, foreign bodies, atrophic crest, soft tissue calcifications (STCs), maxillary sinus opacities, Stafne bone defects, stylohyoid ligament ossifications, and laryngeal cartilage calcifications. The findings were analyzed in different age groups and evaluated with descriptive analysis.

Results: Images of 100 male (53%) and 89 female (47%) patients with a mean age of 64.2±9.6 were examined. It was found that 80% (n=151) of the patients were delivered conventional complete dentures, 20% (n=38) of them were delivered complete dentures in the upper jaw, and two implant-retained overdentures in the lower jaw. The detected positive radiographic findings were 94.7% (n=179); 48.7% (n=87) were in female and 51.3% (n=92) were in male. The most common positive findings were maxillary (50.7%) and mandibular (28.4%) crest atrophies, followed by maxillary sinus opacities (25.9%), and STCs in tonsilloliths region (18.5%). In all age groups, the most common positive finding was maxillary crest atrophy.

Conclusion: The results of this study showed that the rate of positive findings detected in digital panoramic images of completely edentulous patients was high. Routine use and careful examination of panoramic images are essential for patients with complete edentulism.

Keywords: Complete denture; edentulous jaw; incidental findings; panoramic radiography; prevalence

INTRODUCTION

The idea that completely edentulous patients should be evaluated radiographically was brought up by Logan for the first time (1). In a study evaluating 35 edentulous jaws, 28.6% of the patients had residual root fragments and impacted teeth, which have clinical significance and could affect treatment (2). In the following periods, it was thought that before the prosthetic treatment of such edentulous patients, the jaws should be examined with radiographs in terms of many pathologies such as residual roots, impacted teeth, infections, cyst-tumor lesions, bone changes and presence of foreign bodies (2,3). However, due to radiation hazards, the issue that only patients with strict clinical symptoms of pathology should be examined radiographically is also frequently discussed (2,4).

Due to the high rates of positive findings (ranging from 16% to 68%) in studies in which completely edentulous patients

were evaluated radiographically and the possibility of early diagnosis of asymptomatic pathologies (2,3,5-7), Food and Drug Administration, Center for Devices and Radiological Health, and American Dental Association recommend panoramic radiography evaluation following intraoral examination (7).

The most important advantage of panoramic radiography is that, a general evaluation of both jaws and adjacent anatomical structures can be made thanks to a single radiographic image obtained in a short time and with low dose radiation (3,8-10). In panoramic radiographic examinations performed in completely edentulous patients, apart from pathologies, many anatomical and structural conditions that may affect prosthetic treatment, such as the route of the mandibular canal, the position of the mental foramen and maxillary sinuses, and bone resorption level (2,3,11,12). Since the area that can be

Received: 26.04.2020 **Accepted:** 21.08.2020 **Available online:** 18.09.2020

Corresponding Author: Melih Ozdede, Department of Dentomaxillofacial Radiology, Faculty of Dentistry, Pamukkale University, Denizli, Turkey **E-mail:** melihozdede@gmail.com

examined is large, the presence of soft tissue calcifications (STCs) such as calcified carotid artery atheroma, sialolith, and tonsillolith, which are both dental and medically important, can be determined (13,14).

Although a large number of studies have been conducted in the literature on the detection of asymptomatic pathologies in completely edentulous patients (2, 5, 9), the number of studies investigating the rate of radiographic findings requiring treatment is limited (2,5,11). The purpose of this retrospective study is to determine the prevalence of incidental findings detected on digital panoramic images, obtained from completely edentulous patients who applied for complete denture or implant-retained overdentures.

MATERIAL and METHODS

This study protocol was carried out with the principles of Helsinki Declaration and all amendments and revisions. Patients or legal delegates gave their informed consent before radiographic and prosthetic procedures. Before the research, ethical approval was received from Medical Ethics Committee of Pamukkale University (No: 60116787-020/26601).

The images were obtained in the same digital panoramic imaging device (OP200D; Instrumentarium Corp, Tuusula, Finland) with standard exposure parameters (66kV, 10 mA, 16 sec) following the manufacturer's instructions, evaluated on the medical monitor (Barco Medical, Kortrijk, Belgium) with aspecial software (CliniView version 10.2.6; Instrumentarium Dental, Tuusula, Finland). The examinations were carried out retrospectively by a dentomaxillofacial radiologist (M.O.), and a prosthodontist (S.C.S), at the same time and in consensus. Before the dental prosthetic treatment, digital panoramic images obtained from the completely edentulous patients were evaluated. The images with high radiographic quality, including vertebra and hyoid bone in the imaging region, were included in the study. Low-quality images with artifacts due to patient position/motion, and images with maxillofacial trauma, postoperative defect, or developmental anomalies were excluded. Besides, images without consensus among the observers and images from other centers/devices were not included in the study. As a result of the evaluation, 189 of the 382 completely edentulous patient images, which are following the study criteria, were examined.

For our research; impacted teeth, intra-bony residual roots, impacted roots with mucosal retention (some or all of which are not in the alveolar bone), radiolucent (RL) lesions, radiopaque (RO) lesions (including idiopathic osteosclerosis), foreign bodies, crest atrophies, STC lesions, maxillary sinus opacities and Stafne bone defects (SBDs) were examined. The lesions affecting the alveolar region were divided into three regions as anterior (incisors and canine teeth region), premolar, and molar teeth region (11). Other structures and lesions were classified as right, left, and bilateral. The regions with mandibular canal-crest distance and maxillary sinus floor-crest

distance less than 2 mm were considered as 'atrophic crest' (11). Mucosal thickening, mucous retention cyst, polypoid growth, antroliths, and antral exostoses were included in the group of maxillary sinus radiopacities. As the exact three-dimensional location of STC lesions can not be determined by panoramic radiography, these groups of lesions were divided into three categories as in the study conducted by Köse et al (11). According to this study, the region where palatal tonsilloliths and parotid calcifications were seen was classified as STC-1; submandibular sialoliths, and submandibular lymph node calcifications region were STC-2, and the area where carotid calcifications were observed was classified as STC-3. Stylohyoid ligament ossifications (SLO), laryngeal cartilage calcifications (LCC), and SBDs were also evaluated (Figure 1-3).

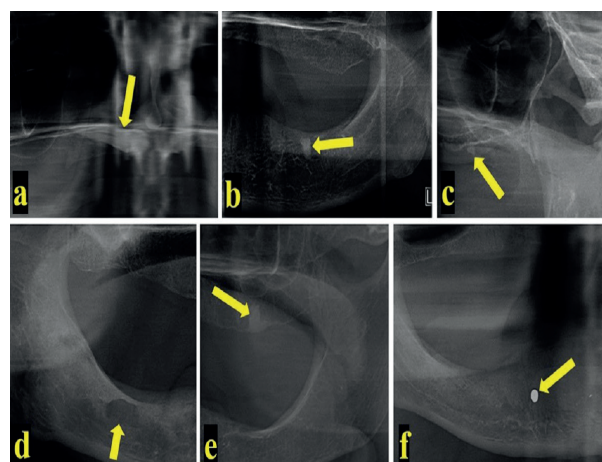


Figure 1. In cropped panoramic images, impacted tooth (a), bone retention impacted root (b), mucosal retention impacted root (c), radiolucent lesion (d), radiopaque lesion (e) and foreign body (f) samples are shown with arrows

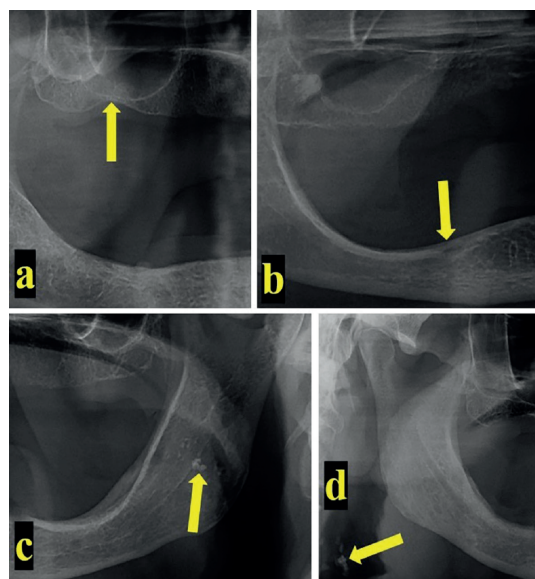


Figure 2. In cropped panoramic images, samples of atrophic maxilla (a), atrophic mandible (b), tonsillolith (c) and carotid calcification (d) are shown with arrows

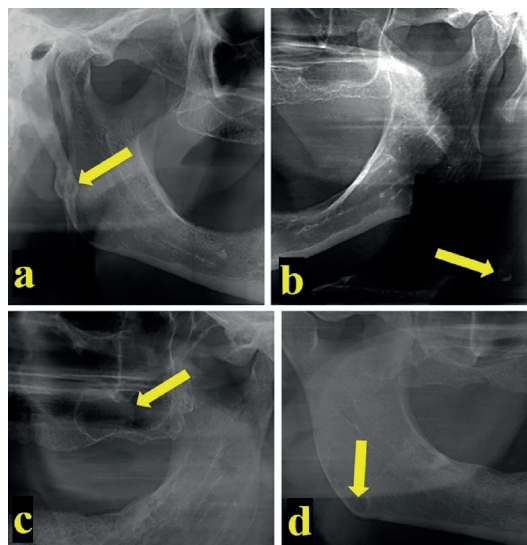


Figure 3. In cropped panoramic images, stylohyoid ligament ossification (a), laryngeal cartilage calcification (b), maxillary sinus opacity (c) and Stafne bone defect (d) are shown by arrows

According to the age distribution, four different patient groups were formed; first group between the ages of 35-55, second group between the ages of 56-65, third group between the ages of 65-75 and fourth group between the ages of 76-95. The data collected regarding the age-gender of the patients and the types of the prosthesis (complete denture or implant-retained overdenture) delivered to the patients were evaluated by descriptive analysis.

RESULTS

Of the 382 images, 189 digital panoramic images (49.5%) matching the study criteria were included in the study. It was determined that 100 of the patients in the study were male (53%) and 89 were female (47%). The average age of the patients was 64.2 ± 9.6 . It was determined that 80% of the patients were delivered conventional complete dentures, 20% of the patients received conventional complete dentures in the upper jaw and two implant-retained overdentures in the lower jaw. The rate of one or more positive radiographic findings detected in patient images was 94.7% (n=179). Positive findings were found in 48.7% of females (n=87) and 51.3% of males (n=92). The most common findings were mandibular canal-crest distance and maxillary sinus floor-crest distance less than 2 mm. The lesions following them were maxillary sinus opacities, STC-1, RO lesions, impacted residual roots (in the bone), SLO, STC-3, and LCC, respectively. Other pathologies were observed in fewer patients (Table 1). In terms of the age groups, 29 patients were in Group 1 (35-55 years), 74 patients in Group 2 (56-65 years), 64 patients in Group 3 (65-75 years), and 22 patients were in Group 4 (76-95 years old). When the distribution of pathologies according to the age groups of the patients is investigated, it was observed that the maxillary atrophy (44.8%) and maxillary sinus opacity (20.6%) were common in the first group. In Group 2, maxillary sinus opacity (21.6%) was common following maxillary (51.3%) and mandibular

Table 1. Radiographic findings prevalence and distribution by gender-age groups

Radiographic Findings	Gender		Age				Total
	Female	Male	Group 1 (35-55)	Group 2 (56-65)	Group 3 (66-75)	Group 4 (76-95)	
	n (%)	n (%)	n (%)	n (%)	n (%)	n (%)	n (%)
Impacted tooth	6 (6.7)	5 (5)	1 (3.4)	4 (5.4)	3 (4.6)	3 (13.6)	11 (5.8)
Impacted residual root	11 (12.3)	15 (15)	3 (10.3)	13 (17.5)	7 (10.9)	3 (13.6)	26 (13.7)
Mucosal retention root	9 (10.1)	6 (6)	2 (6.8)	7 (9.4)	5 (7.8)	1 (4.5)	15 (7.9)
Radiolucent lesion	1 (1.1)	5 (5)	-	4 (5.4)	2 (3.1)	-	6 (3.1)
Radiopaque lesion	17 (19.1)	10 (10)	5 (17.2)	8 (10.8)	11 (17.1)	5 (22.7)	27 (14.2)
Foreign bodies	2 (2.2)	5 (5)	1 (3.4)	5 (6.7)	1 (1.5)	-	7 (3.7)
Atrophic maxilla	45 (50.5)	51 (51)	13 (44.8)	38 (51.3)	34 (53.1)	11 (50)	96 (50.7)
Atrophic mandible	30 (33.7)	23 (23)	4 (13.7)	18 (24.3)	25 (39)	6 (27.2)	53 (28.4)
STC-1	17 (19.1)	18 (18)	4 (14.7)	7 (9.4)	16 (25)	8 (36.3)	35 (18.5)
STC-2	1 (1.1)	1 (1)	-	1 (1.3)	1 (1.5)	-	2 (1.0)
STC-3	6 (6.7)	13 (13)	2 (6.8)	7 (9.4)	5 (7.8)	5 (22.7)	19 (10)
Maxillary sinus opacities	25 (28)	24 (24)	6 (20.6)	16 (21.6)	19 (29.6)	8 (36.3)	49 (25.9)
SBD	1 (1.1)	6 (6)	1 (3.4)	3 (4)	2 (3.1)	1 (4.5)	7 (3.7)
LCC	10 (11.2)	9 (9)	3 (10.3)	7 (9.4)	7 (10.9)	2 (9)	19 (10)
SLO	9 (10.1)	12 (12)	5 (17.2)	10 (13.5)	5 (7.8)	1 (4.5)	21 (11.1)

STC: Soft tissue calcification, LCC: Laryngeal cartilage calcification, SBD: Stafne bone defect, SLO: Stylohyoid ligament ossification

(24.1%) atrophy. In the third group, maxillary (53.1%) and mandibular atrophy (29%), as well as maxillary sinus opacity (29.6%) and STC-1 (25%) were common. In Group 4, maxillary atrophy (50%) was the most common finding. The prevalence of radiographic findings and distribution by age/gender are detailed in Table 1.

Details of the lesions in the maxillary and mandibular alveolar bone region and their distribution by regions are given in Table 2. It was determined that impacted teeth, residual roots, and foreign bodies were observed more frequently in the maxilla, while RO and RL lesions were more common in the mandible. According to the

regions, RL lesions (40%) were seen more frequently in the maxillary anterior region and residual roots with mucosal retention (40%) in the maxillary molar region. While RL lesions were more common in the anterior region of the mandible (30%), RO lesions were the most common (50%) lesions in the mandibular molar region.

The presence of atrophic crest in the maxilla and mandible, the positive radiographic findings observed in regions other than the alveolar bone, and their distribution by region are given in Table 3. While atrophic crest, maxillary sinus opacities, and SLOs were mostly bilateral in the jaws, SBD was observed more frequently on the left.

Table 2. Positive radiographic findings observed in the alveolar bone regions of the maxilla and mandible and their distribution by regions

Radiographic Findings	Maxilla			Mandible			Maxilla	Mandible	Total
	Anterior	Premolar	Molar	Anterior	Premolar	Molar			
	n (%)	n (%)	n (%)	n (%)	n (%)	n (%)			
Impacted tooth	4 (28.5)	-	4 (28.5)	3 (21.45)	-	3 (21.45)	8 (57.1)	6 (42.9)	14
Impacted residual root	7 (19.5)	7 (19.5)	10 (27.7)	4 (11.1)	3 (8.3)	5 (13.9)	24 (66.7)	12 (33.3)	36
Mucosal retention root	-	5 (33.3)	6 (40)	1 (3.35)	1 (3.35)	3 (20)	11 (73.3)	4 (26.7)	15
Radiolucent lesion	4 (40)	-	-	3 (30)	1 (10)	2 (20)	4 (40)	6 (60)	10
Radiopaque lesion	-	2 (5.9)	10 (29.4)	-	5 (14.7)	17 (50)	12 (35.3)	22 (64.7)	34
Foreign bodies	-	-	1 (11.1)	4 (4.5)	2 (2.2)	2 (2.2)	1 (11.1)	8 (8.9)	9

Table 3. Jaw atrophies, positive radiographic findings observed in regions other than alveolar bone and their distribution by regions

Radiographic Findings	Right	Left	Bilateral	Total
	n (%)	n (%)	n (%)	n
Atrophic maxilla	25 (26)	21 (21.9)	50 (52.1)	96
Atrophic mandible	2 (3.8)	2 (3.8)	49 (92.4)	53
STC-1	15 (42.8)	10 (28.6)	10 (28.6)	35
STC-2	1 (50)	1 (50)	-	2
STC-3	4 (21.1)	8 (42.1)	7 (36.8)	19
LCC	9 (47.3)	7 (36.8)	3 (15.8)	19
Maxillary sinus opacity	7 (14.3)	10 (20.4)	32 (65.3)	49
SBD	1 (14.3)	6 (85.7)	-	7
SLO	3 (14.3)	3 (14.3)	15 (71.4)	21

STC: Soft tissue calcification, LCC: Laryngeal cartilage calcification, SBD: Stafne bone defect, SLO: Stylohyoid ligament ossification

DISCUSSION

One of the most important indications of panoramic radiography is to evaluate the jaws and surrounding tissues before prosthetic applications. However, there are different opinions regarding the use of panoramic radiography in complete denture patients (2,12,15). Some of the studies in the literature opposed routine panoramic radiography before prosthetic application,

arguing that most of the detected positive radiographic findings did not affect the treatment (5,9). However, many researchers have emphasized that it is critical to evaluate all patients in this group with panoramic radiography before treatment (2,12,15). The high rate of positive radiographic findings obtained in our study indicates the importance of examination with panoramic radiography before the prosthetic procedures to be applied in complete edentulous patients.

The studies in which panoramic radiographic images of completely edentulous patients were examined, the rates of positive radiographic findings ranged from 32-68.3% (2, 5,7-9,11,12,15). Proportional differences may be due to factors such as the examination of different structures/pathologies, the experience/expertise of the dentist, and the increased image quality of the devices that develop in time (12). The rate of positive radiographic findings in our study was found to be quite high compared to other studies. This result may have been due to the number of parameters we used in our study to be higher than other studies. In a panoramic radiography study in which Köse et al (11) examined patients with complete edentulism, they reported that 6% of the positive findings required a surgical procedure before conventional complete dentures, and 52.9% of the positive findings required a surgical procedure before implant-supported fixed prosthetic restorations. Bohay et al (7) reported that 8.3% of the patients had positive findings requiring surgical procedures prior to conventional complete denture treatment. In similar studies, Kratz et al (8) and Masood et al (5) reported the rates as 3.6% and 3.8%, respectively. In our study, considering that impacted teeth, residual roots, RL lesions, and foreign bodies may require surgical procedures before prosthetic treatments, 16.6% of the positive findings require surgical intervention before both conventional complete dentures and implant-retained overdentures. From a medical point of view, when STCs and SLOs are evaluated as the lesions to be treated, it was seen that the lesions in these groups constitute 19.6% of the total positive findings of our study. However, for STCs and SLOs, pre-prosthetic treatment may not always be required depending on the symptoms or sizes of the lesions. At the same time, pre-prosthetic treatment may not always be required for the impacted teeth, residual roots, RL lesions, and foreign bodies, depending on the intra-bone location of the lesions.

The most common radiographic findings in previous studies in completely edentulous patients were generally residual roots and impacted teeth (2,5). Impacted teeth in the jaws of completely edentulous patients can cause many complications such as dentigerous cyst, pain, infection, and eruption of the teeth (11). When some of the studies in the literature were examined, it was seen that the rate of impacted teeth in the studies ranged between 3.1-6.2% (2,11,15). In the study of Köse et al (11), which is one of the studies reporting the locations of the impacted teeth, they reported that the majority of the impacted teeth (88%) were observed in the maxilla. Peker et al (12) reported that the impacted teeth were seen most frequently in the mandibular molar region. While the rates determined in our study were found to be compatible with these studies, the positions of the impacted teeth were not concentrated in a certain region.

The rates of submucosal and intra-bony residual roots have been reported as 9.5-16.4% in previous studies, and these rates are consistent with the findings of our study (2,11,15). In the previous studies, residual roots were

mostly observed in the maxillary molar region, as in our study (2,5,11). It may be caused by factors such as the fact that the roots are more frequently seen in the maxilla molar region, the number of roots of the teeth in this region is high, the root morphology is complex, and the root is left in the alveol as a result of the dentist's inability to work comfortably in this region (11).

In the studies, it was found that the rate of RL lesions in completely edentulous patients varies between 1.2-9.9% (2,11,12,15). In our study, this rate was determined as 3.1% and is compatible with the literature. The rates of radiopacity findings detected in the studies were between 1.5-12.9% (2,11,12,15), and the rate in our study was found to be higher with 14.2% compared to these studies. This difference may be explained as a result of examining a more common opacity such as idiopathic osteosclerosis within this group, and most of the previous studies do not have details about RO lesions. The incidence of foreign body findings ranges between 2.2-8.8% in studies (8,11). Findings related to the frequency of foreign bodies in our study are consistent with these studies.

The distance between the maxillary sinus floor and the alveolar crest is important in determining whether there is a need for sinus lift surgery, especially when planning implant surgery (15). Insufficient height between the mandibular crest and the mental foramen/mandibular canal border may lead to pain and paresthesia in the jaw as a result of the pressure of removable dentures in completely edentulous patients (2). In our study, the distance between the maxillary sinus floor-alveolar crest and the mental foramen/mandibular canal-alveolar crest less than 2 mm was specified as the atrophic alveolar crest (11). In previous studies (9,11,12,15), while the rates of atrophic crest findings in the maxilla posterior regions ranged between 8.5% and 30.6%, it was determined that approximately half of the patients in our study had atrophic crest in the posterior region of the maxilla. In these studies, information about atrophic crest height, completely edentulous times of the patients, and also in which age groups were included, were not presented in detail. The fact that the increase in age and edentulism period accompanies the increase in resorption may explain the high rate of atrophy in our study.

The previous studies determined that the rates of the atrophic crest in the posterior regions of the mandible varied between 1.7-4.4%. This rate was found to be much higher (28.4%), in our study (12,15). The lower rate in previous studies is thought to arise from the evaluation of cases where mental foramen is located above the crest as an atrophy criteria for the mandible, that seen less frequently. In our study, the insufficient distance between alveolar crest, and both mental foramen and mandibular canal upper border was considered as atrophy because this criteria is important in terms of both conventional complete denture production and implant-retained overdenture indication. The fact that the mental foramen and the mandibular canal are near or

above the crest requires some precautions to be taken in the production of both types of prostheses. Particularly in deciding the correct impression method, changing the impression method if necessary, and using selective pressure impression method, it is very important to evaluate the atrophy status of the crests and the position of the anatomical structures. In addition, the necessity of relieving the mental foramen area during and after prosthetic treatment is also important for the comfort and function of the prosthesis. In some advanced cases, surgical reposition of the nerve trace may be necessary before both conventional complete denture and implant-retained overdenture treatment (16).

Panoramic radiography helps in the diagnosis of STCs in the maxillofacial region (17). It was reported that tonsilloliths larger than 2 mm can be detected by panoramic radiography (17). In previous studies, the rate of STCs seen in completely edentulous patients varied between 3.4-6% (2, 11). In the study conducted by Köse et al (11), the rate of STCs was reported as 3.1% in the tonsillar region (STC-1), 4% in the submandibular region (STC-2) and 1.5% in the carotid region (STC-3). The rate of our findings, using the same classification, showed that the STC-1 and STC-3 groups were higher, and the STC-2 group was lower than previous study. The proportional differences may be since the study population was not the same or the exclusion criteria were different. The calcifications do not usually affect prosthetic treatment, but these conditions that may require medical treatment should be taken into consideration and consulted with the physician. Carotid calcifications, in particular, should be carefully evaluated as they can be life-threatening (18).

The incidence of maxillary sinus opacities ranges from 0.6-7.1% in previous studies (2,8,11). In our study, this rate was found to be much higher (25.9%). This difference may be due to missed lesions in the other studies, because of the superposition of many anatomical structures in the maxillary sinus region. As a matter of fact, in the three-dimensional radiographic studies, high rates of maxillary sinus opacities have been reported, similar to the results of our study (19).

To the best of our knowledge, in only one study complete edentulous patients were examined for the presence of SBDs, and in that study, SBD (0.6%) was detected in only one patient (8). In our study, this rate was determined as 3.7%, and it was found to be compatible with the 3.5% rate in a tomographic study previously conducted in the general population (20).

Limitations of our study can be listed as evaluation of only two-dimensional images without clinical examination, difficulty in distinguishing some lesions with panoramic and the inability to make exact confirmation. In addition, the fact that panoramic radiography is a two-dimensional imaging method limits the detailed evaluation of some anatomical conditions or pathologies. In cases where a more detailed evaluation is required, a three-dimensional tomographic examination may be required (11). However,

three-dimensional imaging does not have a routine indication in every patient, so panoramic radiography images in which routine use is more appropriate were used in our study.

CONCLUSION

According to the results of this study, the rate of positive radiographic findings detected in digital panoramic images of completely edentulous patients was determined to be high. Some of these findings may affect the dental and medical condition of the patients. In particular, it was found that asymptomatic impacted teeth, residual roots, RL lesions, and foreign bodies, and even atrophy of the jaws, may require surgical intervention for both conventional complete dentures and implant-retained overdentures. Before successful prosthetic treatment, routine use and careful examination of panoramic radiographs in completely edentulous patients are very important.

Acknowledgements: We would like to thank Ismail Onur Sahin, DDS, DCLinDent, for the help of grammar check of this article.

Competing interests: The authors declare that they have no competing interest.

Financial Disclosure: There are no financial supports.

Ethical approval: The study was approved by the Medical Ethics Committee of Pamukkale University (IRB approval number: 60116787-020/26601).

REFERENCES

- Ahmad R, Affandi NF, Ayub NM, et al. The value of panoramic radiograph as a screening tool prior to complete denture construction: a retrospective study. *J Dent Indones* 2019;26:65-9.
- Jindal SK, Sheikh S, Kulkarni S, et al. Significance of pre-treatment panoramic radiographic assessment of edentulous patients--a survey. *Med Oral Patol Oral Cir Bucal* 2011;16:600-6.
- MacDonald D, Yu W. Incidental findings in a consecutive series of digital panoramic radiographs. *Imaging Sci Dent* 2020;50:53-64.
- Michaeli Y, Hermel J, Gizenfeld E, et al. Pathologic radiographic findings in clinically symptom-free edentulous subjects. *Oral Surg Oral Med Oral Pathol* 1968;26:27-30.
- Masood F, Robinson W, Beavers KS, et al. Findings from panoramic radiographs of the edentulous population and review of the literature. *Quintessence Int* 2007;38:298-305.
- Keur JJ, Campbell JPS, McCarthy JF, et al. Radiological findings in 1135 edentulous patients. *J Oral Rehabil* 1987;14:183-91.
- Bohay RN, Stephens RG, Kogon SL. A study of the impact of screening or selective radiography on the treatment and postdelivery outcome for edentulous patients. *Oral Surg Oral Med Oral Pathol Oral Radiol Endod* 1998;86:353-9.

8. Kratz RJ, Walton JN, MacEntee MI, et al. Panoramic radiographs made before complete removable dental prostheses fabrication: A retrospective study of clinical significance. *J Prosthet Dent* 2017;118:26-30.
9. Awad EA, Al-Dharrab A. Panoramic radiographic examination: a survey of 271 edentulous patients. *Int J Prosthodont* 2011;24:55-7.
10. Choi JW. Assessment of panoramic radiography as a national oral examination tool: Review of the literature. *Imaging Sci Dent* 2011;41:1-6.
11. Kose TE, Demirtas N, Karabas HC, et al. Evaluation of dental panoramic radiographic findings in edentulous jaws: A retrospective study of 743 patients "radiographic features in edentulous jaws." *J Adv Prosthodont* 2015;7:380-5.
12. Peker I, Toraman Alkurt M, Yıldırım Biçer Z. Evaluation of total and partial edentulous jaws using panoramic radiography. *Ata Diş Hek Fak Derg* 2015;24:241-5.
13. Macdonald D. How should dentists recognise calcified carotid artery atheromas?. *Gerodontology* 2013;30:169-70.
14. MacDonald D, Chan A, Harris A, et al. Diagnosis and management of calcified carotid artery atheroma: Dental perspectives. *Oral Surg Oral Med Oral Pathol Oral Radiol* 2012;114:533-47.
15. Sumer AP, Sumer M, Guler AU, et al. Panoramic radiographic examination of edentulous mouths. *Quintessence Int* 2007;38:399-403.
16. Jones JD, Seals RR, Schelb E. Panoramic radiographic examination of edentulous patients. *J Prosthet Dent* 1985;53:535-9.
17. Ozdede M, Akay G, Karadağ O, et al. Comparison of panoramic radiography and cone-beam computed tomography for the detection of tonsilloliths. *Med Princ Pract* 2020;29:279-84.
18. Ozdede M, Kayadugun A, Uçok O, et al. The assessment of maxillofacial soft tissue and intracranial calcifications via cone-beam computed tomography. *Curr Med Imaging Rev* 2018;14:798-806.
19. Amine K, Slaoui S, Kanice FZ, et al. Evaluation of maxillary sinus anatomical variations and lesions: A retrospective analysis using cone beam computed tomography. *J Stomatol Oral Maxillofac Surg*. Published Online: Jan 10, 2020.
20. Demiralp KO, Bayrak S, Kursun Cakmak ES. Assessment of stafne bone defects prevalence and characteristics by using cone beam computed tomography: a retrospective study. *Kirikkale Univ Tip Fak Derg* 2017;19:167-72.