

Bilateral choanal atresia in a 60-year-old man: A case report and review of the literature

 Erdem Mengi,  Bulent Topuz,  Fevzi Barlay,  Cuneyt Orhan Kara

Department of Otorhinolaryngology, Head and Neck Surgery, Pamukkale University Faculty of Medicine, Denizli, Turkey

ABSTRACT

Choanal atresia is a congenital condition referring to the blockage of the posterior nasal cavity. As bilateral choanal atresia (BCA) causes complete nasal congestion, it usually results in death due to asphyxia in the newborn if no emergency intervention is performed. Therefore, it is very rare to see a patient with BCA who has reached an advanced age. There are only 11 adult cases reported in the recent literature. Here, we report a case of a 60-year-old man diagnosed with BCA and we discuss the clinical presentation and treatment modalities with a review of the literature.

Keywords: Adult; bilateral; choanal atresia.

Cite this article as: Mengi E, Topuz B, Barlay F, Kara CO. Bilateral choanal atresia in a 60-year-old man: A case report and review of the literature. *North Clin Istanbul* 2021;8(5):525–528.

Choanal atresia is a congenital malformation of the nasal cavity characterized by the blockage of the connection between the nasal cavity and the nasopharynx. It occurs as a result of the maintenance of the nasobuccal membrane, which should be ruptured embryologically at about 7th week, remaining intact and close the choana [1]. It is more common in females and the average incidence is 1/8000 live births [2]. Approximately 60% of the cases are unilateral. Unilateral choanal atresia rarely leads to acute respiratory distress and therefore, it may not be recognized in the neonatal period. For this reason, the detection of unilateral choanal atresia in an adult patient is not an unusual situation. However, bilateral choanal atresia (BCA) is an emergency anomaly characterized by respiratory distress and cyanosis immediately after birth. Most of the BCA cases die due to asphyxia if no intervention is performed. This is the reason why the BCA is seen rarely in adults. Here, we present a 60-year-old patient with a complaint of nasal congestion for years and diagnosed with BCA. Written informed consent was obtained from the patient for this study.

CASE REPORT

A 60-year-old male patient presented to our clinic with a continuous nasal discharge and nasal congestion for years. The patient also had complaints of snoring and problems regarding the senses of smell and taste. His anamnesis revealed that he did not know any information about his birth or childhood. It was learned that he had undergone a nasal operation under local anesthesia about 40 years ago, but he had not had any advantages of that operation and had not applied to another physician. He had no history of head trauma or radiotherapy. In the endoscopic nasal examination of the patient, the nasal septum was seen to be located in the midline, the inferior and middle turbinates were atrophic, and bilateral posterior choanal plates were found to be atretic (Fig. 1). No additional congenital anomaly was found in the patient. In the computed tomography of the paranasal sinuses, osseous choanal atresia was detected on the right posterior nasal cavity and membranous choanal atresia on the left side (Fig. 2). Maxillary, ethmoid, and frontal



Received: February 10, 2020 *Accepted:* June 09, 2020 *Online:* August 09, 2020

Correspondence: Erdem MENGI, MD. Pamukkale Universitesi Tip Fakultesi, Kulak Burun Bogaz Hastaliklari Anabilim Dalı, Denizli, Turkey.
Tel: +90 258 296 60 00 e-mail: emengi@hotmail.com

© Copyright 2021 by Istanbul Provincial Directorate of Health - Available online at www.northclinist.com

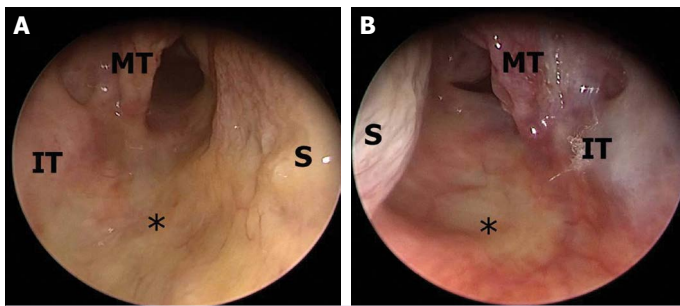


FIGURE 1. Preoperative endoscopic view of posterior choanae. **(A)** Right nasal passage. **(B)** Left nasal passage.

S: Septum; IT: Inferior turbinate; MT: Middle turbinate; *: Atretic choanae.

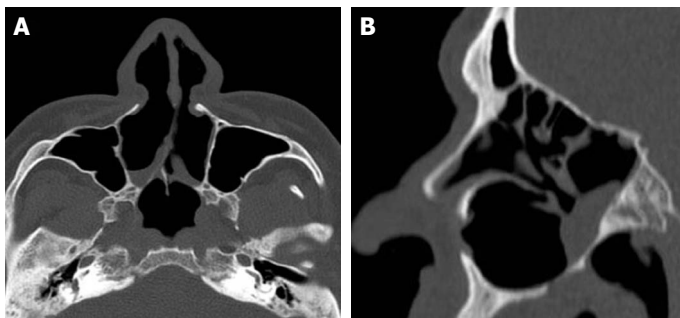


FIGURE 2. Bilateral choanal atresia is seen in computed tomography of the paranasal sinuses. **(A)** Axial section. **(B)** Sagittal section.

sinuses were found to be pneumatized whereas sphenoid sinuses were not developed.

Based on these findings, the patient underwent a transnasal endoscopic surgical treatment under general anesthesia. Endoscopic examination was performed via aspirator palpation and the choanal atresia area in the left nasal cavity was found to be membranous type. The mucosal membrane was perforated with a blade and the curved aspirator passed through the mouth was observed in the nasopharynx. Following the mucosal flap elevation, the surrounding bone tissue was removed using a curette and Kerrison punch forceps and the mucosae were laid toward the nasopharynx. After obtaining an adequate choanal opening on the left side, the right nasal cavity was operated. Choanal atresia on the right nasal cavity was observed to be mixed type. After the mucosal flaps were elevated, the medial pterygoid process and vomer were drilled out. Mucosae were laid down to obtain a choanal opening on the right side as well. For stenting, a six mm endotracheal tube was placed to the right nasal cavity in a way that the balloon would be on the choana and fixed to the membranous septum. No stent was

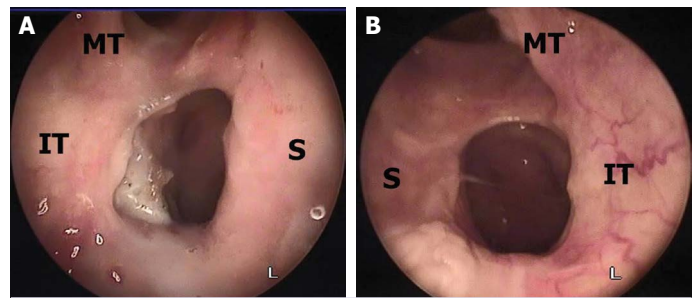


FIGURE 3. Postoperative endoscopic view of choanal opening. **(A)** Right nasal passage. **(B)** Left nasal passage.

S: Septum; IT: Inferior turbinate; MT: Middle turbinate.

placed on the left side. Nasal irrigation was started after the operation. The nasal stent was removed 3 weeks later and adequate openings were seen in the choanae (Fig. 3). The patient has been followed in our clinic for a year without any problem.

DISCUSSION

Breathing through the mouth is obstructed due to the fact that the epiglottis is very close to the soft palate and that tongue is in close contact with both the soft and hard palate in the neonatal period. Therefore, newborns necessarily do nasal breathing in the 1st month. Newborns learn to breathe through the mouth between 4 and 6 weeks at the earliest [3]. For this reason, in the newborn period, BCA causes complete nasal congestion that can be resulted in death due to asphyxia. In the light of this information, BCA is not included among the preliminary diagnoses in an adult patient applied with the complaint of nasal congestion.

There are only 11 adult BCA cases in the literature [1–11]. Cases and their characteristics are presented in Table 1. Adult BCA patients in the literature were diagnosed in the second decade in general. Only two cases were diagnosed above the age of 50 years [1, 3]. The patient presented in this study is the oldest case reported in the literature. In this study, the patient was learned to be operated under local anesthesia 40 years ago due to nasal congestion. No document related to the operation was available. Considering that nasal endoscopes were not used 40 years ago, choanal atresia might not have been detected during the operation. The patient stated that he had not benefited from the operation and had not re-applied to a physician. However, we know that choanal atresia can be seen as a complication of trauma and radiotherapy for nasopharyngeal carcinoma [12]. So in

TABLE 1. Reported cases of bilateral choanal atresia in adults

	Age/sex	Associated abnormalities	History of previous nasal surgery, radiotherapy or head trauma	Surgical approach	Adjuvant therapies (Stenting and mitomycin)	Restenosis
Panda et al. ^[2] (2004)	22-year old male	Telecanthus	No	TE	No. 6 ET for six weeks	–
El-Sawy et al. ^[5] (2006)	24-year old female	Hypogammaglobulinaemia	No	TE	None	+
Yasar et al. ^[3] (2007)	51-year old female	None	No	TE	No. 7.5 ET for seven days	–
Aksoy et al. ^[8] (2009)	23-year old female	None	No	TE	Topical Mitomycin-C	–
Tinoco et al. ^[7] (2010)	34-year old female	None	No	TE	None	–
Chaudhary et al. ^[11] (2010)	female	None	No	TE	Unspecified	–
Tatar et al. ^[11] (2012)	53-year old female	None	No	TE	No. 6 ET for six weeks	–
Bakir et al. ^[10] (2014)	21-year old male	None	No	TE	No.18 NC for three weeks	–
Verma et al. ^[9] (2016)	20-year old female	None	No	TE	None	–
Anajar et al. ^[4] (2017)	18-year old male	None	No	TE	None	–
Durmaz et al. ^[6] (2017)	23-year old female	Pycnodysostosis	No	TE	Unspecified	–
This report	60-year old male	None	Yes	TE	No. 6 ET for three weeks	–

TE: Transnasal endoscopic; ET: Endotracheal tube; NC: Nelaton catheter.

this case, we can not distinguish whether the BCA was congenital or acquired since the patient had previously undergone nasal surgery. The surgical trauma to the posterior choana might have caused acquired stenosis. But acquired choanal atresias are most likely fibrous membranous atresias. In our case, the choanal atresia was membranous type on the left nasal cavity and mixed type on the right side. So it is also possible that mixed type (right side) choanal atresia could be congenital, while membranous atresia (left side) could be acquired due to nasal surgery.

The majority of patients with choanal atresia have concomitant additional congenital anomalies. It is seen mostly as a part of Coloboma, heart defect, atresia choanae, retarded growth, genitourinary abnormalities, and ear anomalies Syndrome [12]. Some of the other accompanying diseases are Treacher Collins Syndrome, Crouzon Syndrome, chromosomal anomalies, craniosynostosis, and so on [4]. In a study by Burrow et al.

[13], additional anomalies have been reported in 46.8% of the cases with unilateral choanal atresia and in 98.4% of cases with BCA. The high rate in patients with BCA is particularly remarkable. The additional anomaly rate was seen to be much lower in adult choanal atresia cases in the literature. Only one patient was reported to have telecanthus [2], while one patient had hypogammaglobulinemia [5] and one patient had pycnodysostosis [6]. No additional anomaly was found in the other eight patients and our case. This finding suggested that the possibility of reaching an advanced age is much higher if no additional anomaly is accompanied in patients with BCA.

Various techniques, transpalatal and transnasal approach, in particular, have been identified in choanal atresia surgery. The endoscopic transnasal approach is the most preferred method in recent years because of its superiorities to other methods, such as being applicable in a short time, less hospitalization, and low complication rates. However, newborns with BCA more often

underwent transpalatal procedures because the small nasal cavity precludes the use of endoscopes and instruments. Moreddu et al. [14] reported that 70% of neonatal patients with BCA were operated with transpalatal approach. In adults, the transnasal endoscopic approach is a safe and efficient technique. All adult BCA cases in the literature were operated through the transnasal endoscopic approach. In the present case report, we also preferred the transnasal endoscopic approach and no technical complications were developed during and after surgery.

The use of postoperative stents in patients with choanal atresia is a controversial topic. Some investigators recommend the use of stents, however, some claim that stents lead to restenosis as they cause trauma. Postoperative stent use depends on the experience of the surgeon. The literature review revealed that the stent was used in most of the adult patients and the endotracheal tube was preferred as the stent. Aksoy et al. [8] reported that they used mitomycin C after the surgery. No adjuvant therapy was applied after the surgery in four patients. Among all cases, restenosis was reported in only one patient who did not receive any adjuvant therapy [5]. In the present case, we did not use the stent on the membranous side as we believed that sufficient choanal opening was obtained, but we preferred to use a six mm endotracheal tube on the osseous side. The adequate choanal opening was obtained on both sides in our case following the operation and no restenosis was observed during the follow-up.

Conclusion

BCA that is considered incompatible with life can be seen in adults. Although most BCA cases are congenital, acquired choanal atresia can also be seen as a complication of surgical trauma and radiotherapy. Therefore, this diagnosis should be considered in adult patients with bilateral nasal congestion and endoscopic nasal examinations should be performed for patients whose complaints do not regress through the routine treatment. The transnasal endoscopic technique is a safe and effective treatment approach for repair BCA.

Informed Consent: Written informed consent was obtained from the patient for the publication of the case report and the accompanying images.

Conflict of Interest: No conflict of interest was declared by the authors.

Financial Disclosure: The authors declared that this study has received no financial support.

Authorship Contributions: Concept – EM, BT, FB, COK; Design – EM, BT, FB, COK; Supervision – EM, BT, FB, COK; Materials – EM, BT; Data collection and/or processing – EM, FB; Analysis and/or interpretation – EM, FB; Literature review – EM, FB; Writing – EM, FB; Critical review – BT, COK.

REFERENCES

1. Tatar EÇ, Ozdek A, Akcan F, Korkmaz H. Bilateral congenital choanal atresia encountered in late adulthood. *J Laryngol Otol* 2012;126:949–51.
2. Panda NK, Simhadri S, Ghosh S. Bilateral choanal atresia in an adult: is it compatible with life? *J Laryngol Otol* 2004;118:244–5.
3. Yasar H, Ozkul MH. Bilateral congenital choanal atresia in a 51-year-old woman. *Am J Rhinol* 2007;21:716–8.
4. Anajar S, Hassnaoui J, Rouadi S, Abada R, Roubal M, Mahtar M. A rare case report of bilateral choanal atresia in an adult. *Int J Surg Case Rep* 2017;37:127–9.
5. El-Sawy H, Siddiq MA, Anbarasu A. Bilateral choanal atresia and paranasal sinus hypoplasia in an adult patient with hypogammaglobulinaemia. *Eur Arch Otorhinolaryngol* 2006;263:1136–8.
6. Durmaz CD, Taş V, Kocayay P, Fitöz ÖS, Onay H, Beton S, et al. Bilateral choanal atresia in an adult woman with pycnodysostosis. *Congenit Anom (Kyoto)* 2017;57:91–2.
7. Tinoco P, Pereira JCO, Filho RCL, Brito TSC, Pereira BM, Carrara VL, et al. Bilateral choanal atresia in 34 year old patients. *Intl Arch Otorhinolaryngol* 2010;14:481–4.
8. Aksoy F, Demirhan H, Yildirim YS, Ozturan O. Bilateral choanal atresia in an adult - management with mitomycin C and without stents: a case report. *Cases J* 2009;2:9307.
9. Verma RK, Lokesh P, Panda NK. Congenital bilateral adult choanal atresia undiagnosed until the second decade: How we did it. *Allergy Rhinol (Providence)* 2016;7:82–4.
10. Bakır S, Ozbay M, Kınış V, Gün R, Yorgancılar E. Bilateral choanal atresia in adults. *Kulak Burun Bogaz Ihtis Derg* 2014;24:114–7.
11. Chaudhary N, Jain A, Kapoor R, Motwani G. Bilateral complete choanal atresia in an adult woman--managed with nasal endoscopes. *J Indian Med Assoc* 2010;108:109–10.
12. Wang QY, Chai L, Wang SQ, Zhou SH, Lu YY. Repair of acquired posterior choanal stenosis and atresia by temperature-controlled radio frequency with the aid of an endoscope. *Arch Otolaryngol Head Neck Surg* 2009;135:462–6.
13. Burrow TA, Saal HM, de Alarcon A, Martin LJ, Cotton RT, Hopkin RJ. Characterization of congenital anomalies in individuals with choanal atresia. *Arch Otolaryngol Head Neck Surg* 2009;135:543–7.
14. Moreddu E, Rossi ME, Nicollas R, Triglia JM. Prognostic factors and management of patients with choanal atresia. *J Pediatr* 2019;204:234–9.e1.