

Laparoscopic Management of Bladder Injury During Total Laparoscopic Hysterectomy

Emre Mat,¹ Gazi Yıldız,¹ Gulfem Basol,¹ Didar Kurt,¹ Betül Kuru,¹
Elif Cansu Gundogdu,¹ Onder Sakin,¹ Umit Cabus,³
Pınar Yıldız,² Ahmet Kale¹

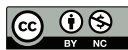¹Department of Obstetrics and Gynecology, Health Sciences University İstanbul Kartal Dr. Lütfi Kırdar City Hospital, İstanbul, Turkey
²Department of Obstetrics and Gynecology, Adatıp Kurtköy Hospital, İstanbul, Turkey
³Department of Obstetrics and Gynecology, Pamukkale University Faculty of Medicine, Denizli, Turkey

Submitted: 28.01.2021
Accepted: 22.02.2021

Correspondence: Emre Mat,
İstanbul Kartal Dr. Lütfi Kırdar Şehir Hastanesi, Kadın Hastalıkları ve Doğum Kliniği, İstanbul, Turkey
E-mail: emremat63@gmail.com



Keywords: Hysterectomy; injury; laparoscopy; repair; urinary bladder.



This work is licensed under a Creative Commons Attribution-NonCommercial 4.0 International License.

ABSTRACT

Objective: The rate of bladder injury during laparoscopic hysterectomy (LH) is three-fold higher than that of ureter injury and is an important problem for gynecologists. The aim of the present study was to present the results of laparoscopic repair of bladder injuries produced during LH procedure.

Methods: Patients who underwent LH for benign indications between November 2018 and January 2020 were evaluated retrospectively. Medical records of all patients with bladder injury were reviewed and their causes of injury, incidence, treatment and follow-up were evaluated.

Results: Eight patients were established to have bladder injury while undergoing LH. All bladder injuries were recognized during operation. Bladder injury occurred during laparoscopic sharp and blunt dissection of uterovesical area in seven patients and during suprapubic trochar insertion in one patient. All bladder injuries were repaired laparoscopically. No major complications were encountered during or after operation. Bladder catheters were removed 7–10 days after surgery.

Conclusion: It was demonstrated that laparoscopic repair of bladder injury, which is a feared complication of LH, can be carried out successfully by gynecologists experienced in endoscopic surgery.

INTRODUCTION

Hysterectomy is the most frequently carried out gynecologic surgery in women.^[1] Hysterectomy indications include uterine leiomyoma (51.4%), abnormal uterine bleeding (41.7%), endometriosis (30%), and prolapse of pelvic organs (18.2%).^[2,3] Hysterectomy can be performed vaginally, abdominally, laparoscopically, or with robot-assisted laparoscopy and their choice depends on many factors, that is, shape and size of the vagina and uterus; accessibility of the uterus (e.g., prolapse and pelvic adhesions); extent of extrauterine disease; surgeon experience and training; and available hospital surgical technology, whether the case is emergent or scheduled; and preference of patient.^[4]

At present, laparoscopic surgery has become the most frequently used approach in hysterectomy performed as outpatient procedure. Laparoscopic hysterectomy (LH) has advantages such as faster recovery, less blood loss,

and less pain.^[5] However, in LH, the probability of injury is higher than that in open hysterectomy.^[5] The female reproductive and urinary tracts are closely related embryologically and anatomically.^[6] Hence, the probability of bladder and ureter injury should be taken into consideration during gynecological surgery. Urinary tract injuries associated with gynecological surgery are divided into acute and chronic complications. Acute complications include ureter ligation, ureter, and bladder lacerations. As to chronic complications, they can arise days or weeks after surgical procedure and include vesicovaginal fistula, ureterovaginal fistula, and organ loss. The rate of urinary tract injuries is 0.3–1% during pelvic surgery, 0.33% in gynecological laparoscopic surgery, and 1.3% in LH.^[7–9] During LH, bladder injury occurs 3 times as common as ureter injuries.^[7,10] The aim of the present study was to evaluate laparoscopic repair of bladder injuries produced during LH and their results.

MATERIALS AND METHODS

Patients who underwent LH for benign gynecological indications between November 2018 and January 2020 were evaluated retrospectively and eight patients with bladder injury during LH were identified. The exclusion criteria were cerebrovascular disease, shock status, chronic obstructive pulmonary disease, chronic heart disease, and hemorrhagic disorder.

All patients gave written informed consent and local ethics committee approved the study number is 2020/514/181/8. After patients underwent general anesthesia, all patients were positioned in the lithotomy position. After bladder catheterization with a foley catheter, RUMI II manipulator was used for uterine manipulation and the vaginal cuff was closed with intracorporeal technique. All laparoscopic bladder repairs were performed by a single gynecologist surgeon experienced in laparoscopic hysterectomies.

Surgical techniques

Laparoscopic bladder repair was postponed until the completion of surgical procedures since additional injuries may also take place. Bladder injuries occurred during placement of suprapubic trocar and dissection of vesicouterine space

and all of them were detected intraoperatively and repaired by the same gynecologist. Bladder injuries were visualized laparoscopically and no ureteral injuries were detected (Fig. 1a). Additional trocar placement was not required during bladder repair. Since the size of bladder injury varied between 1.5 and 2 cm, bladder injuries were repaired by one-layer interrupted sutures with 4/0 Vicryl or 4/0 Polyglactin (Fig. 1b). Whether, there was any leak in sutures and was checked by filling the bladder with saline solution using foley catheter (Fig. 1c). In addition, suture line was examined with cystoscopy without inflating the bladder excessively. Hemostasis was performed and a drain was placed in abdomen. Foley catheter was kept in bladder for 7–10 days. As the size of bladder injury was <2 cm cystography was not performed after removing the catheter. After operation, all patients were followed for 3 months and urine analysis was performed and voiding symptoms were evaluated.

RESULTS

Eight patients who underwent laparoscopic repair of bladder injury intraperitoneally were included in this study. Demographic data and surgical information such as parity, age, body mass index, operation indications, and previous surgeries, were recorded (Table 1). We also noted foley cath-

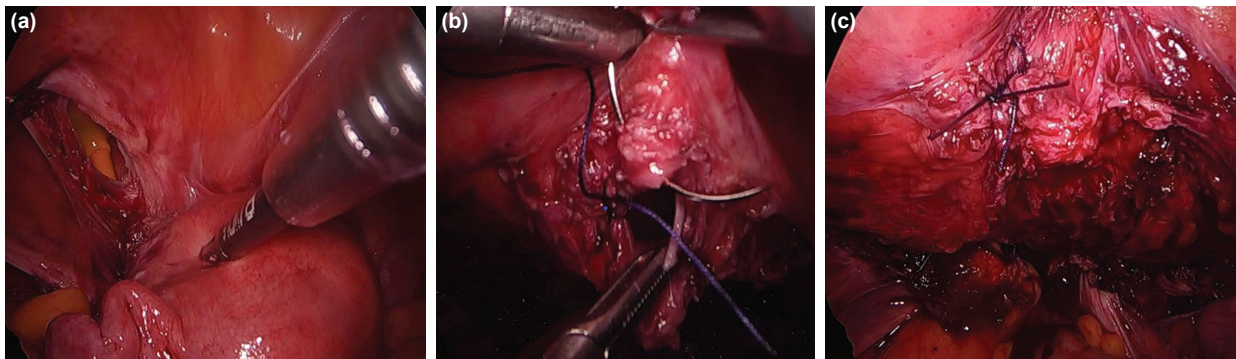


Figure 1. (a) Bladder injury. (b) Repair of bladder injury. (c) Control of leakage by saline solution.

Table 1. Demographic datas and surgical informations of patients

Age (mean±SD, years)	BMI (mean±SD, kg/m ²)	Previous C/S	Number of parity (median)	Indication for hysterectomy	Operation time (mean±SD, min)	Length of hospital stay (mean±SD, d)	Urinary catheterization time (mean±SD, d)	Postoperative complications
50	26	3	3	Leiomyoma	30	4	7	Dysuria
55	30	2	4	Leiomyoma	35	4	7	Nil
48	28	4	4	Endometriosis	28	3	8	Dysuria
56	35	2	5	Leiomyoma	32	4	9	Nil
72	28	2	5	Postmenopausal bleeding	30	5	9	Urinary track infection
58	32	3	3	Leiomyoma	33	5	10	Nil
45	27	3	3	Endometriosis	28	4	8	Urinary track infection
54	25	2	6	Leiomyoma	33	3	7	Nil

BMI: Body mass index; SD: Standard deviation.

eterization time and length of hospital stay. The most common hysterectomy indication was symptomatic fibroids and the second most common cause was endometriosis. Bladder injury occurred during sharp and blunt dissection of uterovesical space in seven patients and during suprapubic trocar insertion in one patient. All bladder injuries were recognized during operation and were repaired laparoscopically in the same session. Ureter injury occurred in none of the patients. No post-operative important complications such as hydronephrosis, organ loss, ureteral stricture, and urinary fistula were encountered. Afebrile urinary tract infection was seen in two patients 2 weeks after surgery and treated with fosfomycin tromethamine. In two patients with dysuria, complaints resolved on post-operative 2nd week. All patients undergoing laparoscopic bladder repair were invited to control visit on post-operative 2nd month and no complications were observed.

DISCUSSION

LH is a less invasive technique than abdominal hysterectomy. Various studies have demonstrated that LH is a safer and more effective surgical method than open surgery.^[11–13] LH has advantages over abdominal surgery such as lower rates of post-operative pain, need for analgesic drugs, and loss of blood and faster recovery, hence shorter duration of hospitalization.^[11–13]

Gynecological operations pose risk of the lower urinary tract injuries due to anatomic proximity of genital organs to ureter and bladder. Ever since the advent of hysterectomy, gynecological surgeons are concerned about urinary tract injuries. Although urinary tract injury is a rare surgical complication, it is thought that 52–82% of all iatrogenic urinary tract injuries are associated with gynecological surgery.^[14]

Although urinary tract injuries mostly lead to vesicovaginal fistula, genitourinary infection, and ureteric stenosis, they also have long-term complications such as kidney injury associated with hydronephrosis and organ loss.^[15] Such injuries commonly result in medico-legal cases.^[15] Although most of urinary tract injuries arise in patients without any known risk factor, there are pathological conditions which increase the risk of injury by disrupting urinary tract anatomy such as pelvic inflammatory disease, endometriosis, large pelvic masses, obesity, uterine leiomyoma, previous pelvic surgery, pelvic radiation, and urinary congenital abnormalities.^[16] In such clinical conditions, imaging with computed tomography and magnetic resonance imaging before operation may decrease the risk of injury in bladder.^[17] Accumulated data on hysterectomy indicate that as operator surgical volume increases, duration of operation is shortened and blood loss and risk of urinary tract injury decreases.^[18]

The recognition of bladder injuries during operation decreases the rate of morbidity and mortality. Unfortunately, solely 51.6% of bladder injuries are recognized during operation.^[19] In the present study, all bladder injuries were recognized and repaired during operation.

Parra reported the first case of laparoscopic repair of iatrogenic bladder injury in 1994.^[20] Dassel et al.^[21] stated that the incidence of urinary tract injuries during LH was 0.84. Walleinstein et al.^[23] noticed a lower rate of ureter (0.1% vs. 0.3%, $p < 0.001$) and bladder (1.0% vs. 1.3% $p < 0.0001$) injuries for high-volume surgeons during LH when compare to low-volume surgeons.^[22] Nevertheless, Boyd et al.^[23] reported that ureter injury rate was lower in high-volume surgeons (0.09% vs. 0.14%, $p = 0.005$), but did not observe a difference in bladder injury rates (0.78% vs. 0.79%, $p = 0.847$).

Thermal damage caused by harmonic scalpel, electrosurgery or other energy sources employed during laparoscopic surgery may bring about urinary tract injuries during or after operation.^[24,25] Thermal heat that may be produced while using these devices may vary between 2 and 22 mm in diameter. In various studies, the most common cause of bladder injuries was reported to be lysis of adhesions (23%); while that of ureter surgery was electrosurgery (33%).^[26]

In patients with the previous history of pelvic surgery, bladder injury may occur during placement of Veress needle and/or suprapubic trocar.^[27,28] Puncture injuries produced by Veress needle, sized 3–5 mm in diameter, may close spontaneously within 7–10 days with the help of decompression exerted on bladder by foley catheter.^[27] Larger or more irregular injuries are required to be closed by suturing through laparoscopic route and foley catheter should be kept in bladder for 4–10 days depending on the location and size of the injury.^[29] In the present study, bladder injury developed during the insertion of suprapubic trocar.

Wang et al.^[30] reported that the likelihood of bladder injury during LH increases in patients with history of two or more previous caesarian sections. Similarly, all of our patients with bladder damage had a history of two or more cesarean sections. In seven of these patients, bladder injury occurred during laparoscopic dissection of vesicouterine space. They all incurred bladder injuries varying between 1.5 and 2 cm, which were recognized and repaired intraoperatively.

Endometriosis disrupts pelvic anatomy associated with severe inflammation and adhesions and increases the risk of the lower urinary tract (bladder and ureter) by rendering surgical dissection during operation more difficult.^[31,32] However, it particularly poses a two-fold higher risk of ureteral injury.^[10] The benefit of prophylactic ureteral catheters in pelvic surgery is controversially. Many studies have demonstrated that ureter catheters decrease the probability of ureter injury during complex surgical procedures by facilitating the visualization of ureter.^[18,33] However, in other studies, it was stated that ureter catheter had no marked benefit and claimed that the main factor reducing injury in ureter during LH was increased surgical experience.^[34–36] In a randomized recent study with a large patient population, in the comparison between the group, which underwent prophylactic ureter catheter placement and the group that did not do so, the incidence of ureter

injury was found to be similar between two groups, but severe injuries were less common in the former group.^[34] In the present study, ureter catheter was used in no patient.

During operation, bladder may be filled back with urinary catheter and its boundaries may be delineated more clearly. In addition, placement of foley catheter in bladder may enable the early recognition of complications that may develop. Clinical findings of bladder injury are gas associated distension of bladder and bloody urine. If there is suspicion of injury, triple lumen catheter may be used and bladder can be filled with indigo carmine or methylene blue to visualize small tears with the aid of laparoscopy. Laparoscopic bladder repair is more cost effective than open surgery and enables faster return to daily activities but, it warrants more advanced surgical experience and skills.^[37]

Main limitations of the present study are that it is a retrospective analysis and includes a limited number of cases. Another limitation is the lack of control groups with open repair bladder injury. The present study indicates that laparoscopic repair of bladder injuries, which is a feared complication of LH, can be carried out by experienced gynecologists. Further randomized, prospective, and multicenter studies are required on the issue to support our results.

Ethics Committee Approval

This study approved by the Kartal Dr. Lütfi Kırdar City Hospital Clinical Research Ethics Committee (Date: 08.07.2020, Decision No: 2020/514/181/8).

Peer-review

Internally peer-reviewed.

Authorship Contributions

Concept: E.M., O.S., D.K., B.K.; Design: E.M., G.Y., E.C.G.; Supervision: E.M., B.K., A.K., U.C.; Materials: E.M., O.K.; Data: E.M., E.C.G.; Analysis: P.Y., G.B., A.K., B.K.; Literature search: P.Y., G.B., B.K., E.C.G.; Writing: E.M., G.Y., D.K., G.B., U.C.; Critical revision: A.K., G.Y., D.K., O.S., P.Y., U.C.

Conflict of Interest

None declared.

REFERENCES

1. Wu JM, Wechter ME, Geller EJ, Nguyen TV, Visco AG. Hysterectomy rates in the United States, 2003. *Obstet Gynecol* 2007;110:1091–5.
2. Whiteman MK, Hillis SD, Jamieson DJ, Morrow B, Podgornik MN, Brett KM, et al. Inpatient hysterectomy surveillance in the United States, 2000–2004. *Am J Obstet Gynecol* 2008;198:34.e1–7.
3. Wright JD, Herzog TJ, Tsui J, Ananth CV, Lewin SN, Lu YS, et al. Nationwide trends in the performance of inpatient hysterectomy in the United States. *Obstet Gynecol* 2013;122:233–41.
4. Committee on Gynecologic Practice. Committee opinion No 701: Choosing the route of hysterectomy for benign disease. *Obstet Gynecol* 2017;129:e155–9.
5. Aarts JW, Nieboer TE, Johnson N, Tavender E, Garry R, Mol BW, et al. Surgical approach to hysterectomy for benign gynaecological disease. *Cochrane Database Syst Rev* 2015;15:CD003677.
6. Chan JK, Morrow J, Manetta A. Prevention of ureteral injuries in gynecologic surgery. *Am J Obstet Gynecol* 2003;188:1273–7.
7. Teeluckdhar B, Gilmour D, Flowerdew G. Urinary tract injury at benign gynecologic surgery and the role of cystoscopy: A systematic review and meta-analysis. *Obstet Gynecol* 2015;126:1161–9.
8. Blackwell RH, Kirshenbaum EJ, Shah AS, Kuo PC, Gupta GN, Turk TM, et al. Complications of recognized and unrecognized iatrogenic ureteral injury at time of hysterectomy: A population based analysis. *J Urol* 2018;199:1540–5.
9. Lee JS, Choe JH, Lee HS, Seo JT. Urologic complications following obstetric and gynecologic surgery. *Korean J Urol* 2012;53:795–9.
10. Wong JM, Bortoletto P, Tolentino J, Jung MJ, Milad MP. Urinary tract injury in gynecologic laparoscopy for benign indication: A systematic review. *Obstet Gynecol* 2018;131:100–8.
11. Manolitsas TP, McCartney AJ. Total laparoscopic hysterectomy in the management of endometrial carcinoma. *J Am Assoc Gynecol Laparosc* 2002;9:54–62.
12. Obermair A, Manolitsas TP, Leung Y, Hammond I, McCartney AJ. Total laparoscopic hysterectomy versus total abdominal hysterectomy for obese women with endometrial cancer. *Int J Gynecol Cancer* 2005;15:319–24.
13. Scribner DR, Walker JL, Johnson GA, McMeekin SD, Gold MA, Mannel RS. Surgical management of early-stage endometrial cancer in the elderly: Is laparoscopy feasible? *Gynecol Oncol* 2001;83:563–8.
14. Burks FN, Santucci RA. Management of iatrogenic ureteral injury. *Ther Adv Urol* 2014;6:115–24.
15. Vilos GA, Dow DJ, Allen HH. Litigation following ureteral injuries associated with gynaecological surgery. *J SOGC* 1999;21:31–45.
16. Smith RB, Ehrlich RM, Taneja SS. Complications of Urologicsurgery: Prevention and Management. Philadelphia, PA: WB Saunders; 2001.
17. Tunitsky E, Citil A, Ayaz R, Esin S, Knee A, Harmanli O. Does surgical volume influence short-term outcomes of laparoscopic hysterectomy? *Am J Obstet Gynecol* 2010;203:24.e1–6.
18. Gilmour DT, Dwyer PL, Carey MP. Lower urinary tract injury during gynecologic surgery and its detection by intraoperative cystoscopy. *Obstet Gynecol* 1999;94:883–9.
19. Findley AD, Solnik MJ. Prevention and management of urologic injury during gynecologic laparoscopy. *Curr Opin Obstet Gynecol* 2016;28:323–8.
20. Parra RO. Laparoscopic repair of intraperitoneal bladder perforation. *J Urol* 1994;151:1003–5.
21. Dassel MW, Adelman MR, Sharp HT. Recognition and management of urologic injuries with laparoscopic hysterectomy. *Clin Obstet Gynecol* 2015;58:805–11.
22. Wallenstein MR, Ananth CV, Kim JH, Burke WM, Hershman DL, Lewin SN, et al. Effect of surgical volume on outcomes for laparoscopic hysterectomy for benign indications. *Obstet Gynecol* 2012;119:709–16.
23. Boyd L, Novetsky A, Curtin J. Effect of surgical volume on route of hysterectomy and short-term morbidity. *Obstet Gynecol* 2010;116:909–15.
24. Donnez O, Jadoul P, Squifflet J, Donnez J. A series of 3190 laparoscopic hysterectomies for benign disease from 1990 to 2006: Evaluation of complications compared with vaginal and abdominal procedures. *BJOG* 2009;116:492–500.
25. Léonard F, Fotso A, Borghese B, Chopin N, Foulot H, Chapron C, et al. Ureteral complications from laparoscopic hysterectomy indicated for benign uterine pathologies: A 13-year experience in a continuous series of 1300 patients. *Hum Reprod* 2007;22:2006–11.

26. Wong JM, Bortoletto P, Tolentino, Jung MJ, Milad MP. Urinary tract injury in gynecologic laparoscopy for benign indication: A systematic review. *Obstet Gynecol* 2018;131:100–8.
27. Georgy FM, Fetterman HH, Chefetz MD. Complication of laparoscopy: Two cases of perforated urinary bladder 1974;120:1121–2.
28. Homburg R, Segal T. Perforation of the urinary bladder by the laparoscope. *Am J Obstet Gynecol* 1978;130:597.
29. Poffenberger RJ. Laparoscopic repair of intraperitoneal bladder injury: A simple new technique. *Urology* 1996;47:248–9.
30. Wang L, Merkur H, Hardas G, Soo S, Lujic S. Laparoscopic hysterectomy in the presence of previous caesarean section: A review of one hundred forty-one cases in the Sydney West Advanced Pelvic Surgery Unit. *J Minim Invasive Gynecol* 2010;17:186–91.
31. Tan-Kim J, Menefee SA, Reinsch CS, Bechuk J, Kennedy JS, Whitcomb EL. Laparoscopic hysterectomy and urinary tract injury: experience in a health maintenance organization. *J Minim Invasive Gynecol* 2015;22:1278–86.
32. Adelman MR, Bardsley TR, Sharp HT. Urinary tract injuries in laparoscopic hysterectomy: A systematic review. *J Minim Invasive Gynecol* 2014;21:558–66.
33. Kuno K, Menzin A, Kauder HH, Sion C, Gal D. Prophylactic ureteral catheterization in gynecologic surgery. *Urology* 1998;52:1004–8.
34. Chou MT, Wang CJ, Lien RC. Prophylactic ureteral catheterization in gynecologic surgery: A 12-year randomized trial in a community hospital. *Int Urogynecol J* 2009;20:689–93.
35. Wu MP, Lin YS, Chou CY. Major complications of operative gynecologic laparoscopy in southern Taiwan. *J Am Assoc Gynecol Laparosc* 2001;8:61–7.
36. Kreiker GL, Bertoldi A, Larcher JS, Orrico GR, Chapron C. Prospective evaluation of the learning curve of laparoscopic-assisted vaginal hysterectomy in a university hospital. *J Am Assoc Gynecol Laparosc* 2004;11:229–35.
37. Aydin C, Mercimek MN. Laparoscopic management of bladder injury during total laparoscopic hysterectomy. *Int J Clin Pract* 2020;74:e13507.

Total Laparoskopik Histerektomi Sırasında Mesane Yaralanmasının Laparoskopik Yönetimi

Amaç: Laparoskopik histerektomi (LH) sırasında mesane yaralanması, üreter yaralanmasından yaklaşık olarak üç kat daha fazla görülmektedir ve jinekologlar için hala önemli bir problem oluşturmaktadır. Çalışmamızın amacı, laparoskopik histerektomi sırasında oluşan mesane yaralanmalarının laparoskopik olarak onarılmasının sonuçlarını sunmaktır.

Gereç ve Yöntem: Kasım 2018 ile Ocak 2020 arasında benign jinekolojik nedenlerle LH yapılan hastalar geriye dönük olarak incelendi. Mesane yaralanması izlenen tüm hastaların tıbbi kayıtları incelendi, yaralanma nedenleri, insidansı, tedavi ve takipleri değerlendirildi.

Bulgular: Laparoskopik histerektomi sırasında mesane yaralanması olan sekiz hasta saptandı. Mesane yaralanmalarının hepsi operasyon sırasında farkedildi. Yedi hastada utero–vezikal alanın laparoskopik olarak keskin ve künt diseksiyonu sırasında, bir hastada da suprapubik trokar girişi sırasında mesane hasarı olduğu izlendi. Mesane hasarlarının tümü laparoskopik olarak onarıldı. Cerrahi sırasında ve sonrasında hiçbir hastada majör bir komplikasyon izlenmedi. Mesane katateri cerrahiden 7–10 gün sonra çıkarıldı.

Sonuç: Laparoskopik histerektominin korkulan bir komplikasyonu olan mesane yaralanmalarının laparoskopik onarımı, endoskopik cerrahide deneyimli bir jinekologlar tarafından da başarı ile yapılabileceği gösterilmiştir.

Anahtar Sözcükler: Histerektomi; laparaskopi; mesane; onarım; yaralanma.