

## Comparison of traction table and supine position without traction in double axis femoral nailing of intertrochanteric fracture

### *İntertrokanterik kırıklarda çift eksenli femoral çivilemede traksiyon masası ve traksiyonsuz supin pozisyonunun karşılaştırılması*

Ali Çağdaş Yörükoğlu, Ahmet Nadir Aydemir, Mehmet Yücens, Özgür Yiğiter, Ahmet Esat Kiter, Nusret Ök

Gönderilme tarihi:08.02.2019

Kabul tarihi:26.02.2019

#### Abstract

**Purpose:** The aim of this study was to compare the traction table and supine position without traction table in double axis femoral nailing of intertrochanteric fractures in terms of reduction quality and complication rates.

**Material and Method:** Sixty-three patients with a mean age of 68.54±16.42 (29-97) were retrospectively analyzed. 42 patients were operated without the traction table, 21 patients were operated with the traction table. Collodiaphyseal angles and Baumgartner reduction criteria were used for radiologic evaluation. The union time of the fractures, complications, and nonunion cases were assessed.

**Results:** The restoration of collodiaphyseal angle was better in the group using the traction table, the reduction quality could not be restored well in the group without the traction table ( $p<0.05$ ). The mean union time was calculated as 3.2±2.2 months in patients operated with the traction table while in patients who were operated without a traction table was calculated as 4.26±2.23 months ( $p>0.05$ ). Cut-out and nonunion complications were more common in the group operated without traction table. Increasing difference of the collodiaphyseal angle was found to be correlated with the complication rates and union time.

**Conclusion:** Better reduction was achieved in the patient group that operation performed using the traction table and the complication rates were low in this group. Operation with the traction table should be the first choice for intertrochanteric fractures. The supine position without traction table may be a preferable treatment method for intertrochanteric fractures when the traction table is not available.

**Key Words:** Supin position, intertrochanteric fractures, traction table, collodiaphyseal angle.

Yörükoğlu AÇ, Aydemir AN, Yücens M, Yiğiter Ö, Kiter AE, Ök N. Comparison of Traction Table and Supine Position Without Traction in Double Axis Femoral Nailing of Intertrochanteric Fracture. Pam Med J 2019;12:315-320.

#### Özet

**Amaç:** Bu çalışmanın amacı, intertrokanterik kırıkların supin pozisyonunda traksiyon masası kullanılarak ve kullanılmadan çift eksenli femur çivisi ile tedavisinde redüksiyon kalitesi ve komplikasyon oranları açısından karşılaştırılmasıdır.

**Gereç Yöntem:** Ortalama yaşı 68,54±16,42 (29-97) olan 60 hasta retrospektif olarak incelendi. 42 hasta traksiyon masası olmadan ameliyat edildi, 21 hasta traksiyon masasıyla ameliyat edildi. Radyolojik değerlendirme için kollodiyafizel açıları ve Baumgartner redüksiyon kriterleri kullanıldı. Kırıkların kaynama süresi, komplikasyonlar ve kaynamama vakaları değerlendirildi.

**Bulgular:** Kollodiyafizel açı restorasyonu, traksiyon masasının kullanıldığı grupta daha iyiydi, traksiyon masasının olmadığı grupta iyi bir redüksiyon kalitesi elde edilemedi ( $p<0,05$ ). Traksiyon masası ile ameliyat edilen hastalarda ortalama kaynama süresi 3,2±2,2 ay iken traksiyon masası olmadan ameliyat edilen hastalarda 4,26±2,23 ay olarak hesaplandı ( $p>0,05$ ). Traksiyon masası olmadan opere edilen grupta vida penetrasyonu ve kaynamama komplikasyonları daha fazlaydı. Kollodiyafizel açı farkının artmasının komplikasyon oranları ve kaynama süresi ile korele olduğu saptandı.

**Sonuç:** Sonuç olarak, traksiyon masası kullanılarak opere edilen hasta grubunda daha iyi redüksiyon elde edildiği ve komplikasyon oranlarının bu grupta düşük olduğu görüldü. İntertrokanterik kırıklar için traksiyon masası ile operasyon ilk seçenek olmalıdır. Traksiyon masasız supin pozisyonu traksiyon masası mevcut olmadığında intertrokanterik kırıklar için tercih edilen bir tedavi yöntemi olabilir.

Ali Çağdaş Yörükoğlu, MD., Assistant Professor. Pamukkale University, Faculty of Medicine, Department of Orthopedics and Traumatology. DENİZLİ, e-mail: alicagdasyorukoglu@gmail.com (orcid.org/0000-0001-8903-3578) (Sorumlu Yazar)

Ahmet Nadir Aydemir, MD., Assistant Professor. Pamukkale University, Faculty of Medicine, Department of Orthopedics and Traumatology. DENİZLİ, e-mail: ahmetnadiraydemir@gmail.com (orcid.org/0000-0002-3095-4935)

Mehmet Yücens, MD., Assistant Professor. Pamukkale University, Faculty of Medicine, Department of Orthopedics and Traumatology. DENİZLİ, e-mail: aflyucens@yahoo.com (orcid.org/0000-0001-6924-6613)

Özgür Yiğiter, M.D., Denizli Government Hospital, Clinic of Orthopedics and Traumatology, DENİZLİ, e-mail: dryigiter77@yahoo.com (orcid.org/0000-0002-3365-5164)

Ahmet Esat Kiter, M.D., Professor. Pamukkale University, Faculty of Medicine, Department of Orthopedics and Traumatology. DENİZLİ, e-mail: esatkiter@gmail.com (orcid.org/0000-0002-5061-6669)

Nusret Ök, M.D., Assistant Professor. Pamukkale University, Faculty of Medicine, Department of Orthopedics and Traumatology. DENİZLİ, e-mail: oknusret@gmail.com (orcid.org/0000-0002-3365-5164)

**Anahtar Kelimeler:** Supin pozisyonu, intertrokanterik kırıklar, traksiyon masası, kolladiyafizer açısı.

Yörükoğlu AÇ, Aydemir AN, Yücens M, Yiğiter Ö, Kiter AE, Ök N. İntertrokanterik kırıklarda çift eksenli femoral çivilemede traksiyon masası ve traksiyonsuz supin pozisyonunun karşılaştırılması. Pam Tıp Derg 2019;12:315-320.

## Introduction

Proximal femur fractures are usually operated with the use of traction table in the supine position [1]. Complications such as erectile dysfunction, pudendal nerve damage [2], intact leg compartment syndrome [3] and peroneal nerve damage have also been reported due to the use of the traction table [4]. In addition to this, setting up the patient with the traction table causes significant delay to the beginning of the operation and prolongs the time under anesthesia [5]. Supine position without traction table may be preferred if patient also have cervical spine injury, ipsilateral lower extremity fracture and severe pulmonary compromise [6, 7]. Previous studies have reported that intramedullary fixation of proximal femoral fractures can be performed in the lateral decubitus position and in a publication it is described for subtrochanteric fractures in the prone position [8] without a traction table. The feasibility of nailing of intertrochanteric fractures in the supine position has not been discussed previously.

In this study, it was aimed to make a contribution to the literature by comparing both operation techniques; in the supine position with the knees flexed without the traction table and conventional surgery with the traction table in the intertrochanteric femur fractures in terms of fracture reduction quality and complication rates.

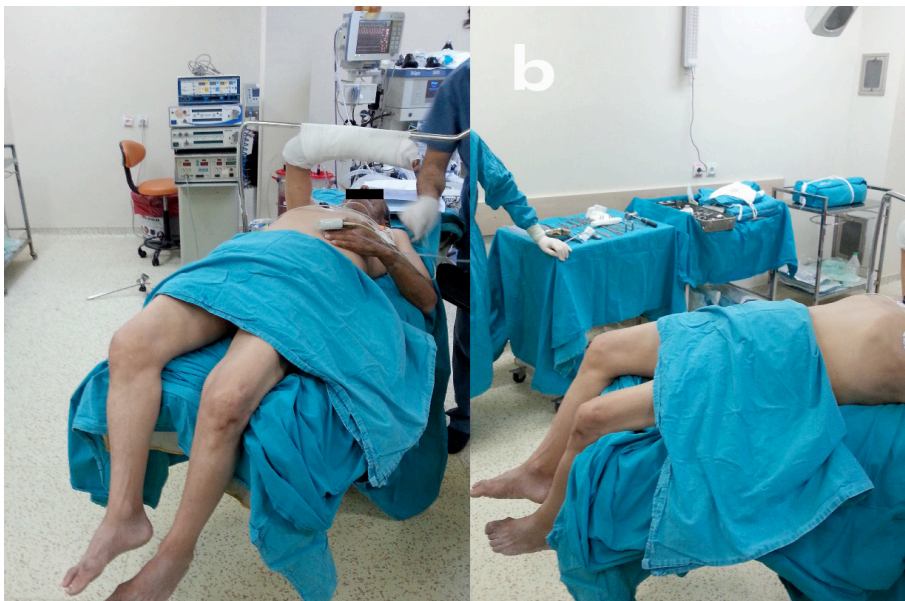## Material and method

Sixty-three patients with a mean age of  $68.54 \pm 16.42$  (29-97) who were admitted to two separate centers with intertrochanteric femur fractures between 2010 and 2014 were retrospectively analyzed. The mean follow-up time was  $52.21 \pm 14.05$  (35-105) months. 36 patients were male and 27 patients were female. 37 patients had fracture on the right side, 26 patients had fracture on the left side. (Table 1). Fractures were classified according to the Arbeitsgemeinschaft für Osteosynthesefragen (AO) classification. The study protocol was approved by the Ethics Committee. 42 patients

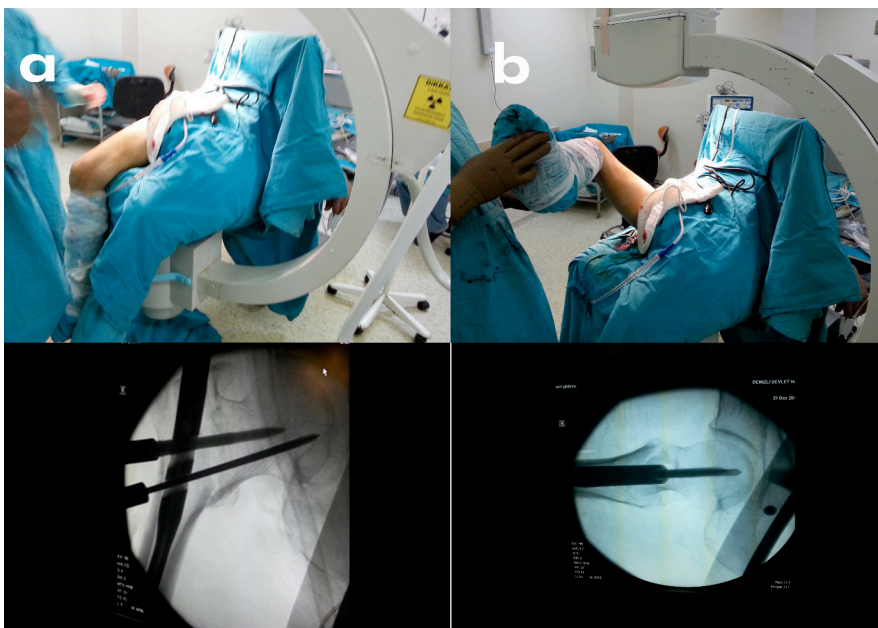
were operated without the use of a traction table at the first center in the supine position using a conventional fracture table. The operation of 21 patients was performed in the second center using the same implant The Veronail® (Veronail Trochanteric System, Orthofix, Bussolengo, Italy) with the help of the traction table. Implant allows using two parallel sliding cephalic screws or two convergent fixed screws for fixation of the neck of the femur. Patients who were operated without using a traction table, were placed to the conventional radiolucent surgical table in the supine position with 70-degree flexion of their knees and the proximal portion of the tibia were in contact with the distal end of the table. Distal part of the cruris was allowed to swing to the bottom of the table. By this way, the patient's lower extremity performed gravity assisted proximal femoral traction with the cruris weight (Figure 1). Slight internal and external rotation movements were manually applied to the lower extremity under fluoroscopic control and guide wire fixation was performed when best reduction was obtained. After confirmation that the guide wires were inside the femoral neck in anteroposterior position, the leg and arm was positioned for lateral view of femoral neck, to confirm that the guide wires were in the center of the femoral neck on the lateral plane. (Figure 2) After insertion of the appropriate length of the lag screws to the femoral neck under anteroposterior position, frog-leg position images were taken to evaluate the screw position in the femoral neck (Figure 2). In the conventional traction table group, the operation was started after reduction of fractures under C-arm. Follow-up was scheduled at 4, 6 weeks and 6, 12 months after the operation. The reduction qualities were assessed by calculating the collodiaphyseal angles(CDA) of the operated side and the healthy side of each patient. Baumgartner reduction criteria were used for radiologic evaluation [9]. The union time of the fractures and complications such as cut-out, intra-articular migration of the screw, fixation loss, implant-related fractures and nonunion were assessed. Patients who died in the early period after surgery were noted.

**Table 1.** Demographic characteristics of the patients

		Usage of traction table		p
		No n=42	Yes n=21	
Gender	Male	30 (71.42%)	6 (28.57%)	>0.05
	Female	12 (28.58%)	15 (71.42%)	
AO	1	18 (42.9%)	11 (52.4%)	>0.05
	2	13 (31.0%)	4 (19.1%)	
	3	11 (26.2%)	6 (28.6%)	
Divergent Screw		33 (78.57%)	13 (61.9%)	
Convergent screw		9 (21.43%)	8 (38.1%)	



**Figure 1.** Positioning the patient in the supine position with the knees flexed



**Figure 2.** Final confirmation of the lag screw positions: anteroposterior image and frog leg position images were taken to evaluate lateral positions of the the screws in the femoral neck

## Statistical analyses

SPSS 17.0 was used in the evaluation of the data. Descriptive statistics were used for categorical variables, number, percentage; arithmetic mean and standard deviation for continuous variables. Chi-square test was used to compare categorical variables. When the parametric test assumptions were provided in comparing the independent groups, the difference between Two Means Test was used for significance; Mann-Whitney U test was used when parametric test assumptions were not provided. Spearman correlation test was used for correlation. Statistical significance level ( $p$ ) was accepted as  $<0.05$ .

## Results

The mean age of the patients who were operated without the use of a traction table was  $65.6\pm 16.6$ , and the mean age of the patients who were operated on the traction table was  $74.24\pm 14.9$ . There was no statistically significant difference between the groups in terms of age

distribution and AO classification of fractures ( $p>0.05$ ). In the group with the traction table, the average CDA of the healthy side was  $131.6\pm 4.5$ , while the average postoperative CDA of the fractured side was  $129.9\pm 5.7$  ( $p>0.05$ ). In the group without the use of the traction table, the average CDA of the healthy side was  $130.6\pm 6.3$  while CDA of the operated side was  $121.2\pm 11.5$  ( $p<0.05$ ) (Table 2). The mean union time was calculated as  $3.2\pm 2.2$  months in patients operated with the traction table while in patients who were operated without a traction table it was calculated as  $4.26\pm 2.23$  months ( $p>0.05$ ). According to the Baumgartner classification, both methods gave similar results ( $p>0.05$ ) (Table 3). Complications of both methods are given in Table 3. There was a moderate correlation between CDA difference and complication rate  $r=0.559$   $p<0.001$ . Low degree of + correlation was found between the CDA difference and the union time  $p=0.01$   $r=0.359$ . A positive moderate correlation was found between angular difference and Cut-out complication  $r=0.401$   $p=0.001$ .

**Table 2.** The collodiaphyseal angle of the patients.

	Collodiaphyseal angle		
	Operated side	Healthy side	$p$
Traction table	$129.9\pm 5.7$	$131.6\pm 4.5$	$>0.05$
Without Traction table	$121.2\pm 11.5$	$130\pm 6.3$	$<0.05$

**Table 3.** The complications and Boumgartner classification comparing both methods.

Complications	With Traction Table	Without Traction table	$p$
Cephalic screw malposition	-	1(2.4%)	
Implant fracture	1(4.8%)	-	
Periprosthetic fracture	1(4.8%)	-	$>0.05$
Ex	3(14.3%)	1(2.4%)	
Nonunion	2(9.5%)	8(19.0%)	
Cut out	1(4.8%)	5(11.9%)	
<b>Boumgartner classification</b>			
Good	13(61.9%)	23(54.42%)	
Moderate	4(19%)	10(23.8%)	$>0.05$
Bad	4(19%)	9(21.4%)	

## Discussion

The patients operated with traction table had better restoration of CDA compared to those without traction table. Cut-out and nonunion complications were more common in patients with an increased angle difference. The use of the traction table did not have a significant effect on union time but the rate of nonunion was higher in the group without traction table. In terms of complications, better results were obtained in the group with the traction table.

The feasibility of these operations without using the traction table has been reported in previous studies. Researchers who used the manual traction method with the lateral decubitus position due to the absence of a traction table in their centers reported that, this method did not completely obviate the tip-apex distance and ideal quadrant placement of the screw [10]. Şahin et al. compared the patients who were operated with traction table with those manual traction applied in the supine position in unstable intertrochanteric femur fractures and no significant difference was observed between the groups when the surgical or postoperative parameters were evaluated [5]. In another study, conducted by Sonmez et al. compared the lateral decubitus position with patients treated at the traction table, there was a significant difference on the CDA change in the group without traction table and they found that the CDA was better restored in the traction table group. However, they didn't find any statistically significant difference according to the Baumgartner criteria [1]. In our study, similarly, CDA was better restored on the traction table but in terms of Baumgartner classification, both methods gave similar results. We observed that the increasing difference of the CDA was correlated with the complication rates and union time. The characteristic displacement in intertrochanteric fractures is the shortening and external rotation of the distal fragment. The head and neck fragment displaces into varus and posterior position. Besides this, operating in supine position has some advantageous; the contact of the proximal tibia to the operation table with the flexion of the knees, allows for the self-traction of the fracture. Contact of the hip to the operation table reducing posterior angulation and rotation of the proximal part, which prevents neck shaft

overlapping [11]. Although the traction table provides a good correction in the fracture line and facilitates surgery, it may not be available in every clinic or when the patient has additional injuries, the surgeon must be able to perform the operation in the supine or lateral decubitus position [12]. Kumar and Chadha's case series of 328 patients without using a traction table 97% of cases showed good and moderate reduction quality. In our own series, this ratio was found to be 77% according to Baumgartner criteria. The most common cause of cut-out is failure to provide anatomic reduction and lack of optimal lag screw position [13, 14]. In the present study, the CDA of femoral neck was not fully achieved in the supine position and that the cutout and nonunion was more observed in the group without the use of the traction table. Surgery with the traction table, cause delay to start operation than those not used, for reasons such as the setup of the traction table, more detailed surgical cover and obtaining fracture reduction [1, 8]. In elderly patients with comorbidity, prolonged anesthesia has been reported to cause complications, which increase morbidity and mortality [15]. In this study, in the postoperative period, the number of ex-patients was found to be 14.3% in the group of patients operated with traction table and 2.4% in the group of patients without traction table. The short duration of surgery under anesthesia and patients' exposure to anesthetic drugs for less time can be one of the reason for this difference.

This study has some limitations. First, it has been designed retrospectively and the operations carried out in two different institutions with different surgeons. Therefore, some differences between the groups, the operating room, physical differences such as C-arm quality; and personal differences such as surgical experience have been ignored.

In conclusion, better reduction was achieved in the patient group that operation performed using the traction table and the complication rates were low in this group. Operation with the traction table should be the first choice for intertrochanteric fractures. The supine position without traction table may be a preferable treatment method for intertrochanteric fractures when the traction table is not available.

## References

1. Sonmez MM, Camur S, Erturer E, Ugurlar M, Kara A, Ozturk I. Strategies for proximal femoral nailing of unstable intertrochanteric fractures: Lateral decubitus position or traction table. *J Am Acad Orthop Surg* 2017;25:37-44. <https://dx.doi.org/10.5435/JAAOS-D-15-00691>
2. Brumback RJ, Ellison TS, Molligan H, Molligan DJ, Mahaffey S, Schmidhauser C. Pudendal nerve palsy complicating intramedullary nailing of the femur. *J Bone Joint Surg Am* 1992;74:1450-1455
3. Anglen J, Banovetz J. Compartment syndrome in the well leg resulting from fracture-table positioning. *Clin Orthop Relat Res* 1994;301:239-42. <https://dx.doi.org/10.1097/00003086-199404000-00037>
4. Flierl MA, Stahel PF, Hak DJ, Morgan SJ, Smith WR. Traction table-related complications in orthopaedic surgery. *J Am Acad Orthop Surg* 2010;18:668-675. <https://dx.doi.org/18/11/668> [pii]
5. Şahin E, Songür M, Kalem M, et al. Traction table versus manual traction in the intramedullary nailing of unstable intertrochanteric fractures: A prospective randomized trial. *Injury* 2016;47:1547-1554. doi: 10.1016/j.injury.2016.04
6. Johnson KD, Greenberg M. Comminuted femoral shaft fractures. *Orthop Clin North Am* 1987;18:133-147.
7. Aiyer S, Jagyasi J, Argekar H, Sharan S, Dasgupta B. Closed antegrade interlocked nailing of femoral shaft fractures operated up to 2 weeks postinjury in the absence of a fracture table or C-arm. *J Trauma Injury, Infection, and Critical Care* 2006;61:457-160. <https://dx.doi.org/10.1097/01.ta.0000210269.05305.75>
8. Zhao Z, Song F, Zhu J, et al. Prone positioning for intramedullary nailing of subtrochanteric fractures, the techniques of intraoperative fluoroscopy and reduction: A technique note. *Injury* 2017;48:2354-2359. <https://dx.doi.org/10.1016/j.injury.2017.08.025>
9. Baumgaertner MR, Curtin SL, Lindskog DM, Keggi JM. The value of the tip-apex distance in predicting failure of fixation of peritrochanteric fractures of the hip. *J Bone Joint Surg Am* 2019;77:1058-1064.
10. Turgut A, Kalenderer Ö, Günaydin B, Önvural B, Karapinar L, Ağus H. Fixation of intertrochanteric femur fractures using Proximal Femoral Nail Antirotation (PFNA) in the lateral decubitus position without a traction table. *Acta Orthop Traumatol Turc* 2014;48:513-520. <https://dx.doi.org/10.3944/AOTT.2014.14.0098>
11. Carr JB. The anterior and medial reduction of intertrochanteric fractures: A simple method to obtain a stable reduction. *J Orthop Trauma* 2007;21:485-489. <https://dx.doi.org/10.1097/BOT.0b013e31804797cf>
12. Kumar S, Chadha GN. Dynamic hip screw fixation of intertrochanteric fractures without using traction table. *Acta Orthop Belg* 2016;82:346-350.
13. Bojan AJ, Beimel C, Taglang G, Collin D, Ekholm C, Jönsson A. Critical factors in cut-out complication after gamma nail treatment of proximal femoral fractures. *BMC Musculoskelet Disord* 2013;14:1. <https://dx.doi.org/10.1186/1471-2474-14-1>
14. Ballal MSG, Emms N, Thomas G. Proximal femoral nail failures in extracapsular fractures of the hip. *J Orthop Surg (Hong Kong)* 2008;16:146-149. <https://dx.doi.org/10.1177/230949900801600203>
15. Jaffer AK, Barsoum WK, Krebs V, Hurbanek JG, Morra N, Brotman DJ. Duration of anesthesia and venous thromboembolism after hip and knee arthroplasty. *Mayo Clin Proc* 2005;80:732-738. [https://dx.doi.org/10.1016/S0025-6196\(11\)61526-7](https://dx.doi.org/10.1016/S0025-6196(11)61526-7)