

## Bilateral Synovial Chondromatosis of Knee Joint in a Patient with Rheumatoid Arthritis

### Her İki Diz Eklemine Sinoviyal Kondromatozisi Olan Romatoid Artritli Bir Hasta

<sup>ID</sup> Hakan ALKAN<sup>a</sup>, <sup>ID</sup> Ayşe SARSAN<sup>a</sup>, <sup>ID</sup> Necmettin YILDIZ<sup>a</sup>, <sup>ID</sup> Harun Reşit GÜNGÖR<sup>b</sup>

<sup>a</sup>Department of Physical Medicine and Rehabilitation, Pamukkale University Faculty of Medicine, Denizli, TURKEY

<sup>b</sup>Department of Orthopaedics and Traumatology, Pamukkale University Faculty of Medicine, Denizli, TURKEY

**ABSTRACT** Synovial chondromatosis (SC) is an uncommon disorder of unknown etiology and is characterized by the presence of multiple cartilaginous nodules in the joint synovium or cavity. In this case presentation, we aimed to present a rare case of bilateral knee chondromatosis with different phases of Milgram's classification secondary to rheumatoid arthritis (RA). A 47 years-old female patient, diagnosed with RA for 25 years, was presented with a history of 5 years knee pain when she was referred to our hospital. She had tenderness in her both knees with effusion and limited knee range-of-motion. Bilateral knee radiographs showed widespread multiple calcified loose bodies with variable in size, joint space narrowing and osteoporosis. Moreover on bilateral knee magnetic resonance imaging, multiple hypointense and few hyperintense calcified nodules distributed throughout the joint with lobular contours were observed on T1-weighted images and peripheral hypointense central hyperintense multiple nodular lesions with an associated effusion were detected in the same sections of T2-weighted images. The diagnosis was confirmed by pathology following arthroscopic biopsy. SC should be considered in the differential diagnosis of patients presenting with a persistent arthritis in patients with RA.

**ÖZET** Sinoviyal kondromatozis (SK), etiolojisi bilinmeyen nadir görülen bir hastalıktır ve eklem sinoviyumu veya boşluğunda multipl kırkardak nodüllerinin varlığı ile karakterizedir. Bu olgu sunumunda, romatoid artrit (RA) sekonder Milgram'ın sınıflamasının farklı fazlarında olan, nadir bir bilateral diz kondromatozisi olgusunu sunmayı amaçladık. Yirmi beş yıldır RA tanısı olan 47 yaşındaki kadın hasta, hastanemize sevk edildiğinde 5 yıllık diz ağrısı öyküsü mevcuttu. Her iki diz eklemine hassasiyet ile birlikte efüzyon ve hareket kısıtlılığı vardı. Mukayeseli diz grafilerinde ise değişen boyutlarda, yaygın, multipl, kalsifiye eklem fareleri, eklem aralığında daralma ve osteoporoz görüldü. Ayrıca her iki diz manyetik rezonans görüntülemesinde, T1 ağırlıklı serilerde multipl hipointens ve az sayıda hiperintens kalsifiye lobüler konturlu nodülün eklem boşluğuna dağılmış olduğu gözlemlendi ve aynı kesitlerin T2 ağırlıklı serilerinde eşlik eden eklem efüzyonu ile birlikte periferi hipointens, santrali hiperintens multipl nodüler lezyonlar saptandı. Tanı, artroskopik biyopsiyi takiben patoloji ile doğrulandı. SK, inatçı aritri bulunan RA'lı hastaların ayırıcı tanısında dikkate alınmalıdır.

**Keywords:** Rheumatoid arthritis; loose bodies; synovial chondromatosis

**Anahtar Kelimeler:** Romatoid artrit; eklem fareleri; sinoviyal kondromatozis

Synovial chondromatosis (SC) is an uncommon disorder of unknown etiology and is characterized by metaplasia of the subsynovial cells resulting in multiple cartilaginous nodules which can lead loose bodies into the synovial cavity.<sup>1,2</sup> On the other hand, loose bodies in the joint space may be due to a num-

ber of conditions such as rice bodies, tuberculosis, secondary to the injury of the joint cartilage, or degeneration of the cartilage or osteochondritis dissecans in patients with rheumatoid arthritis (RA).<sup>3</sup> Because of the differences in prognosis and treatment for these entities, attempts have been made to identify

**Correspondence:** Hakan ALKAN

Department of Physical Medicine and Rehabilitation, Pamukkale University Faculty of Medicine, Denizli, TURKEY/TÜRKİYE

**E-mail:** alkanhsc@yahoo.com



Peer review under responsibility of Journal of Physical Medicine and Rehabilitation Science.

**Received:** 18 May 2020

**Received in revised form:** 16 Sep 2020

**Accepted:** 28 Sep 2020

**Available online:** 18 Jan 2021

1307-7384 / Copyright © 2021 Turkey Association of Physical Medicine and Rehabilitation Specialist Physicians. Production and hosting by Türkiye Klinikleri.

This is an open access article under the CC BY-NC-ND license (<https://creativecommons.org/licenses/by-nc-nd/4.0/>).

the features that might aid in differentiating between them.

Although SC is often a primary event, it may develop secondary to arthritis.<sup>4</sup> Secondary SC is thought to be caused by irritation of the synovial tissue of the affected joint which is also associated with degenerative joint disease, trauma, inflammatory arthropathies, osteochondritis dissecans, avascular necrosis.<sup>4,5</sup> The definitive diagnosis is achieved after the pathological examination of the synovial tissue. Milgram classified the histologic appearances of SC into three different phases.<sup>2</sup> Metaplasia of the synovial intima occurs which active synovitis and nodule formation is present without calcifications in the first phase. The involved joint has nodular synovitis and loose bodies which are primarily still cartilaginous in the second phase. Finally in phase 3 synovitis gets resolved but loose bodies remain which have a tendency to calcify. SC is rarely reported in patients with RA.<sup>6-9</sup> Nevertheless bilateral SC of knees in patients with RA, is even rarer.<sup>6,7</sup> To the best of our knowledge, bilateral SC of knees with different phases of Milgram's classification secondary to RA has not been reported in the literature thus far.

In this case presentation, we aimed to represent a rare case of bilateral knee chondromatosis with different phases of Milgram's classification secondary to RA.

## CASE REPORT

A forty seven years-old female patient, diagnosed with RA for 25 years, was presented with a history

of five years knee pain when she was referred to our hospital. On assessment of her musculoskeletal system, she had features consistent with chronic RA; limited motion of bilateral wrists and metacarpophalangeal joints, ulnar deviation of the metacarpophalangeal joints and Z-deformity. Moreover she had tenderness in her both knees with effusion and limited knee range of motion. The patient reported morning stiffness lasting for one hour in her both knees. The patient had no prior injuries to her knees. She had no extraarticular involvement and examination of other systems revealed no abnormality.

Laboratory markers of inflammation including erythrocyte sedimentation rate (ESR), and C-reactive protein (CRP) levels were slightly higher than normal limits. Her ESR was 30 mm/h and CRP was 0.7 mg/dL. Serologic investigation was positive for rheumatoid factor and anti-citrullinated protein antibodies. All the other laboratory examination showed no abnormality.

Radiographs of the hand and knees and magnetic resonance imaging (MRI) examination of both knees were performed. In consistent with physical examination, bilateral hand radiographs revealed typical features of advanced RA; bilateral radiocarpal, intercarpal and carpometacarpal joint space narrowing, periarticular osteoporosis, demineralized carpal bones, erosions in carpal bones and styloid process of ulna. On the other hand, bilateral knee radiographs showed widespread multiple calcified loose bodies, joint space narrowing and osteoporosis as shown in [Figure 1](#). Moreover on bilateral knee

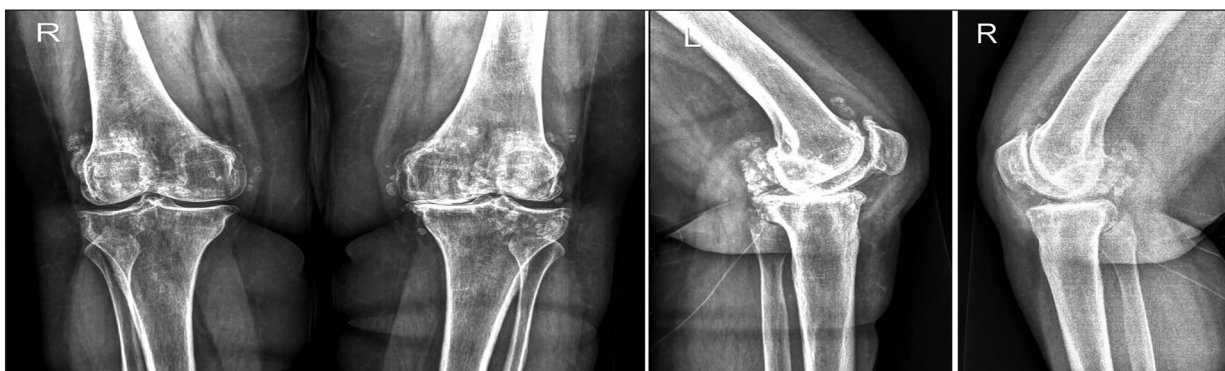

FIGURE 1: Postero-anterior and lateral X-rays of the knees demonstrating bilateral widespread multiple calcified loose bodies, joint space narrowing and osteoporosis.

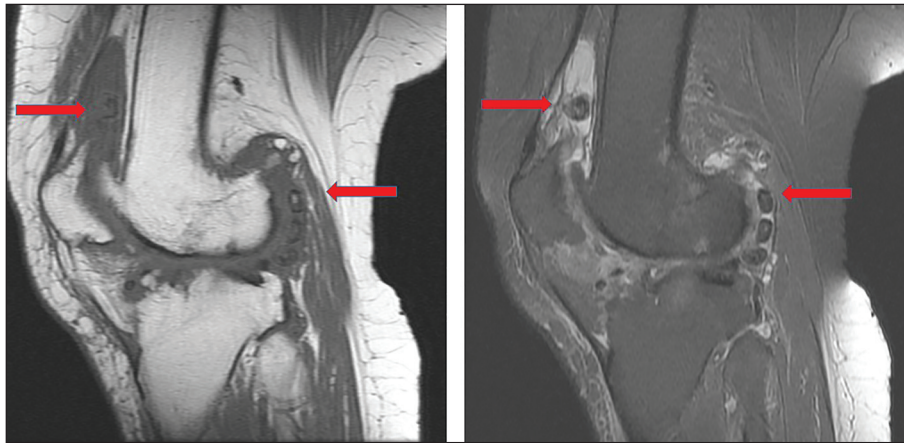
MRI, multiple hypointense and few hyperintense calcified nodules distributed throughout the joint with lobular contours were observed on T1 weighted images and peripheral hypointense central hyperintense multiple nodular lesions with an associated effusion were detected in the same sections of T2-weighted images (Figure 2, Figure 3). Based on the imaging findings, the patient was felt most likely to have SC with different phases of Milgram's classification however other etiologies causing loose bodies could not be completely excluded. The diagnosis was confirmed by pathology following arthroscopic biopsy. Histological examination of the extracted multiple loose bodies revealed differentiated hyaline cartilage evenly distributed chondro-

cytes and concentric rings of calcification, thereby leading to a diagnosis of secondary SC.

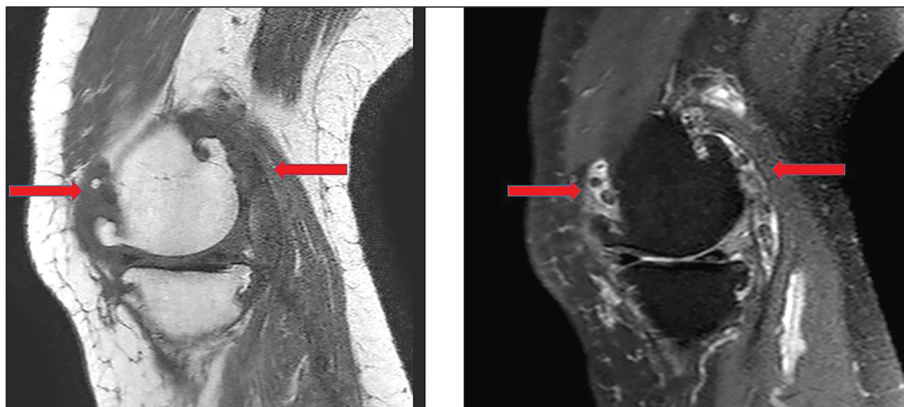
On admission to our clinic, the patient was using combination of leflunomide, methotrexate and steroids for RA. Since the disease activity was not under control, biologic agents were proposed to patient for the treatment of RA. However the patient refused to use biologics as well as arthroplasty for her knees. Currently she is under clinical and radiological surveillance.

## DISCUSSION

Differential diagnosis of loose bodies are important because each diagnosis required a different treatment



**FIGURE 2:** Left knee magnetic resonance imaging (MRI) showing multiple hypointense and few hyperintense calcified nodules distributed throughout the joint with lobular contours on T1 weighted image and multiple nodular lesions with peripheral hypointense central hyperintense in the same sections of T2-weighted image. a) Left knee MRI T1-weighted image; b) Left knee MRI T2-weighted image.



**FIGURE 3:** Right knee magnetic resonance imaging (MRI) multiple hypointense nodules and few hyperintense calcified nodules with lobular contours were observed in on T1-weighted image and peripheral hypointense central hyperintense multiple nodular lesions with an associated effusion were detected in the same sections of T2-weighted image. a) Right knee MRI T1-weighted image; b) Right knee MRI T2-weighted image.

strategy. The distinction between loose bodies can be even more difficult in patients with RA. Understanding the pathology, recognizing the radiographic and MRI appearance of secondary SC and differentiating it from primary form and other synovial pathologies is mandatory for clinical management of these patients.<sup>1</sup> In this case presentation, a rare case with bilateral knee chondromatosis secondary to RA was reported and differential diagnosis of this condition was discussed.

Epidemiology of SC is not known but it occurs more commonly in males. Although often benign, malignant transformation can occur.<sup>4</sup> Moreover multiple joint involvement is very infrequent in SC. The current standard for the treatment of SC is arthroscopic or open removal of the loose bodies, with complete synovectomy.<sup>10</sup> SC is classified as either primary or secondary.<sup>11</sup> Primary SC results from a proliferation of chondrocytes in the synovial membrane leading to the formation of cartilaginous loose bodies. Secondary SC is associated with mechanical or arthritic joint abnormalities which cause intra-articular chondral bodies.<sup>5</sup>

The clinical symptoms of SC is usually non-specific and may overlap with other conditions. Clinically, all loose bodies and SC secondary to RA may present with pain, swelling, and restricted range of motion.<sup>12</sup> These symptoms may be due to either loose bodies, SC itself or secondary RA changes. Thus these clinical findings can not give additional information for differential diagnosis of these diseases. Similarly our patient had pain in her both knees with effusion and limited range of motion.

Initially, SC may present with an effusion and non-calcified loose bodies, so it is also difficult to detect SC by X-ray in the early stages before the cartilaginous nodules become ossified.<sup>13</sup> In a review of SC of the hip, it was reported that approximately half of SC cases do not initially present with positive radiographic findings.<sup>14</sup> In the late stages radiographs of the primary SC reveal multiple intra-articular calcifications of similar size and shape, distributed throughout the joint, with typical "ring-and-arc" chondroid mineralization. In cases of secondary SC, osteochon-

dral intra-articular fragments are also observed. However, these are fewer in numbers and more variable in size suggesting various times of origin as compared with the fragments observed in primary disease.<sup>11</sup> In addition, in the secondary SC, radiologically underlying other articular disease can be detected and also several rings of calcification may be identified on radiographs, compared with the single ring seen in primary SC.<sup>15</sup> In our case, bilateral knee radiographs showed widespread multiple calcified loose bodies with variable in size, joint space narrowing and osteoporosis which is likely to radiographic findings of secondary SC.

MRI is a useful radiologic method in the early diagnosis of the diseases.<sup>16</sup> RA can lead to intra-articular rice bodies of which MRI appearance were similar to that of non-calcified SC. MRI shows three different patterns of SC which correlates with Milgram's phases of SC. Homogeneous lobulated intra-articular signals isointense with respect to muscle on T1-weighted images and hyperintense on T2-weighted images are seen in phase 1. In addition to the above, multiple areas void signals appear which correspond to the beginning of calcification in phase 2. Features of other two phases can be seen with multiple foci isointense to fat with peripheral low signal rims can be seen in phase 3.<sup>8</sup> In accordance with these findings our patient also had multiple hypointense and hyperintense calcified nodules on T1 and T2 weighted images reflecting the properties of all three Milgram's phases. Moreover, advanced imaging modalities including MRI may show non-specific findings due to similar intensity of loose bodies with the synovial fluid. Thus, histologic correlation with the radiologic appearance is essential for correctly diagnosing and treating the SC.

The histopathological features of loose bodies are usually distinctive, whereas the clinical findings may be ambiguous.<sup>16</sup> Histopathology of SC shows fragments a well-differentiated hyaline cartilage with focal calcifications, uniform chondrocytes and annular calcification surrounding the core tissue. Secondary SC can be distinguished histologically from primary SC by the reactive, proliferative chon-

dral bodies that often have a central nidus of non-neoplastic hypocellular cartilage that grows in concentric rings, lack of atypia, and presence of fragments of articular hyaline cartilage.<sup>11</sup> In accordance with these findings our case showed uniform chondrocytes and annular calcification surrounding the core tissue leading to a diagnosis of secondary SC.

## CONCLUSION

The differential diagnosis of loose bodies could be made after a detailed history, physical examination, and radiologic evaluation in patients with RA. However, the definitive diagnosis is achieved after histological examination. SC should be considered in the differential diagnosis of patients presenting with a persistent arthritis in patients with RA.

## Ethical Approval

*Informed consent: Written informed consent was obtained from the patient.*

## Acknowledgements

*This study is partially presented in International Internal Medicine Training Meeting 13, Bucharest, 16-18 March 2018.*

## Source of Finance

*During this study, no financial or spiritual support was received neither from any pharmaceutical company that has a direct connection with the research subject, nor from a company that provides or produces medical instruments and materials which may negatively affect the evaluation process of this study.*

## Conflict of Interest

*No conflicts of interest between the authors and / or family members of the scientific and medical committee members or members of the potential conflicts of interest, counseling, expertise, working conditions, share holding and similar situations in any firm.*

## REFERENCES

- Chalasan P, Koduru S, Mikkineni K. A rare case of multiple rice bodies in glenohumeral joint, subscapular recess and along long head of biceps. *J Orthop Case Rep.* 2016;6(3):53-5. [[Crossref](#)] [[PubMed](#)] [[PMC](#)]
- Milgram JW. Synovial osteochondromatosis: a histopathological study of thirty cases. *J Bone Joint Surg Am.* 1977;59(6):792-801. [[Crossref](#)] [[PubMed](#)]
- O'Connell JX. Pathology of the synovium. *Am J Clin Pathol.* 2000;114(5):773-84. [[Crossref](#)] [[PubMed](#)]
- Shearer H, Stern P, Brubacher A, Pringle T. A case report of bilateral synovial chondromatosis of the ankle. *Chiropr Osteopat.* 2007;15:18. [[Crossref](#)] [[PubMed](#)] [[PMC](#)]
- Ümit Yemişçi O, Ozen S, Kart Köseoğlu H. A rare benign tumor with diagnostic difficulties: synovial chondromatosis. *Arch Rheumatol.* 2019;35(2):274-7. [[Crossref](#)] [[PubMed](#)] [[PMC](#)]
- Tahmasebi MN, Bashti K, Sobhan M, Ghorbani G. Bilateral synovial knee chondromatosis in a patient with rheumatoid arthritis: case-report and literature review. *Arch Bone Jt Surg.* 2014;2(4):260-4. [[PubMed](#)] [[PMC](#)]
- Padhan P, Ahmed S. Synovial chondromatosis. *N Engl J Med.* 2019;381(14):1364. [[Crossref](#)] [[PubMed](#)]
- Bhadu D, Das SK, Dhakad U, Sharma M, Srivastava D, Tripathy SR. Synovial chondromatosis involving multiple joints in rheumatoid arthritis: a case report review of the literature. *Int J Rheum Dis.* 2017;20(12):2148-51. [[Crossref](#)] [[PubMed](#)]
- Witwity T, Uhlmann R, Nagy MH, Bhasin VB, Bahgat MM, Singh AK. Shoulder rheumatoid arthritis associated with chondromatosis, treated by arthroscopy. *Arthroscopy.* 1991;7(2):233-6. [[Crossref](#)] [[PubMed](#)]
- Reverté Vinaixa MM, Singh R, Monyart JM, Llado GD, Dominguez MP, Feliu EC, et al. Wrist synovial chondromatosis: case report and literature review. *Hand Surg.* 2012;17(2):233-8. [[Crossref](#)] [[PubMed](#)]
- Ji JH, Shafi M, Jeong DS. Secondary synovial chondromatosis of the shoulder. *Knee Surg Sports Traumatol Arthrosc.* 2015;23(9):2624-7. [[Crossref](#)] [[PubMed](#)]
- Chiang CH, Jou IM, Wang PH, Chern TC, Huang MT. Synovial osteochondromatosis of the second metatarsophalangeal joint: a case report. *J Foot Ankle Surg.* 2011;50(4):458-61. [[Crossref](#)] [[PubMed](#)]
- Rogachefsky RA, Zlatkin MB, Greene TL. Synovial chondromatosis of the distal radioulnar joint: a case report. *J Hand Surg Am.* 1997;22(6):1093-7. [[Crossref](#)] [[PubMed](#)]
- Startzman A, Collins D, Carreira D. A systematic literature review of synovial chondromatosis and pigmented villonodular synovitis of the hip. *Phys Sportsmed.* 2016;44(4):425-31. [[Crossref](#)] [[PubMed](#)]
- Murphey MD, Vidal JA, Fanburg-Smith JC, Gajewski DA. Imaging of synovial chondromatosis with radiologic-pathologic correlation. *Radiographics.* 2007;27(5):1465-88. [[Crossref](#)] [[PubMed](#)]
- Yu GV, Zema RL, Johnson RW. Synovial osteochondromatosis. A case report and review of the literature. *J Am Podiatr Med Assoc.* 2002;92(4):247-54. [[Crossref](#)] [[PubMed](#)]