

Locally applied molgramostim improves wound healing at colonic anastomoses in rats after ligation of the common bile duct

Mehmet A. Gulcelik, MD;* Soykan Dinc, MD;* Ferda Bir, MD;† Orhan Elitok, MD;* Haluk Alagol, MD;* Murat Oz, MD, PhD‡

Background: Several systemic factors, including jaundice, long-term corticosteroid therapy, diabetes and malnutrition, increase the risk of anastomotic dehiscence. The local application of molgramostim (recombinant human granulocyte-macrophage colony stimulating factor) has been reported to improve impaired dermal wound healing. Since jaundice, one of the systemic risk factors for anastomotic dehiscence, causes significant impairment of anastomotic healing, we hypothesized that locally injected molgramostim could improve the healing of bowel anastomoses in bile-duct-ligated rats used as an experimental model for jaundice. **Methods:** Eighty-six Sprague–Dawley rats were randomized into 4 groups of 20–22 animals each as follows: group 1 — colonic anastomosis only; group 2 — laparotomy followed 7 days later by colonic anastomosis; group 3 — common-bile-duct ligation (CBDL) followed 7 days later by colonic anastomosis (control group); group 4 — CBDL followed by colonic anastomosis with locally applied molgramostim. Laparotomy was performed under anesthesia in group 2 rats. In groups 3 and 4, laparotomy was followed by ligation and dissection of the common bile duct. After 7 days, colonic anastomosis was performed; in group 4 rats, molgramostim (50 µg) was injected into the perianastomotic area. On postoperative day 3, rats were killed, and the bursting pressures and hydroxyproline levels measured. Two rats from each group were selected for histopathological examination. **Results:** The mean bursting pressure in group 4 was significantly higher than that in group 3 (37.8 v. 30.5 mm Hg [$p < 0.01$]). The mean hydroxyproline level in group 3 was significantly lower than that of the other groups (2.7 v. 3.1–3.5 mg/g tissue [$p < 0.01$]). On histopathological examination, specimens from group 4 rats showed an increased mononuclear cell population and a smaller gap on the anastomotic line than those from group 3. **Conclusion:** The local injection of molgramostim improves healing of the impaired wound in rats subjected to CBDL.

Contexte : Plusieurs facteurs systémiques, y compris l'ictère, les corticothérapies de longue durée, le diabète et la malnutrition, augmentent le risque de déhiscence anastomotique. On a signalé que l'application locale de molgramostim (forme recombinante du facteur de croissance des colonies de granulocytes et de macrophages) améliore la guérison déficiente des plaies dermiques. Étant donné que l'ictère, l'un des facteurs de risque systémiques de déhiscence anastomotique, entraîne un déficit important de la guérison de l'anastomose, nous avons posé l'hypothèse voulant que l'injection locale de molgramostim pourrait améliorer la guérison des anastomoses intestinales chez des rats utilisés comme modèle expérimental de l'ictère et à qui on a pratiqué une ligature du canal cholédoque. **Méthodes :** Quatre-vingt-six rats de Sprague–Dawley ont été répartis aléatoirement entre 4 groupes comptant de 20 à 22 animaux : groupe 1 — anastomose du côlon seulement; groupe 2 — laparotomie suivie d'une anastomose du côlon 7 jours plus tard; groupe 3 — ligature du canal cholédoque (LCC) suivie d'une anastomose du côlon 7 jours plus tard (groupe témoin); groupe 4 — LCC suivie d'une anastomose du côlon conjuguée avec une application locale de molgramostim. La laparotomie des rats du groupe 2 a été effectuée sous anesthésie. Dans les groupes 3 et 4, la laparotomie a été suivie d'une ligature et d'une dissection du canal cholédoque. Après une période de 7 jours, on a effectué l'anastomose du côlon. Les rats du

From the *Department of General Surgery, Ankara Oncology Training and Research Hospital, Demetevler, Ankara, the †Department of Pathology, Pamukkale University, Denizli, Turkey, and the ‡National Institute on Drug Abuse, Intramural Research Program, Cellular Neurobiology Section, Baltimore, Md.

Accepted for publication May 18, 2004

Correspondence to: Dr. Murat Oz, National Institute on Drug Abuse/Intramural Research Program, Cellular Neurobiology Section, 5500 Nathan Shock Dr., Baltimore MD 21224; fax 410 550-1621; moz@intra.nida.nih.gov

groupe 4 ont reçu une injection de molgramostim (50 µg) dans la région périanastomotique. Trois jours après l'intervention, les rats ont été mis à mort, puis les pressions de rupture et les niveaux d'hydroxyproline ont été mesurés. Dans chaque groupe, deux rats ont été choisis pour l'examen histopathologique. **Résultats :** Dans le groupe 4, la pression de rupture moyenne était considérablement plus élevée que celle enregistrée dans le groupe 3 (37,8 c. 30,5 mm Hg [$p < 0,01$]). Le niveau moyen d'hydroxyproline enregistré dans le groupe 3 était considérablement inférieur à celui des autres groupes (2,7 c. 3,1–3,5 mg/g de tissu [$p < 0,01$]). L'examen histopathologique a révélé que les rats du groupe 4 présentaient une population de cellules mononucléaires accrue et un moindre écart au niveau de l'anastomose, comparativement aux rats du groupe 3. **Conclusion :** L'injection locale de molgramostim améliore la guérison des plaies problématiques de rats ayant subi une LCC.

Several systemic factors, including ischemia, jaundice, infection, diabetes mellitus and malignant lesions, increase the risk of poor healing in colonic anastomosis.¹ Obstructive jaundice causes serious pathologic and biochemical changes associated with increased postoperative morbidity and mortality.² The condition also can result in impaired hepatic, renal and systemic immune functions.³ In experimental studies, jaundice lowers the bursting strength of abdominal wounds, decreases the rupture strength of skin wounds, adversely affects the migration of fibroblasts in wound healing⁴⁻⁸ and reduces the migration of reticuloendothelial cells.⁹ Immune dysfunction has also been demonstrated and may be due to cytokine production by macrophages or abnormal hepatocyte-Kupffer cell dysfunctions.⁹ In oncologic surgery, gastrointestinal cancers and their lymphadenopathies cause bile duct obstruction necessitating internal drainage of the bile. In clinical and experimental studies jaundice has emerged as one of the adverse risk factors in wound healing.⁴⁻¹¹ Wound dehiscence occurs in 2%–4% of jaundiced patients and incisional hernia in 10%–12%.² Postoperative death has varied from 10%–30% in patients with obstructive jaundice.⁶⁻¹⁰ Leading risk factors for death in these patients have been identified as wound infection, septicemia, intra-abdominal abscesses, increased wound dehiscence and anastomotic leak.⁷⁻¹¹

Recombinant human granulocyte-macrophage colony stimulating factor (molgramostim) has been shown to induce hematopoietic progenitor cells in myeloid and erythroid lineages to

proliferate and to stimulate mature monocytes/macrophages and neutrophils.¹² Furthermore, it has been shown to enhance the migration and proliferation of endothelial cells and to promote keratinocyte growth.^{13,14} Animal studies have also shown that local application of molgramostim to wounded areas results in an increase in granulation tissue and breaking strength of incisional wounds, resulting in a faster wound healing.¹⁵⁻²² For this reason, some have suggested the use of molgramostim therapy in some patients with non-healing ulcers.²³

We hypothesized that molgramostim may have beneficial effects on impaired healing of colonic anastomosis in jaundiced rats. Thus, we studied the effects of locally applied molgramostim on the healing process in rats that had common-bile-duct-ligation (CBDL) as an experimental model for jaundice.

Methods

Our procedures were in accordance with the *Guide for the care and use of laboratory animals* (National Institutes of Health Publication no. 86-23, revised 1985).

Eighty-six male Sprague–Dawley rats were randomized into the following groups:

- Group 1: colonic anastomosis ($n = 22$)
- Group 2: laparotomy and colonic anastomosis ($n = 20$)
- Group 3: colonic anastomosis in rats after CBDL (control group; $n = 22$)
- Group 4: colonic anastomosis in rats after CBDL plus 50 µg of molgramostim ($n = 22$).

Rats were brought into the laboratory 24 hours before the operation, and housed in separate cages. Investigators were blinded to groups during surgical procedures. All animals were anesthetized with intramuscular injections of ketamine (40 mg/kg; Ketalar, Parke Davis, Pfizer, Istanbul, Turkey) and xylazine (5 mg/kg; Rompun, Bayer, Leverkusen, Germany). After laparotomy in the rats from groups 3 and 4, the common bile duct was ligated and dissected. All components of anastomotic healing were studied in the significantly jaundiced rats in these 2 groups.² In group 2, only laparotomy was performed. After 7 days, the rats in all groups were anesthetized. A 4-cm median laparotomy was performed and the left colon transected (without resection of a segment) by a transverse circumferential incision 5 cm proximally to the peritoneal reflection, taking care to preserve the marginal arteries. The bowel was restored by an end-to-end anastomosis with 6 interrupted, inverting sutures of 6-0 polypropylene (Prolene; Ethicon, Edinburgh). In group 4, 0.5 mL of molgramostim (from the solution of 100 µg/mL; Novartis Pharma, Basel) was injected subserosally into the perianastomotic area by multiple injections. We applied 50 µg molgramostim as recommended in our earlier studies in which molgramostim was used on anastomotic wounds.^{24,25} Anastomoses were performed on postoperative day 7 after CBDL to allow the development of significant jaundice. Subsequently, the abdominal incision was closed with 2 layers of continuous 4-0 silk sutures. Postoperatively, the rats were fed a diet with rat chow and water *ad libitum*.

On postoperative day 3 before

bursting pressures were measured, 2 rats from each group were randomly selected for histopathological examination of anastomotic tissue. Investigators were blinded to groups, repeat laparotomies were made under anesthesia, and blood samples were taken to measure the serum bilirubin levels and the leukocyte count. Intra-abdominal adhesions were separated gently, and a 6-cm segment of colon centred by the anastomosis was resected; the rats were then killed. In the remaining rats, the distal parts of the segments were closed with 2-0 silk sutures. The proximal parts were attached to an intraluminal pressure manometer (monitoring kit L978-A07; Abott, Slingo, Ireland). The segments were filled with isotonic NaCl solution with continuous infusion (4 mL/min). The rising intraluminal pressures were monitored and the bursting pressures noted.

Determination of hydroxyproline levels

A segment of tissue measuring 0.5 cm (30–50 mg) was resected from the anastomosis, frozen to -25°C , and then sent immediately for evaluation of hydroxyproline levels. The tissue samples were placed into hydrolysis tubes. 50 mM of potassium phosphate buffer, pH 7.0, and equal volume of concentrated hydrochloric acid were added to each tube, and

the samples were hydrolyzed at 110°C for 16 hours. The pH of the samples was adjusted to 8.5 with diluted sodium hydroxide and oxidized at room temperature with chloramine-T solution. After 4 minutes, Ehrlich's reagent was added to the tubes. The colour was allowed to develop at 60°C for 25 minutes and the absorbency at $560\ \mu\text{m}$ was determined by the method of Bergman and Loxley.²⁶ The hydroxyproline concentration was calculated as $\mu\text{g}/\text{mg}$ wet weight tissue.

Histopathological examination

For the histopathological examinations, 1 cm of tissue sample from the injection site was kept in 10% buffered formalin solution and stained with hematoxylin–eosin.

Statistical analysis

The distribution of bursting pressure and hydroxyproline values was normal and their variances were homogeneous. Therefore, 1-way analysis of variance with the post-hoc Tukey test was used for the statistical analysis. Because multiple comparisons were made, the Bonferroni correction was performed and the criterion for sig-

nificance was accepted as $p < 0.016$. The statistical analyses were performed with use of a statistical program (SPSS 10.0, Prentice Hall, NJ).

Results

The mean values of total bilirubin levels in the control (group 3) and molgramostim-treatment group (group 4) were $235\ \mu\text{mol}/\text{L}$ and $226\ \mu\text{mol}/\text{L}$ respectively. The differences of mean values for leukocyte counts and total bilirubin levels between groups 3 and 4 are statistically not significant, indicating that both group of animals were equally jaundiced.

The mean values of the bursting pressures and hydroxyproline levels of the groups are presented in Table 1. The values for bursting pressures and hydroxyproline levels in groups 1, 2 and 4 were significantly higher than those in group 3 ($p < 0.001$, Table 1). On the other hand, the differences of mean values for bursting pressures and hydroxyproline levels between groups 1, 2 and 4 were statistically not significant.

Sections of specimens taken from colonic segments of anastomotic areas are presented in Figure 1, Figure 2 and Figure 3. In Figure 1, histopathological examination of a

Table 1

Bursting pressures and hydroxyproline levels in control and treatment groups. Values are means and standard deviations

| Grp | No. of rats | Bursting pressures, mm Hg | Hydroxyproline levels, mg/g tissue |
|-----|-------------|---------------------------|------------------------------------|
| 1 | 20 | 46.1 (12.2) | 3.5 (0.8) |
| 2 | 20 | 44.5 (14.3) | 3.4 (1.1) |
| 3 | 18 | 30.5 (8.0)* | 2.7 (0.5)† |
| 4 | 19 | 37.8 (9.3) | 3.1 (0.3) |

See text for description of groups.

*Group 3 v. group 1 or group 2, $p < 0.001$; group 4 v. group 3, $p = 0.01$

†Group 3 v. group 1 or group 2, $p < 0.001$; group 4 v. group 3, $p = 0.01$

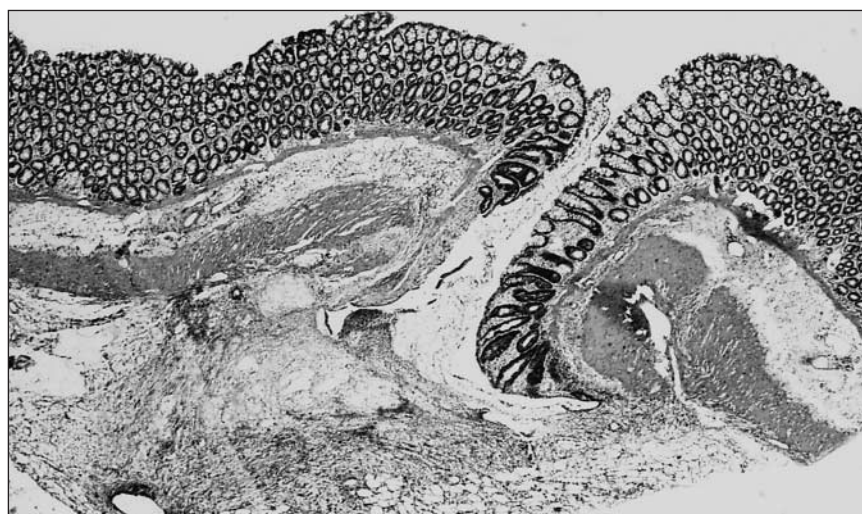


FIG. 1. Cross-section of a specimen from a rat in group 1 (colonic anastomosis only) demonstrates normal anastomotic wound healing on postoperative day 3. The gap between the anastomotic edges is filled by granulation tissue (hematoxylin–eosin stain; original magnification $\times 10$).

section from a group 1 rat indicates that the anastomotic defect is nearly filled with granulation tissue and

there is no gap in the submucosal layer. In Figure 2, a section of colonic segment from a group 3 rat,

there is a large gap in the submucosal layer and an abscess has formed near the anastomotic line. In addition, the mononuclear cell population in the anastomotic area is sparse in this specimen. Figure 3 demonstrates a section of colonic segment from a group 4 rat injected with molgramostim. The mononuclear cell population is increased, and the gap on the anastomotic line is smaller than that in group 3.

Discussion

In gastrointestinal surgery, impaired wound healing and anastomotic dehiscence are important problems. Obstructive jaundice is known to compromise both hepatic and systemic immune functions, and it has been reported that immune system defects in phagocytic and neutrophilic functions may occur.³ Also, there is a functional disorder of the reticuloendothelial system, which plays a role in the immunologic response and is important in the synthesis of monocytes, neutrophils and prostaglandins.³ Furthermore, pathologic conditions caused by obstructive jaundice, including renal insufficiency, cardiovascular changes and coagulation disorders, may cause additional deleterious effects on the healing of anastomoses. Obstructive jaundice has been shown to reduce the number of fibroblasts present in healing wounds^{6,7} and to decrease the migration of reticuloendothelial cells and fibroblasts into the wounded area.^{6,8} In addition, delay in angiogenesis, which adversely affects the collagen deposition, has been reported to occur in rats with obstructive jaundice.^{2,6-8} In line with these earlier results, hydroxyproline levels, which indicate the amount of collagen in the wounded field, and the bursting pressures, were decreased significantly in the CBDL group (group 3).

In cancer patients, granulocyte-macrophage colony stimulating factor (GM-CSF) is widely used during the

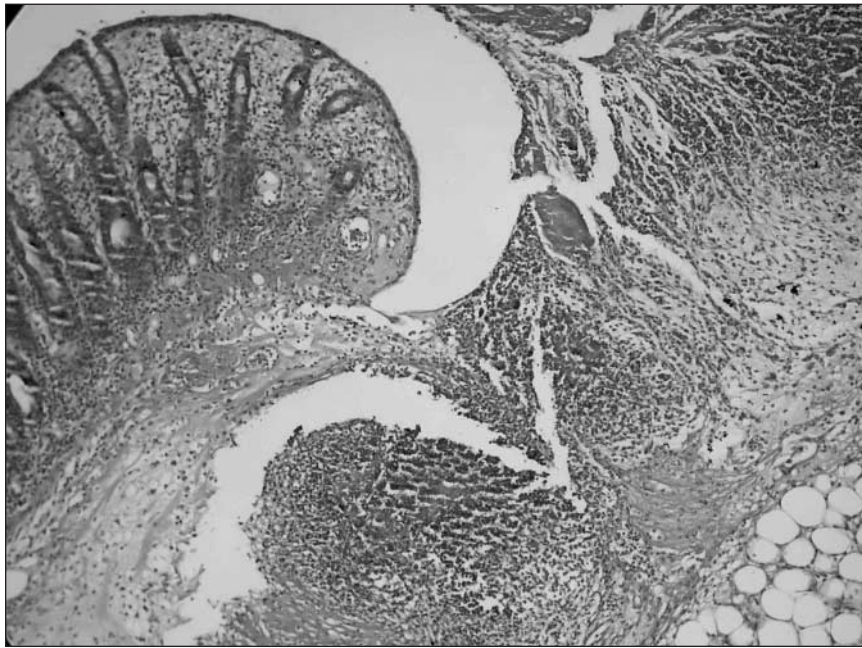


FIG. 2. Cross-section of the anastomosis in a rat from group 3 (colonic anastomosis after common-bile-duct ligation) demonstrates impaired anastomotic wound healing with a significant gap in the submucosal layer. There is an abscess formation in the anastomotic area. Mononuclear cell infiltration is decreased (hematoxylin-eosin stain; original magnification $\times 20$).

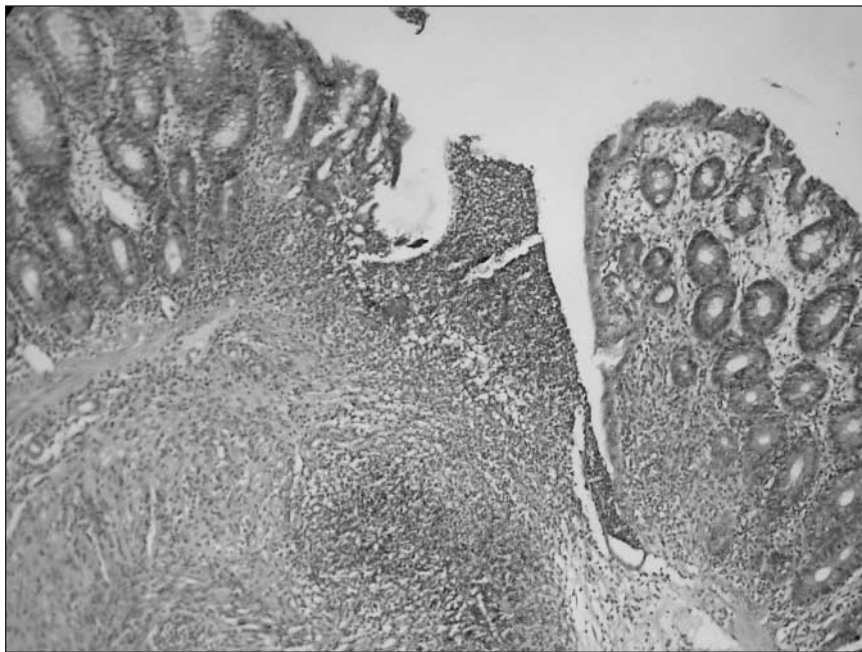


FIG. 3. Cross-section obtained on postoperative day 3 of the anastomosis from a rat in group 4 (common-bile-duct ligation (CBDL) followed by colonic anastomosis and injection of 50 μ g molgramostim) indicated that the gap at the anastomotic line is smaller than that in the group with CBDL only. The mononuclear cell population is also increased (hematoxylin-eosin stain; original magnification $\times 20$).

treatment of neutropenia caused by chemotherapy. Beneficial effects of GM-CSF have been reported in the treatment of several clinically and experimentally impaired dermal wounds such as venous ulcers, Adriamycin extravasations and radiotherapy-related dermal complications.^{27,28} Recent studies suggest that the stimulation of cell infiltration by GM-CSF in the injection area induces collagen synthesis by fibroblast activation, increases the population of keratinocytes and Langerhans cells, enhances the proliferation of endothelial cells and induces their migration.^{29,30} GM-CSF also has immunologic, hematologic and inflammatory effects. It has been reported to increase the population and function of monocytes-macrophages³ and to induce proliferation and differentiation of monocytes of large macrophage-like cells.^{31,32} In support of these findings, compared with control group, increased mononuclear cell infiltration observed in our histopathological specimens from molgramostim-treated animals (Fig. 2, Fig. 3). The action of GM-CSF on monocytes-macrophages, which may be relevant to enhanced antimicrobial activity, include increased phagocytosis and oxidative metabolism, an increased number of Fc receptors, release of chemotactic factors and stimulation of mechanisms for killing intracellular viruses, fungi, bacteria and protozoa.^{12,32} Because of these effects, GM-CSF has antimicrobial and antitumoral effects and enhances wound healing.^{12,32}

In our earlier studies, we found that GM-CSF significantly improves anastomotic wound healing in rats undergoing long-term steroid and intraperitoneal 5-fluorouracil treatment.^{24,25} We also found that in intraoperatively radiated rats, GM-CSF had beneficial effects on the wound healing in ischemic colon segments and anastomoses.^{33,34}

Although there are multiple parameters, including bursting pressure, bursting wall tension and tensile strength,³⁵ with which to observe the

intrinsic resistance of an anastomosis, we have chosen bursting pressure as a mechanical parameter since this approximates clinical conditions closely, especially in the early phase of wound healing.³⁶ In addition, we measured the diameters of anastomoses after bursting and found that there were no statistically significant differences among the groups.

Although systemic administration of GM-CSF has been shown to have no effect on wound healing,^{21,24} it significantly improves dermal-wound healing when it is applied locally. For example, various routes of local molgramostim application (subcutaneously around the wound, incubated with skin grafts and applied topically in sterile water) have been demonstrated to induce rapid wound healing and decrease the time to total wound closure.¹⁵⁻¹⁷ Although in some studies, intraperitoneal or systemic administration of GM-CSF was reported to be ineffective on the healing of intestinal anastomoses,^{37,38} it is likely that due to the intraperitoneal adhesions, the intraperitoneal use of the drug may not have access to the anastomotic area, and local concentration of the drug may not reach a level required for a healing effect. In line with this suggestion and earlier studies, systemic application of GM-CSF was also found to be ineffective in our previous study.²⁴ However, after subserosal injection of GM-CSF into the anastomotic line of the intestinal wall, a significant improvement in the healing process of the anastomotic wound was found.

Compared with the control group (group 3), bursting pressures and hydroxyproline levels were significantly higher in rats from group 4 in which GM-CSF was injected perianastomotically, indicating a beneficial effect on the healing of anastomotic wound. Although the exact mechanism of the GM-CSF effect is currently unknown, multiple factors likely play roles. First, it has been reported that GM-CSF reverses neu-

trophil and macrophage functions, which have been damaged in jaundice. Second, GM-CSF increases the number of fibroblasts in the periphery of the anastomotic area, causing an increase in the amount of collagen in the healing area. Finally, GM-CSF has been reported to have antimicrobial and neovascularization effects on application sites.^{12,39} All of these effects may reduce the increased infection risk in rats that had undergone CBDL. Also, GM-CSF has been used clinically in patients with coronary artery disease due to its neovascularization effects.³⁹ Combinations of these factors may contribute to the beneficial effects of GM-CSF application observed in this study.

Conclusion

The local application of molgramostim significantly improves healing of the impaired bowel anastomosis in rats after CBDL.

Acknowledgement: We thank Ms. Mary Pfeiffer of NIDA/NIH for reading the manuscript.

Competing interests: None declared.

References

1. Thornton FJ, Barbul A. Healing in the gastrointestinal tract. *Surg Clin North Am* 1997;77:549-74.
2. Comert M., Taneri F, Tekin E, Ersoy E, Oktemer S, Onuk E, et al. The effect of pentoxifylline on the healing of intestinal anastomosis in rats with experimental obstructive jaundice. *Surg Today* 2000;30: 896-902.
3. Caglikulekci M, Besirov E, Ozkan H. The effect of granulocyte colony stimulating factor on immune parameters in experimental obstructive jaundice. *Hepatology* 2001;48:220-3.
4. Lee E. The effect of obstructive jaundice on the migration of reticulo-endothelial cells and fibroblasts into early experimental granulomata. *Br J Surg* 1972;59:875-7.
5. Than T, Evans HJ, Ryan CJ, Smith DA, Harper AM, Blumgart LH. Rupture strength of skin wounds in jaundiced rats. *Br J Exp Pathol* 1979;60:107-10.
6. Arnaud JP, Humbert W, Eloy MR,

- Adloff M. Effect of obstructive jaundice on wound healing. *Am J Surg* 1981;141:593-6.
7. Askew AR, Bates GJ, Balderson G. Jaundice and the effect of sodium taurocholate taken orally upon abdominal wound healing. *Surg Gynecol Obstet* 1984;159:207-9.
 8. Bayer I, Ellis H. Jaundice and wound healing: an experimental study. *Br J Surg* 1976;64:392-6.
 9. Sayan M, Alponat A, Yavuz N, Altinkaya E, Goksel S, Sariyar M. The effect of oral sodium taurocholate on endotoxemia and intestinal anastomotic wound healing in rats with obstructive jaundice. *Surg Today* 1997;27:953-7.
 10. Erbil Y, Berber E, Ozarmagan S, Seven R, Eminoglu L, Calis A, et al. The effect of sodium deoxycholate, lactulose and glutamine on bacterial translocation in common bile duct ligated rats. *Hepatogastroenterology* 1999;46:2791-5.
 11. Kapoor VK, Pradeep R, Haribhakti SP, Singh V, Sikora SS, Saxena R, et al. Intrahepatic segment III cholangiojejunostomy in advanced carcinoma of the gallbladder. *Br J Surg* 1996;83:1709-11.
 12. Jones TC. The effects of rhGM-CSF on macrophage function. *Eur J Cancer* 1993;29(Suppl 13):10-3.
 13. Bussolino F, Wang JM, Defilippi P, Turini F, Sanavio F, Edgell CJ, et al. Granulocyte- and granulocyte-macrophage-colony stimulating factors induce human endothelial cells to migrate and proliferate. *Nature* 1989;337:471-3.
 14. Hancock GE, Kaplan G, Cohn ZA. Keratinocyte growth regulation by the products of immune cells. *J Exp Med* 1988;168:1395-402.
 15. da Costa RM, Aniceto C, Jesus FM, Mendes M. Quick healing of leg ulcers after molgramostim. *Lancet* 1994;344:481-2.
 16. Pojda Z, Struzyna J. Treatment of non-healing ulcers with rhGM-CSF and skin grafts. *Lancet* 1994;343:1100.
 17. Raderer M, Kornek G, Hejna M, Koperna K, Scheithauer W, Base W. Topical granulocyte-macrophage colony-stimulating factor in patients with cancer and impaired wound healing. *J Natl Cancer Inst* 1997;89:263.
 18. Arnold F, O'Brien J, Cherry G. Granulocyte monocyte-colony stimulating factor as an agent for wound healing. *J Wound Care* 1995;4:400-2.
 19. Shamseddine AI, Khalil AM, Kibbi AG, Abu Nasr TA, Seud MA, El Saghir NS. Granulocyte macrophage-colony stimulating factor for treatment of chemotherapy extravasation. *Eur J Gynaecol Oncol* 1998;19:479-81.
 20. Halabe A, Ingber A, Hodak E, David M. Granulocyte-macrophage colony stimulating factor — a novel therapy in the healing of chronic ulcerative lesions. *Med Sci Res* 1995;23:65-6.
 21. Jyung RW, Wu L, Pierce GF, Mustoe TA. Granulocyte-macrophage colony-stimulating factor and granulocyte colony-stimulating factor: differential action on incisional wound healing. *Surgery* 1994;115:325-34.
 22. El Saghir NS, Bizri AR, Shabb NS. Pressure ulcer accelerated healing with local injections of granulocyte macrophage-colony stimulating factor. *J Infect* 1997;35:179-82.
 23. Groves RW, Schmidt-Lucke JA. Recombinant human GM-CSF in the treatment of poorly healing wounds. *Adv Skin Wound Care* 2000;13:107-12.
 24. Dinc S, Alagol H, Gulcelik MA, Ozbirecikli B, Kuru B, Renda N, et al. Locally applied granulocyte-macrophage colony-stimulating factor improves the impaired bowel anastomoses in rats with long-term corticosteroid treatment. *World J Surg* 2002;26:1208-13.
 25. Erdem E, Dinc S, Erdem D, Ustun H, Caydere M, Alagol H. Effects of intraperitoneal chemotherapy and GM-CSF on anastomotic healing: an experimental study in rats. *J Surg Res* 2002;108:1-6.
 26. Bergman I, Loxley R. Two improved and simplified methods for the spectrophotometric determination of hydroxyproline. *Ann Chem* 1963;35:1961-5.
 27. Kilic D, Sayan H, Gönül B. The effect of GM-CSF on glutathione and lipid peroxidation in a rat model. *Eur J Surg Oncol* 2000;26:701-4.
 28. Shamseddine AI, Khalil AM, Kibbi AG, Abu Nasr TA, Seoud MA, El Saghir NS. Granulocyte macrophage-colony stimulating factor for treatment of chemotherapy extravasation. *Eur J Gynaecol Oncol* 1998;19:479-81.
 29. Branstein S, Kaplan G, Gottlieb AB, Schwartz M, Walsh G, Abalos RM, et al. GM-CSF activates regenerative epidermal growth and stimulates keratinocyte proliferation in human skin in vivo. *J Invest Dermatol* 1994;103:601-4.
 30. Kaplan G, Walsh G, Gottlieb AB, Schwartz M, Walsh G, Abalos RM, et al. Novel responses of human skin to intradermal recombinant granulocyte-macrophage colony stimulating factor: Langerhans recruitment, keratinocyte growth and enhanced wound healing. *J Exp Med* 1992;175:1717-28.
 31. Lopez AF, Williamson DJ, Gamble JR, Begley CG, Harlan JM, Klebanoff SJ, et al. Recombinant human granulocyte-macrophage colony-stimulating factor stimulates in vitro mature human neutrophil and eosinophil function, surface receptor expression, and survival. *J Clin Invest* 1986;78:1220-8.
 32. Armitage JO. Emerging applications of recombinant human granulocyte-macrophage colony-stimulating factor. *Blood* 1998;92:4491-508.
 33. Dinc S, Ozbirecikli B, Gulcelik MA, Ergeneci D, Kuru B, Erdem E, et al. The effects of local GM-CSF on the healing of intraoperatively irradiated bowel anastomoses. *J Exp Clin Cancer Res* 2004;23:421-6.
 34. Dinc S, Gulcelik MA, Kuru B, Ergeneci D, Camlibel M, Caydere M, et al. The effects of locally applied GM-CSF on ischemic bowel anastomosis. *Eur Surg Res* 2004;36:59-63.
 35. Koruda MJ, Rolandelli RH. Current research review experimental studies on the healing of colonic anastomoses. *J Surg Res* 1990;48:504-15.
 36. Phillips JD, Kim CS, Fonkalsrud EW, Zeng H, Dindar H. Effects of chronic corticosteroids and vitamin A on the healing of intestinal anastomosis. *Am J Surg* 1992;163:71-7.
 37. Fatouros MS, Vekinis G, Bourantas KL, Mylonakis EP, Scopelitou AS, Malamou-Mitsis VD, et al. Influence of growth factors erythropoietin and granulocyte macrophage colony stimulating factor on mechanical strength and healing of colonic anastomoses in rats. *Eur J Surg* 1999;165:986-92.
 38. de Waard WD, Wobbles T, van der Linden CJ, Hendriks T. Retinol may promote fluorouracil-suppressed healing of experimental intestinal anastomoses. *Arch Surg* 1995;130:959-65.
 39. Seiler C, Pohl T, Wustmann K, Hutter D, Nicolet PA, Windecker S, et al. Promotion of collateral growth by granulocyte-macrophage colony-stimulating factor in patients with coronary artery disease. *Circulation* 2001;104:2012-7.