

THE PROTECTIVE EFFECTS OF TETRANDRINE AGAINST TO HISTOLOGICAL, SPERMATOLOGICAL AND OXIDATIVE DAMAGE INDUCED BY AROCLOR 1254 ON THE MALE RATS REPRODUCTIVE SYSTEM

ERKEK SIÇANLARDA AROKLOR 1254'ÜN NEDEN OLDUĞU REPRODUKTİF HASARA KARŞI TETRANDRİNİN KORUYUCU ETKİLERİNİN ARAŞTIRILMASI

Feride ÖZDEMİR¹, Aslı ÇETİN TAŞLIDERE², Osman ÇİFTÇİ³, Muhterem AYDIN⁴, Neşe BAŞAK TÜRKMEN⁵

¹Istanbul University, Institute of Graduate Studies in Health Sciences, Department of Histology and Embryology, Istanbul, Türkiye

²Inonu University, Faculty of Medicine, Department of Histology and Embryology Malatya, Türkiye

³Pamukkale University, Faculty of Medicine, Department of Pharmacology Denizli, Türkiye

⁴Firat University, Faculty of Veterinary Medicine, Department of Reproduction and Artificial Insemination, Elazığ, Türkiye

⁵Inonu University Department of Pharmaceutical Toxicology, Faculty of Pharmacy, Malatya, Türkiye

ORCID ID: F.Ö. 0000-0003-1327-9146; A.Ç.T. 0000-0003-3902-3210; O.Ç. 0000-0001-5755-3560; M.A. 0000-0002-6494-9229; N.B.T. 0000-0001-5566-8321

Citation/Atf: Ozdemir F, Cetin Taslidere A, Ciftci O, Aydin M, Basak Turkmen N. Journal of Advanced Research in Health Sciences 2023;6(1):80-87. <https://doi.org/10.26650/JARHS2023-1181839>

ABSTRACT

Objectives: Aroclor (AR) 1254; has many adverse effects on male reproduction such as carcinogenic, teratogenic, immune and endocrine disruption problems. Tetrandrine (TET), a bisbenzillisoquinoline alkaloid isolated from the root of *Stephania tetrandra* S. Moore, has protective effects such as immunomodulatory, anti-cancer, and anti-inflammatory. The objective of this study was to investigate the possible curative effects of TET therapy against testicular damage (histological, spermatological and oxidative damage) induced by AR1254.

Materials and Methods: Twenty-eight male rats were randomly divided into four equal-sized groups: a control group; (1 ml of corn oil by gastric oral gavage), AR1254 group; (2 mg/kg) AR1254 administered intraperitoneally), TET group; (TET by gastric oral gavage 30 mg/kg) and AR 1254 + TET group;(Aroclor 1254 and TET administered together at the same doses as the previous groups.

Results: The AR1254 treatment caused morphological and spermatological damage on testis tissue; oedema vacuolization and congestion, in interstitial area, reduction in spermatogenic cells, arrested spermatocytes at different stages of spermatogenesis, shedding of spermatogenic serial cells into tubular lumens, a decline in epididymal sperm concentrations, sperm motility and a rise in abnormal sperm ratios. The AR1254 administration induced an increase in the oxidative parameters and a decrease in enzymatic and nonenzymatic antioxidant levels. The TET treatment significantly ameliorated histological, oxidative, and sperm damage caused by AR1254.

Conclusion: This study demonstrated the protective effects of TET against AR1254-induced male rat reproductive damage.

Keywords: Aroclor1254, testis, tetrandrine, rat, caspase-3

ÖZ

Amaç: Aroklor (AR) 1254; Kanserojenik, endokrin bozucu, nörotoksik, immünsüpresif, teratojenik etkileri olan poliloklorlu bifenil bileşiğidir. *Stephania tetrandra* S. Moore'un kökünden izole edilen bir bisbenzillisoquinolin alkaloid olan Tetrandrin (TET) ise immünomodülatör, anti kanser, anti-inflamatuar etkilere sahiptir. Bu çalışma, AR1254'ün neden olduğu testis hasarına (histolojik, spermatolojik ve oksidatif hasar) karşı TET tedavisinin koruyucu, iyileştirici etkilerini göstermek amacıyla planlandı.

Materyal ve Metot: Çalışmamızda 28 adet Sprague-Dawley cinsi siçanlar kullanıldı ve rastgele seçilerek 4 gruba ayrıldı. (n=7) Gruplar sırasıyla: Kontrol grubu; (1 ml mısır yağı gastrik gavaj ile), AR1254; (2 mg/kg/gün intraperitoneal yolla), TET grubu 30 mg/kg/gün gastrik gavaj ile), AR1254+TET grubu; Aroclor1254 ve TET grubuna uygulan dozlar aynı şekilde uygulanarak oluşturuldu. Deney süresi sonunda siçanlardan alınan testis dokuları histopatolojik ve biyokimyasal yöntemlerle analiz edildi.

Bulgular: AR1254 uygulaması sonucunda siçan testis dokusunda interstisyel alanda; vakuolizasyon, ödem, vasküler konjesyon, spermatogenik hücrelerde; azalma, bölünmenin herhangi bir evresinde duraksama ve lümen dökülme, epididimal sperm konsantrasyonunda, sperm hareketliliğinde azalma ve anormal sperm oranlarında ise artış gözlemlendi. AR1254 uygulaması oksidatif stres parametrelerinde artışa ve buna karşılık antioksidan seviyelerinde ise azalışa sebep oldu. Uygulanan TET tedavisi, AR1254'ün neden olduğu histolojik, oksidatif ve sperm hasarını önemli ölçüde iyileştirdi.

Sonuç: Bu çalışmada, erkek siçanlarda AR1254 ile oluşturulan testis dokusu hasarına karşı TET'in koruyucu ve iyileştirici etkileri gösterildi.

Anahtar kelimeler: Aroklor1254, testis, tetrandrin, siçan, kaspaz-3

Corresponding Author/Sorumlu Yazar: Feride ÖZDEMİR E-mail: feridekarahan1@gmail.com

Submitted/Başvuru: 29.09.2022 • **Revision Requested/Revizyon Talebi:** 18.10.2022 • **Last Revision Received/Son Revizyon:** 25.11.2022

• **Accepted/Kabul:** 25.11.2022 • **Published Online/Online Yayın:** 09.02.2023



This work is licensed under Creative Commons Attribution-NonCommercial 4.0 International License

INTRODUCTION

Polychlorinated biphenyls (PCBs) are chlorine compounds with the formula $C_{12}H_{10-x}Cl_x$ which are the most permanent in nature among all known chemicals (1). Owing to their excellent physicochemical properties of stability, unflammability, vis-cosity and electrical insulation, they are used in the production of capacitors, transformers, hydraulic pumps, printing ink, paints, pesticides and electrical insulating liquids (2). It is known that they tend to accumulate in the food chain and fatty tissues due to their lipophilic properties and cause environmental contamination and threaten human health (3,4). PCBs are taken into the body through the respiratory system and gastrointestinal tract and transferred through the blood to the liver and other organs (5). The carcinogenic, immune suppressor, neurotoxic, hepatotoxic and teratogenic effects of PCBs and their disruptive effects on the endocrine system have been shown in previous studies (2, 5) PCBs cause endocrine disorders by mimicking steroid hormones such as estrogen. Thus, they accumulate in steroid producing organs such as adrenal glands, testes, and ovaries (6).

Aroclor 1254 which is a mixture of PCBs, is one of the common factors causing environmental pollution. Many previous studies demonstrated that AR1254 has detrimental effects on the male reproductive system (7). An exposure to AR1254 can cause dysregulation in gonadotropin and steroid hormone levels, metabolic dysfunction in Sertoli cells, decreased luteinizing hormone (LH) receptor density and steroidogenic enzyme activity in Leydig cells, and a decrease in weight of testis and male accessory glands (7-10). In addition, it can cause a decline in sperm motility and quality (9, 11) and deterioration may occur in testicular tissue (12,13).

Tetrandrin is an alkaloid isolated from the Radix Stephania tetrandra plant which is used for traditional Chinese medicine (14, 15). TET has anti-inflammatory, immunomodulator, antioxidant, anti-cancer and anti-apoptotic effects and it is defined as a calcium-channel blocker. It has been reported that Tetrandrin showed its apoptotic effects in cancer cells by activating death receptors and FAS ligand. Also it has been shown that Tetrandrine activates caspase -3 to induce apoptosis in hepatic stellate cells (16, 17). Chemotherapeutic agents which are used as the main treatment method against cancer, cause lots of damage in human beings such as fertility problems, nerve and muscle problems and weight changes. Plant species have been used in medicine for many years. Because of the side effects of chemotherapeutic agents used in cancer treatments, today's studies focus on plant -drug therapy.

As a result this study planned to investigate possible curative effects of TET treatment on AR1254 induced testicular damage in rats. For this purpose, histological damage, morphologic changes, oxidative stress and sperm parameters were evaluated.

MATERIALS AND METHODS

Chemicals

Aroclor 1254 (ampule of 50 mg, CAS No:11097- 69-1), Tetrand-

rine (CAS No: 518-34-3) and the other complementary chemicals were obtained from Sigma-Aldrich Chemical Co. (St. Louis, MO, USA).

Animals

Twenty eight healthy adult male Sprague Dawley rats, (3–4 months, 200-250 g) were obtained from the Experimental Animal Institute (Malatya, Turkey). Animals were fed ad libitum with standard laboratory pellet chow and kept under standard conditions. This study was approved by Inonu University,- The Institutional Animal Ethical Committee- (Malatya, Turkey). (Date: 28 January 2014 and Protocol no: 2014/A-01)

Experimental Design

We determined the doses of Aroclor 1254 (AR1254) and tetrandrine (TET) based on previous studies. In these studies, AR1254 was intraperitoneally (i.p.) given to the rats at the dose of 2 mg /kg/day (6, 13, 18). and TET was given to the rats at dose of 30 mg/kg/day (19, 20).

All Sprague Dawley rats were randomly divided into four groups as control (n=7), AR1254 (n=7), TET (n=7) and AR1254+TET(n=7) groups in this study.

1 ml of corn oil (the solvent of AR1254 and TET) was administered by gastric oral gavage to the control group;

AR1254 was administered intraperitoneally (i.p) (2mg/kg/day) to the AR1254 group.

TET was administered 2mg/kg/day with gastric oral gavage (30 mg/kg/day) to the TET group.

AR1254 was administered i.p. (2mg/kg/day) and TET was administered 30mg/kg/day with gastric oral gavage to the AR1254 +TET group.

At the end of the experimental protocol (four weeks) all rats were anesthetized (mixture of ketamine hydrochloride). The left and right testis tissue samples were removed for biochemical and histopathological analysis.

Light Microscopic Examinations

For light microscopic evaluation, testis tissue samples in all groups were fixed in 10% neutral formaldehyde embedded in paraffin and sectioned apart. Hematoxylin and eosin (H&E) staining were applied on sections mounted on a slide. All testis tissue samples were analyzed with a light microscope and an image analysis system (Leica). The seminiferous tubule diameters and germinal epithelial thickness were measured by counting 100 seminiferous tubules. The tubule diameters were determined by taking micrographs at 20x magnification and taking the average of the horizontal and vertical diameters of the round tubules on the screen. The tubular epithelial thickness was determined by randomly selecting three regions of the intratubular epithelium in each micrograph at 20x magnification and taking the average of these three values for each tubule (Table 1). For Histological scoring 10 different areas were examined and intact seminiferous tubules, atrophic, and degenerated tubules were evaluated (Table 2).

Table 1: Tubular diameter and germinal layer thickness measurements after administration of AR1254 and/or TET in study groups

Groups	Tubule diameter	Tubular epithelium thickness
Control	303.45±2.99 ^a	80.18±0.66 ^a
AR 1254	267.56±2.44 ^b	53.57±0.64 ^b
TET	299.62±3.39 ^a	78.94±0.71 ^a
AR1254 + TET	287.24±3.18 ^c	69.37±0.62 ^c

^a: There was no difference between control and TET, ^b: Shows that AR1254 differs from all groups. ^c: Shows that AR1254 + TET differs from all groups (p<0.0001)

Table 2: Proportion of normal, degenerated and atrophic seminiferous tubules after AR1254 and/or TET administration in study groups

Groups	Normal	Degenerate	Atrophic
Control	3.33±0.09 ^a	0.15±0.05 ^a	0.38±0.06 ^a
AR 1254	0.17±0.05 ^b	0.40±0.08 ^b	3.88±0.14 ^b
TET	2.68±0.07 ^c	0.18±0.05 ^c	0.65±0.08 ^c
AR 1254 + TET	1.85±0.12 ^d	0.33±0.07 ^d	1.13±0.10 ^d

^a: There was no difference between control and TET, ^b: Shows that AR1254 differs from all groups. ^c: Shows that TET differs AR1254, and AR1254+TET groups, ^d: Shows that AR1254 + TET differs from all groups (p<0.0001)

Immunohistochemical analysis

After deparaffinization and rehydration procedures, slides were boiled in the citrate buffer (pH 7.6) and washed with phosphate-buffered saline (PBS). Respectively, sections were incubated in 3% H₂O₂, (7 min) primer antibody (caspase-3-) (2 hours), Biotinylated Goat Anti Polyvalent (10 min), streptavidin peroxidase (10 min) and chromogen (15 min) Then slides were applied with Mayer's hematoxylin (1 min) stained sections were analyzed with light microscope and an image analysis system (Leica).

Evaluation of sperm parameters

Testis, epididymis, seminal vesicle, and prostate tissues were removed, weighed and values of weights parameters and sperm parameters were evaluated in all groups.

The Hemocytometer method was used for determination of epididymal sperm concentration. The cauda epididymis was used for sperm motility evaluation (21). All epididymal sperm cells (200x magnification) and percentage of sperm motility (400x magnification) were evaluated using a light microscope (Leica). To evaluate the percentage motility score of sperm cells, the slides were stained with eosin-nigrosin (1.67% eosin, 10% nigrosin and 0.1M sodium citrate) and analyzed at 400x magnification. Three hundred spermatozoa were randomly selected on each slide and head, mid, tail and total morphologically abnormal spermatozoas ratios were presented as percentages (21, 22).

Biochemical Analyses

Homogenized testis tissues were used for biochemical parameters. For determination of TBARS levels, testis tissues were evaluated spectrophotometrically at 532 nm (23). The reduced glutathione (GSH) level was measured at 412 nm (24). Catalase (CAT) activity was determined using the method defined by Aebi et al. (25). The superoxide dismutase (SOD) activity was determined using the method defined by Sun et al. (26). The SOD activity was evaluated by the nitroblue tetrazolium (NBT) method and measured by spectrophotometer at 560 nm. For determination of the glutathione peroxidase activity (GPx) the Beutler method was used (27). The GPx activity measured spectrophotometrically at 340 nm.

Statistical analysis

Histological values were analysed using the SPSS 13 statistical program. Since our data are suitable for non-normal distribution, we used the Kruskal–Wallis test for comparison between groups. The significance of differences between the groups were evaluated by pair wise comparisons with the Mann-Whitney U test. All data were presented as the arithmetic mean ± standard error (SE), p ≤ 0.0001 were regarded as statistically significant.

Biochemical and Spermatological values were analysed using the “SPSS for Windows 12.0” statistical program. Since our data are suitable for non-normal distribution, we used the Kruskal–Wallis test for comparison between groups. The significance of differences between the groups were evaluated by pair wise comparisons with the Mann-Whitney U test. All data were presented as the arithmetic mean ± standard error (SE), p ≤ 0.05 were regarded as statistically significant.

RESULTS

Histological results

Hematoxylin and eosin applied testis tissue sections in all groups were evaluated in general morphology. In both the control and TET group; seminiferous tubule's interstitial cells and germinal epithelium, exhibited normal histological appearances as shown in Figure (1A, 1B). However, in the AR1254 group histopathological lesions such as tubular degeneration, vascular congestion in tunika albuginea layer and interstitium Figure (1C, 1D), vacuolisation Figure (1E) interstitial oedema, tubular degeneration Figure (1F), reduction in spermatogenic cells, Figure (1G), and arrested spermatocytes at different stages of spermatogenesis Figure (1H) were observed. The TET treatment showed ameliorative effects on the AR1254 induced testes toxicity Figure (1I, 1J, 1K, 1L). Histopathological changes analyzed in the AR1254+TET group were milder than the AR1254 group. Compared with the AR1254 alone group, vascular congestion, interstitial oedema and vacuolisation, the rate of arrested spermatocytes in different stages of spermatogenesis and shedding of spermatogenic serial cells into tubular lumens were decreased markedly in the AR1254+TET group. Curative effects were observed in testicular tissues of all animals in the AR1254+TET group.

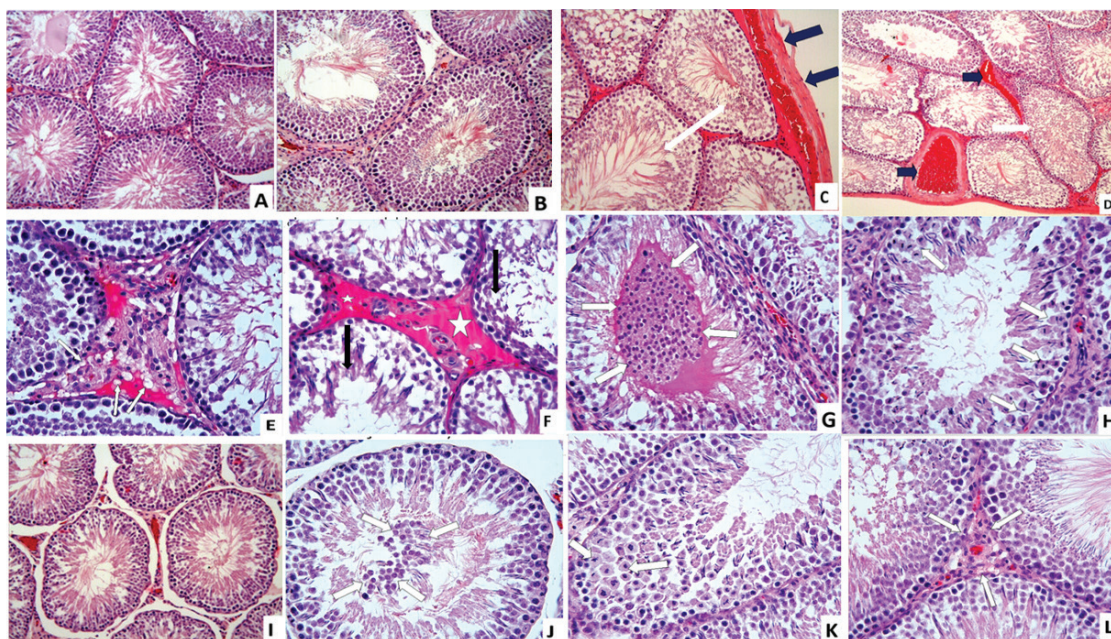


Figure 1: Testis tissue showed normal histological appearance in Control (A) and Tetrandrine (B) groups. Germinal epithelium, seminiferous tubules and interstitial cells exhibited normal histological appearances. H&E; X20 In AR1254 group (C-H) in testis tissue, vascular congestion in tunika albuginea and in interstitial area and deterioration in seminiferous tubules (white arrows) (C, D), vacuolization in the in interstitial area (white arrows) (E), interstitial oedema (white asteriks), and tubular degeneration (black arrows) (F), deterioration in the seminiferous tubule epithelium and shedding of spermatogenic serial cells into tubular lumens (white arrows) (G), arrested spermatocytes at different stages of spermatogenesis (H), C: H&E; x20. D: H&E; x10, E, F, G, H: H&E; X40. In TET+ AR1254 group (I-L) deterioration in seminiferous tubules, vascular congestion and oedema in interstitial area (I) shedding of spermatogenic serial cells into tubular lumens (white arrows) (J), the rate of arrested spermatocytes at different stages of spermatogenesis (white arrows) (K) and interstitial vacuolisation (white arrows) (L) was decreased markedly), A: H&E; x20., B, C, D: H&E; X40.

In morphometric measurements the germinal layer thickness and the tubular diameter of the control and TET groups did not exhibit any significant differences as shown Table 1. A significant decrease was observed in seminiferous tubule diameters of the

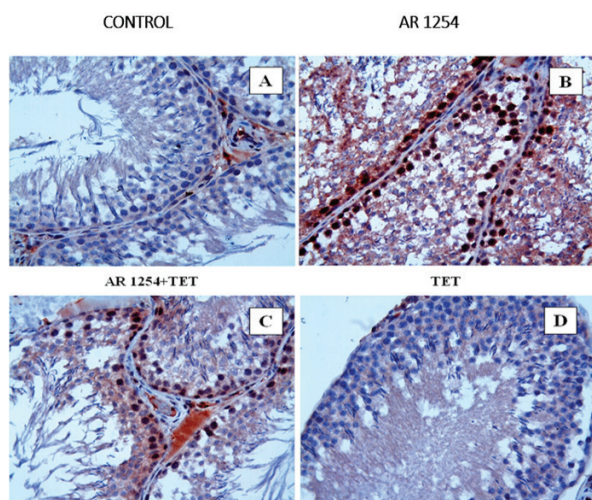


Figure 2: Caspase-3 immunoreactivity in seminiferous tubules of Control (A), AR 1254 (B), AR 1254+ TET (C) and TET (D) groups. Caspase-3; X40.

groups treated with AR1254 ($p < 0.0001$). TET reduced the morphometric effects of AR1254; with p -value of ($p < 0.0001$). Testicular seminiferous tubules were analyzed as intact (normal), degenerated, and atrophic tubules. The higher rates of atrophic tubules in the AR1254 group decreased significantly with TET treatment as shown in Table 2. Curative effects were observed in testicular tissues of all animals in the AR1254+TET group

Immunohistochemical results

Immunoreactivity of Caspase-3 in seminiferous tubule cells were evaluated. Caspase-3 positive cells were not detected in the TET and control groups. The intensity of caspase-3 positive cells was dramatically high in the AR1254 group. The ratio of immunoreactive caspase-3 positive stained cells was less in the AR1254 + TET group as indicated in Figure 2A,B,C,D.

Organ weights and sperm parameters

As shown in Table 3, there was no statistically significant difference in weight data among all groups (testis, epididymis, seminal vesicle, prostate tissues).

Sperm parameters in all groups were presented in Table 4. The results showed that AR1254 caused a decrease in epididymal sperm concentrations and sperm motility and an increase in abnormal sperm ratios. The TET treatment significantly increased

Table 3: Testis weights, epididymal weights, seminal vesicle weight and prostate weights in study groups

Groups	Testis weight (g)		Epididymal weight (g)		Seminal vesicle weight (g)	Prostate weight (g)
	Right	Left	Right	Left		
Control	1.285±0.02	1.307±0.03	0.615±0.03	0.571±0.04	1.419±0.09	0.486±0.03
AR1254	1.330±0.05	1.348±0.043	1.348±0.043	0.547±0.03	1.365±0.09	0.498±0.02
TET	1.350±0.04	1.362±0.02	1.362±0.02	0.509±0.01	1.224±0.10	0.430±0.03
AR1254 + TET	1.362±0.06	1.414±0.03	1.414±0.03	0.609±0.01	1.069±0.01	0.374±0.03

There was no statistically significant difference in weight data among all groups

Table 4: Epididymal sperm concentration, sperm motility and abnormal sperm rate in study groups

Groups	Sperm motility(%)	Epididymal sperm concentration (million g/tissue)	Abnormal sperm rate (%)		
			Head	Tail	Total
Control	85.73±2.08 ^a	234.50±8.48 ^a	4.57±0.29 ^a	4.42±0.29 ^a	9.00±0.37
AR1254	58.85±1.85 ^b	139.28±6.77 ^b	9.85±0.50 ^b	8.85±0.59 ^b	18.71±0.47
TET	92.85±1.48 ^a	301.78±5.28 ^c	4.57±0.29 ^a	4.14±0.45 ^a	8.71±0.68
AR1254 + TET	80.57±1.25 ^a	185.71±8.75 ^d	7.28±0.47 ^c	6.85±0.55 ^c	14.14±0.82

It shows the statistical difference (p≤0,01) between groups a,b,c and d in the same column.

sperm motility and concentration, but the ameliorative effect of on abnormal sperm ratios were not statistically significant.

Biochemical results

The biochemical parameters are presented in Table 5. As a result of oxidative damage, the testicular TBARS level was significantly increased in the Aroclor 1254 group. Administration of AR1254 caused a statistical decrease in the GPx, SOD, CAT and GSH levels. TET treatment resulted in a significant decrease in the TBARS level and an increase in the GPx SOD, CAT and GSH levels in the TET +AR1254 group. There was no statistical difference in biochemical parameters between the control group and the TET group.

DISCUSSION

Water resources in the world have become a threat to human health depending on the behavior of people towards nature. Polychlorinated biphenyls, which are used in industry and agriculture, are transmitted into the environment by mixing sewage and chemical wastes into the water (6). Due to their persistence in nature and their accumulation in the fat tissue

of animals and humans, by contaminating the food chain, they pose many negative effects on nature and human health (28, 29).

In this study Aroclor 1254 was used as a toxic agent in order to induce testicular damage under experimental conditions. The ameliorative effects of TET on the reproductive system were investigated based on histological, spermatological and oxidative parameters to provide a novel pharmacological perspective in attempts to promote reproductive health.

Many studies have shown that AR 1254 and other PCB compounds cause reproductive damage through histological, spermatological and biochemical changes and damage to the testicular structures (9, 11, 30, 31). Hsu et al. demonstrated that PCBs led to a decrease in motility, concentration and sperm attachment to oocyte and penetration and an increase in abnormal sperm rate (30). Likewise, Erkekoglu P. et al showed that an AR1254 (15 mg/kg) injection resulted in a decrease in epididymal sperm concentrations, sperm motility and testis tissues weight (32). In another study, Moreno et al. reported an increase in sperm abnormalities and a significant reduction in sperm count in

Table 5: The levels of SOD, CAT, GPx, GSH and TBARS in testicular tissue of rat in study groups

	Control (Mean±SD)	AR1254 (Mean±SD)	TET (Mean±SD)	AR1254 + TET (Mean±SD)
TBARS(nmol/g tissue)	5.31±0.91 ^a	8.70±1.03 ^b	4.98±0.81 ^a	6.05±0.14 ^c
GSH (nmol/ml)	130.2±4.7 ^{ac}	89.6±5.2 ^b	143.1±6.1 ^a	125.8±4.5 ^c
CAT (k/mg protein)	0.034±0.005 ^a	0.019±0.002 ^b	0.039±0.007 ^a	0.024±0.003 ^d
SOD (U/mg protein)	42.1±2.01 ^a	24.6±2.69 ^b	39.9±1.97 ^a	33.6±2.41 ^c
GPx (U/mg protein)	247.1±23.2 ^a	171.4±19.1 ^b	219± 21.7 ^c	198.7±20.3 ^d

It shows the statistical difference (p≤0,01) between groups a,b,c in the same column

mice with AR 1254 (50/500 µg/kg) whereas there was no meaningful change in testicular and epididymal weights (33). Similarly, previous studies found that the administration of AR1254 caused a reduction in epididymal sperm concentration, sperm motility and increased abnormal sperm ratios and there was no statistically significant difference in testes, epididymis, seminal vesicle and prostate weights. In the AR1254+TET group, a remarkable increase in sperm quality, motility and concentration, and reduction in the abnormal sperm ratio (Head, tail, total) were observed. Administration of TET significantly ameliorated the toxicity of AR1254 in spermatogenesis.

It has been indicated in previous research that PCBs exposure led to morphological damage in testicular tissues (12, 13, 33, 34). Jia X et al. showed that; AR1254 administration in rats (1 or 3mg/kg 21 days) and primer culture Sertoli cells (5 or 10µg/ml - 48h) could cause the blood–testis barrier disruption via p38 MAPK pathway (34). Sangalang et al. indicated that AR 1254 led to histopathological damages such as disorganization in testicular lobules and spermatogenic cells, reduction of spermatogenesis, fibrosis and necrosis of the lobule walls (35). Oskam et al. reported that degenerative seminiferous tubules, decrease in seminiferous epithelial thickness, increase in intercellular spaces, and deterioration in spermiogenesis and cells with pycnotic nuclei in testicular tissue (36). In addition, Ateşşahin et al. reported a reduction in spermatogenic cells, degeneration, desquamation, disorganization, interstitial oedema and congestion in seminiferous tubule of rats treated with AR 1254 (13). Consistent with the findings of previous studies, this research observed that tubular degeneration and reduction in spermatogenic cells, arrest spermatocytes at different stages of spermatogenesis, the shedding of spermatogenic serial cells into tubular lumens, vascular congestion in tunika albuginea layer and interstitium, interstitial oedema and vacuolization in testis tissue were induced with AR1254 administration. Moreover this study observed that AR 1254 administration caused a decrease in tubular diameter and tubular epithelial thickness similar to Ateşşahin et al findings (13). In the AR1254+TET group, TET treatment significantly improved testicular damage. Tubular epithelial thickness and tubular diameter values increased significantly compared to the AR1254 group. The mechanism underlying the therapeutic effects of TET on testicular tissue is not yet clear, but it may be related to inducing autophagy and cell cycle arrest, inhibiting oxidative stress, improving metastasis and suppressing tumor cell growth (37).

Apoptosis is a physiological process of cell death that plays a crucial role in homeostasis. Apoptosis is characterized by DNA fragmentation, nuclear fragmentation, chromatin condensation, and cell shrinkage. Although apoptosis is thought to be a homeostatic mechanism for maintaining cell populations in tissues, previous studies have shown that many factors are involved in this process, including reactive oxygen species, death factors, and toxic agents. The imbalance of these factors leads to the formation of autoimmune diseases, neurodegenerative diseases and many types of cancer (38). Mitochondrial damage from oxidative stress, a potent mediator of apoptosis, causes

cytochrome C release, caspase activation, and apoptotic death. Caspases initiate apoptosis by activating the proteolytic cleavage cascade. Caspase 3, a protease that is activated in the early stages of apoptosis, is one of 14 members of the caspase family (39). It is known that PCB 132 and AR1254 administrations increase pro-apoptotic molecules caspase-3 and caspase-9 activities in testicular tissue of rats (13, 30, 40). Studies have shown that TET initiates apoptosis by inducing caspase-3 activation in tumor cell lines. In vitro, administration of TET at high concentrations induces apoptosis in hepatocellular carcinoma cells, while administration at low concentrations stimulates autophagy and has an antitumor effect (41, 42). Apoptotic cells were evaluated by caspase-3 immunoreactivity in our study. Compared to AR1254+TET, the intensity of caspase-3- positive staining was higher in the AR1254 group. The decrease in the rate of apoptotic cells in the TET + AR1254 group can be explained by the inhibition of oxidative stress by TET.

Oxidative stress is defined as disruption of the balance between antioxidants and reactive oxygen species (ROS). The effect of the antioxidant system protects cells from damage caused by free radicals. TBARS, which formed as a result of peroxidation of lipid and causes damage to cells, is one of the most important markers of oxidative stress. Due to high content polyunsaturated fatty acids, testis tissue is under the effects of oxidative stress (43,44). It is known that antioxidant parameters such as SOD, CAT, GPx, GSH reduces free radicals and protects cells against adverse effects of lipid peroxidation. Previous studies showed that Ar1254 application causes an increment in TBARS level and reduction in CAT, SOD, GR, GPx and GSH activities in testis tissue (8, 9, 13, 45). It has also been reported that antioxidant treatments such as Vitamin E, vitamin C, quercetin, zinc, lycopene and ellagic acid in conjunction with the Aroclor administration reduce the level of TBARS and increase activities of CAT, GSH, GSH-Px and SOD (9, 13, 45 -47). Similarly to the findings of previous studies with Aroclor 1254 administration, we have observed remarkable increase in TBARS level and significant decrease in GSH, CAT, GSH-Px, SOD, levels. In the AR+TET group, TET reversed toxic damage of AR1254, TBARS level decreased, SOD, CAT, GSH-Px and GSH levels increased significantly. A review of literature indicated that, there are no previous studies focusing on the mechanism underlying the protective effect of TET against oxidative stress induced by AR1254 in testis tissue. However, it has been reported that TET, a calcium-channel blocker, inhibits lipid peroxidation in the heart, liver, pancreas and brain tissues, reduces the levels of reactive oxygen species (ROS), and suppresses the formation of cytokines and inflammatory mediator(17, 48-50). These findings correlate with the results of biochemical parameters evaluating oxidative stress in our study.

As a result, administration of AR1254 led to histopathological changes, increased apoptotic cells count, abnormal sperm ratios and decreased sperm concentrations and motility, which are caused by oxidative damage. TET treatment significantly reduced the disrupting effects of AR1254, due to its strong antioxidant, radical eliminating and anti-inflammatory properties.

The literature review process of this research indicated that no research has been conducted on the effects of TET on the male reproductive system. The results of this study suggested that TET treatment may be used against AR1254 induced male reproductive toxicity.

Ethics Committee Approval: This study was approved by Inonu University Faculty of Medicine Experimental Animal Research Ethics Committee (Date: 28.01.2014, No: 2014/A-01).

Author Contributions: Conception/Design of Study- F.Ö., A.Ç.T., O.Ç., M.A., N.B.T.; Data Acquisition- F.Ö., A.Ç.T., O.Ç., M.A., N.B.T.; Data Analysis/Interpretation- F.Ö., A.Ç.T., O.Ç., M.A., N.B.T.; Drafting Manuscript- F.Ö., A.Ç.T., O.Ç., M.A., N.B.T.; Critical Revision of Manuscript- F.Ö., A.Ç.T., O.Ç., M.A., N.B.T.; Final Approval and Accountability- F.Ö., A.Ç.T.; Material and Technical Support- F.Ö., A.Ç.T., O.Ç., M.A., N.B.T.; Supervision- F.Ö., A.Ç.T., O.Ç., M.A., N.B.T.

Peer Review: Externally peer-reviewed.

Conflict of Interest: Authors declared no conflict of interest.

Financial Disclosure: This research was financially supported by the Inonu University Scientific Research Projects Unit (No. 2013/11).

REFERENCES

- Lilienthal H, Fastabend A, Hany J, Kaya H, Roth-Härer A, Dunemann L, et al. Reduced levels of 1, 25-dihydroxyvitamin D3 in rat dams and offspring after exposure to a reconstituted PCB mixture. *Toxicol Sci* 2000;57(2):292-301.
- Carpenter DO. Polychlorinated biphenyls and human health. *Int J Occup Med Environ Health* 1998;11(4):291-303.
- Kamrin M, Ringer R. PCB residues in mammals: A review. *Toxicol Environ Chem* 1994;41(1-2):63-84.
- Carpenter DO. Environmental contaminants and human health: the health effects of persistent toxic substances. *Firat Med J* 2005;10(1):1-4.
- Kimbrough RD, Krouskas CA. Human Exposure to Polychlorinated Biphenyls and Health Effects. *Toxicol Rev* 2003;22(4):217-33.
- Mazen NF, Zidan RA. Histological study on the effect of aroclor 1254 on the epididymis of adult rats and the role of L-NAME administration. *Ultrastruct Pathol* 2017;41(2):154-67.
- Krishnamoorthy G, Murugesan P, Muthuvel R, Gunadharini D, Vijayababu M, Arunkumar A, et al. Effect of Aroclor 1254 on Sertoli cellular antioxidant system, androgen binding protein and lactate in adult rat in vitro. *Toxicology* 2005;212(2-3):195-205.
- Murugesan P, Kanagaraj P, Yuvaraj S, Balasubramanian K, Aruldas MM, Arunakaran J. The inhibitory effects of polychlorinated biphenyl Aroclor 1254 on Leydig cell LH receptors, steroidogenic enzymes and antioxidant enzymes in adult rats. *Reprod Toxicol* 2005;20(1):117-26.
- Aly HA, Domènech Ò, Abdel-Naim AB. Aroclor 1254 impairs spermatogenesis and induces oxidative stress in rat testicular mitochondria. *Food Chem Toxicol* 2009;47(8):1733-8.
- Ahmad SU, Tariq S, Jalali S, Ahmad MM. Environmental pollutant Aroclor 1242 (PCB) disrupts reproduction in adult male rhesus monkeys (*Macaca mulatta*). *Environ Res* 2003;93(3):272-8.
- Krishnamoorthy G, Venkataraman P, Arunkumar A, Vignesh R, Aruldas M, Arunakaran J. Ameliorative effect of vitamins (α -tocopherol and ascorbic acid) on PCB (Aroclor 1254) induced oxidative stress in rat epididymal sperm. *Reprod Toxicol* 2007;23(2):239-45.
- Alston DA, Tandler B, Gentles B, Smith EE. Testicular histopathology in deer mice (*Peromyscus maniculatus*) following exposure to polychlorinated biphenyl. *Chemosphere* 2003;52(1):283-5.
- Ateşşahin A, Türk G, Yılmaz S, Sönmez M, Sakin F, Çeribası AO. Modulatory effects of lycopene and ellagic acid on reproductive dysfunction induced by polychlorinated biphenyl (Aroclor 1254) in male rats. *Basic Clin Pharmacol Toxicol* 2010;106(6):479-89.
- Ruan L, Huang HS, Jin WX, Chen H-M, Li XJ, Gong Q-J. Tetrandrine attenuated cerebral ischemia/reperfusion injury and induced differential proteomic changes in a MCAO mice model using 2-D DIGE. *Neurochem Res* 2013;38(9):1871-9.
- Zhang J, Yu B, Zhang XQ, Sheng ZF, Li SJ, Wang ZJ, et al. Tetrandrine, an antihypertensive alkaloid, improves the sleep state of spontaneously hypertensive rats (SHRs). *J Ethnopharmacol* 2014;151(1):729-32.
- Yin M-F, Lian LH, Piao D-M, Nan J-X. Tetrandrine stimulates the apoptosis of hepatic stellate cells and ameliorates development of fibrosis in a thioacetamide rat model. *World J Gastroenterol* 2007;13(8):1214-20.
- Chen Y, Tsai YH, Tseng SH. The potential of tetrandrine as a protective agent for ischemic stroke. *Molecules* 2011;16(9):8020-32.
- Murugesan P, Muthusamy T, Balasubramanian K, Arunakaran J. Studies on the protective role of vitamin C and E against polychlorinated biphenyl (Aroclor 1254)—induced oxidative damage in Leydig cells. *Free Radic Res* 2005;39(11):1259-72.
- Zhong Z, Qian Z, Zhang X, Chen F, Ni S, Kang Z, et al. Tetrandrine prevents bone loss in ovariectomized mice by inhibiting RANKL-induced osteoclastogenesis. *Front Pharmacol* 2020;10:1530.
- Lv Yi, Wu Zz, Chen Lx, Wu Bx, Chen Ll, Qin Gc, et al. Neuroprotective effects of tetrandrine against vascular dementia. *Neural Regen Res* 2016;11(3):454-59.
- Türk G, Sönmez M, Aydın M, Yüce A, Gür S, Yüksel M, et al. Effects of pomegranate juice consumption on sperm quality, spermatogenic cell density, antioxidant activity and testosterone level in male rats. *Clin Nutr* 2008;27(2):289-96.
- Ciftci O, Ozdemir I, Aydın M, Beytur A. Beneficial effects of chrysin on the reproductive system of adult male rats. *Andrologia* 2012;44(3):181-6.
- Yagi K. Simple assay for the level of total lipid peroxides in serum or plasma. *Free radical and antioxidant protocols: Methods Mol Biol*. Springer; 1998. DOI: p. 101-6. 10.1385/0-89603-472-0:10
- Ellman GL. Tissue sulfhydryl groups. *Arch Biochem Biophys* 1959;82(1):70-7.
- Aebi H. Catalase in vitro. *Methods in enzymology* 1984;105:121-6.
- Sun Y, Oberley LW, Li Y. A simple method for clinical assay of superoxide dismutase. *Clin Chem* 1988;34(3):497-500.
- Beutler E. Red cell metabolism: a manual of biochemical methods. 1984.
- Çakıroğulları GÇ, Seçer S. Poliklorlu Bifeniller ve Sucul Yaşam. *Ankara Üniversitesi Çevre Bilimleri Dergisi* 2011;3(1):73-88.

29. Ahlborg UG, Hanberg A, Kenne K. Risk assessment of polychlorinated biphenyls (PCBs): Document for Risk Assessment, Institute of Environmental Medicine, Stockholm, Sweden; 1992. pp. 46-58.
30. Hsu PC, Li MH, Guo YL. Postnatal exposure of 2, 2', 3, 3', 4, 6'-hexachlorobiphenyl and 2, 2', 3, 4', 5', 6-hexachlorobiphenyl on sperm function and hormone levels in adult rats. *Toxicology* 2003;187(2-3):117-26.
31. Hsu PC, Pan MH, Li LA, Chen CJ, Tsai SS, Guo YL. Exposure in utero to 2, 2', 3, 3', 4, 6'-hexachlorobiphenyl (PCB 132) impairs sperm function and alters testicular apoptosis-related gene expression in rat offspring. *Toxicol Appl Pharmacol* 2007;221(1):68-75.
32. Aydin S, Erkekoglu P, Başaran N, Kocer-Gumusel B. Impact of selenium status on Aroclor 1254-induced DNA damage in sperm and different tissues of rats. *Toxicol Mech Methods* 2018;28(4):252-61.
33. Lopes Moreno JM. Effect of Pcb's (Aroclor 1254) on spermatogenesis In Testis of Mouse 2009. pp.1-61. Available from: <http://www.portaldonhecimento.gov.br/bitstream/10961/67/1/EFFECT%20of%20PCBs%20%28AROCLOR%201254%29%20on%20Spermatogenesis%20in%20testis%20of%20mouse.pdf>
34. Jia X, Xu Y, Wu W, Fan Y, Wang G, Zhang T, et al. Aroclor1254 disrupts the blood–testis barrier by promoting endocytosis and degradation of junction proteins via p38 MAPK pathway. *Cell Death Dis* 2017;8(5):e2823-e. doi: 10.1038/cddis.2017.224
35. Sangalang G, Freeman H, Crowell R. Testicular abnormalities in cod (Gadus morhua) fed Aroclor 1254. *Arch Environ Contam Toxicol* 1981;10(5):617-26.
36. Oskam IC, Lyche JL, Krogenæs A, Thomassen R, Skaare JU, Wiger R, et al. Effects of long-term maternal exposure to low doses of PCB126 and PCB153 on the reproductive system and related hormones of young male goats. *Reproduction* 2005;130(5):731-42.
37. Luan F, He X, Zeng N. Tetrandrine: a review of its anticancer potentials, clinical settings, pharmacokinetics and drug delivery systems. *J Pharm Pharmacol* 2020;72(11):1491-512.
38. Elmore S. Apoptosis: a review of programmed cell death. *Toxicol Pathol* 2007;35(4):495-516.
39. Yang GS, Wang W, Wang YM, Chen ZD, Wang S, Fang JJ. Effect of cocaine on germ cell apoptosis in rats at different ages. *Asian J Androl* 2006;8(5):569-75.
40. Mathur PP, Huang L, Kashou A, Vaithinathan S, Agarwal A. Environmental toxicants and testicular apoptosis. *Open Reprod Sci J* 2011;3(1):114-24.
41. Liu C, Gong K, Mao X, Li W. Tetrandrine induces apoptosis by activating reactive oxygen species and repressing Akt activity in human hepatocellular carcinoma. *Int J Cancer* 2011;129(6):1519-31.
42. Gong K, Chen C, Zhan Y, Chen Y, Huang Z, Li W. Autophagy-related gene 7 (ATG7) and reactive oxygen species/extracellular signal-regulated kinase regulate tetrandrine-induced autophagy in human hepatocellular carcinoma. *J Biol Chem* 2012;287(42):35576-88.
43. Aitken RJ, Roman SD. Antioxidant systems and oxidative stress in the testes. *Adv Exp Med Biol* 2008;636:154-71.
44. Kaya K, Ciftci O, Aydin M, Cetin A, Basak N. Favourable effect of β-glucan treatment against cisplatin-induced reproductive system damage in male rats. *Andrologia* 2019;51(9):e13342. doi: 10.1111/and.13342
45. Banudevi S, Sharmila M, Murugesan P, Srinivasan N, Balasubramanian K, Aruldas M, et al. Effects of Vitamin C and E on PCB (Aroclor 1254) induced oxidative stress, androgen binding protein and lactate in rat Sertoli cells. *Reprod Toxicol* 2004;19(2):201-8.
46. Zhang YMC. Protective effect of quercetin on Aroclor 1254–induced oxidative damage in cultured chicken spermatogonial cells. *Toxicol Sci* 2005;88(2):545-50.
47. Venkataraman P, Sridhar M, Dhanammal S, Vijayababu M, Srinivasan N, Arunakaran J. Antioxidant role of zinc in PCB (Aroclor 1254) exposed ventral prostate of albino rats. *J Nutr Biochem* 2004;15(10):608-13.
48. Koh SB, Ban JY, Lee BY, Seong YH. Protective effects of fangchinoline and tetrandrine on hydrogen peroxide-induced oxidative neuronal cell damage in cultured rat cerebellar granule cells. *Planta Medica* 2003;69(6):506-12.
49. Li YY, Li XL, Yang CX, Zhong H, Yao H, Zhu L. Effects of tetrandrine and QYT on ICAM-1 and SOD gene expression in pancreas and liver of rats with acute pancreatitis. *World J Gastroenterol* 2003;9(1):155-59.
50. Hui SC, Chan TY, Chen YY. Tetrandrine inhibits lipid peroxidation but lacks reactivity towards superoxide anion and hydrogen peroxide. *Pharmacol Toxicol* 1996;78(3):200-1.