

COVID-19 case with prolonged neutropenia

Uzamış nötropenili COVID-19 vakası

Nilüfer Yiğit, Başak Ünver Koluman, Erhan Uğurlu, Göksel Altınışık Ergur

Gönderilme tarihi:01.11.2021

Kabul tarihi:31.01.2022

Abstract

In this article, we present the follow-up and treatment process of neutropenia, which develops during COVID-19 infection in a healthy adult and lasts for approximately 45 days. When the patient applied with the complaints of weakness and joint pain, the PCR test was positive and neutropenia and lymphopenia were detected in the laboratory examination. Granulocyte-Colony Stimulating Factor (G-CSF) treatment was started in order to prevent the development of secondary infection to the patient, who was evaluated for additional medical treatment for neutropenia while the COVID-19 treatment was continuing. However, it was observed that neutropenia returned to normal after 1.5 months. Neutropenia secondary to COVID-19 infection can be seen in healthy adults and it is thought that the use of G-CSF in the treatment will be beneficial.

Key words: COVID-19, G-CSF, neutropenia.

Yiğit N, Ünver Koluman B, Uğurlu E, Altınışık Ergur G. COVID-19 case with prolonged neutropenia. Pam Med J 2022;15:391-394.

Öz

Bu yazıda sağlıklı bir erişkinde COVID-19 enfeksiyonu sırasında gelişen ve yaklaşık 1,5 ay devam eden nötropeni tablosunun takip ve tedavi sürecini sunuyoruz. Halsizlik ve eklem ağrısı şikayeti ile başvurusunda pcr pozitifliği ve laboratuvar incelemesinde nötropeni, lenfopeni saptanması ile COVID-19 tedavisi devam ederken nötropeni için ek medikal tedavi verilmesi açısından değerlendirilen hastaya sekonder enfeksiyonların gelişimini önlemek amacıyla G-CSF tedavisi başlandı. Yaklaşık 1,5 ay devam eden nötropeni durumu 1,5 ayın sonunda tamamen normale döndüğü görüldü. Sağlıklı erişkinde COVID-19 enfeksiyonuna sekonder nötropeni görülebilmektedir ve tedavide G-CSF kullanımının yararlı olacağı düşünülmektedir.

Anahtar kelimeler: COVID-19, G-CSF, nötropeni.

Yiğit N, Ünver Koluman B, Uğurlu E, Altınışık Ergur G. Uzamış nötropenili COVID-19 vakası. Pam Tıp Derg 2022;15:391-394.

Introduction

Neutropenia is the term used when the absolute neutrophil count falls below 1,500/ μ l. If the number of neutrophils is below 1.000-1.500/ μ l, it is classified as mild, if below 500-1000/ μ l, as moderate, if below 500/ μ l, severe and if below 200/ μ l it is classified as very severe neutropenia [1].

If the duration of neutropenia continues for less than 3 months, it is defined as acute neutropenia, if it lasts longer than 3 months, it is defined as chronic neutropenia. Post-infectious causes are seen as the acute form of neutropenia

due to acquired causes [1]. Viruses are the most common cause of postinfectious neutropenia [2, 3].

The data obtained from 15 published articles reflecting the value of blood cell count and different percentages of lymphocytes and neutrophils from severe / non-severe COVID-19 patients were evaluated collectively in a review. As presented, while lymphopenia is a prominent finding in most patients, some studies have reported an increased number of neutrophils [4].

In this case report example, unlike the literature, neutropenia developed during

Nilüfer Yiğit, Research Ass. Department of Chest Diseases, Faculty of Medicine, Pamukkale University, Denizli, Turkey, e-mail: nilufer_savurmus@hotmail.com (https://orcid.org/0000-0002-5871-6461) (Corresponding Author)

Başak Ünver Koluman, Ass. Prof. Department of Hematology, Faculty of Medicine, Pamukkale University, Denizli, Turkey; e-mail: basakunver@yahoo.com (https://orcid.org/0000-0003-1106-5021)

Erhan Uğurlu, Assoc. Prof. Department of Chest Diseases, Faculty of Medicine, Pamukkale University, Denizli, Turkey, e-mail: drerhanugurlu@gmail.com (https://orcid.org/0000-0001-5402-6925)

Göksel Altınışık Ergur, Prof. Department of Chest Diseases, Faculty of Medicine, Pamukkale University, Denizli, Turkey, e-mail: gaergur@gmail.com (https://orcid.org/0000-0001-6869-1301)

COVID-19 infection and granulocyte colony stimulating factor (G-CSF) applied in treatment will be mentioned.

Case

A 30-year-old female patient applies to the hospital with severe weakness and joint pain on November 23, 2020. The patient had no known chronic disease and was not smoker. Her arrival saturation was 98% at room air, the fever was 37.1°C, her blood pressure was 100/60 mm/Hg, and her pulse was 121/dk. Laboratory values are included in the table. Postero-anterior chest X-ray was normal (Figure 1). The patient's covid pcr test was positive. Hemoglobin was 11.1 g/dL, white cell count (WBC) $1.2 \times 10^9/L$ (neutrophils $0.64 \times 10^9/L$), and platelets $127 \times 10^9/L$. There was no atipic cell in peripheral blood smear, and coherent with neutropenia. She was hospitalized because of neutropenia. Favipiravir treatment was started. In the thorax CT, there were patched ground-glass areas in the lower zones bilaterally in the lungs (Figure 2). Because of neutropenia, she was consulted to hematology for additional recommendations. G-CSF (filgrastym) therapy was recommended to the patient by hematology. The patient received a single dose of 48 units of G-CSF therapy. Nausea, vomiting and diarrhea started during follow-up. The fever was 37.3°C

maximum. The neutrophil count was $4440/\mu l$ in the hemogram taken at the 24th hour of G-CSF treatment. The last peripheral blood smear was also evaluated by hematologists. There was presence of neutrophils in peripheral smear but appeared fragile. There were hyposegmented (hypolobulated) or bilobed neutrophil nuclei as known as pseudo Pelger-Huet anomaly. Hypogranulation of cytoplasm was also noted. The cytoplasm of neutrophils was pale. All these were dysplasia findings of neutrophils (Figure 3).

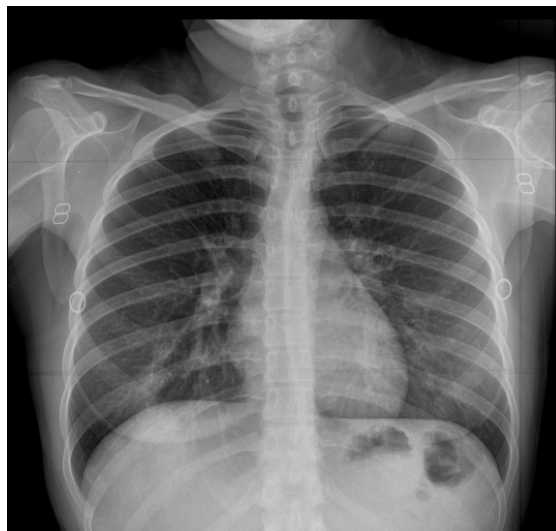

Figure 1. Postero-anterior chest X-ray was normal

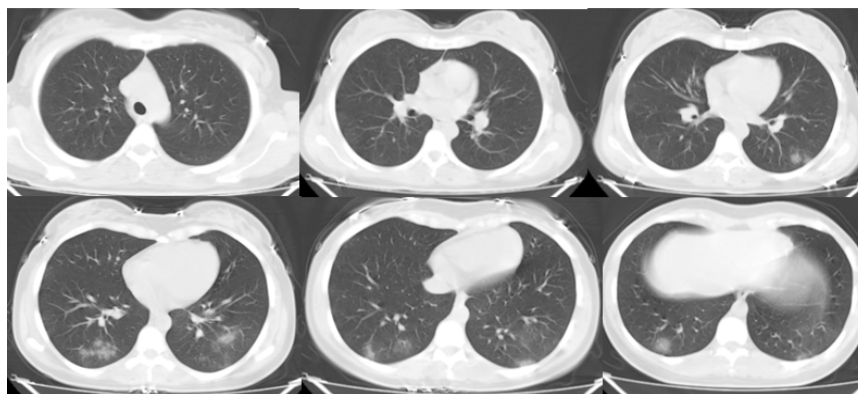


Figure 2. Patched ground-glass infiltrates in bilateral lower lobes in thorax CT

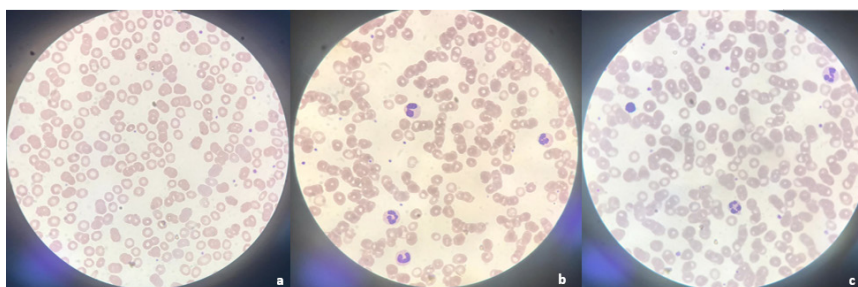


Figure 3a. Blood smear at diagnosis; **3b.** blood smear after initial G-CSF treatment; **3c.** blood smear after completion of treatment at the end of 45 days

Nausea and vomiting regressed on the 3rd day of treatment. The patient's oral intake improved. Daily hemogram follow-up continued. Gradual decrease in neutrophil values was observed. Absolute neutrophil count (ANC) decreased below 1000/ μ l level exactly four days after G-CSF treatment. Therefore, a second dose of G-CSF was given with the recommendation of hematology. The patient whose complaints regressed was discharged on the 7th day of hospitalization. Hemogram control was done once a week. In the following third and fourth weeks, two more G-CSF treatments were given because the neutrophil count was below 1000. It was decided to continue the follow-up without treatment as the number of neutrophils in the hemogram at the fourth week was 1300/ μ l. The patient reached a normal WBC ($4.33 \times 10^9/L$) and a normal ANC (2700/ μ l), at the end of the 5th week. Neutrophil morphology reached its healthy form at the end of the 5th week.

Discussion

Neutrophils are spectacular cells of body's immune system and prevent bacterial and fungal infections by phagocytosis and killing foreign invaders. A neutrophil count below 1,500 cells/ μ L is termed neutropenia, and it becomes clinically significant if the counts fall below 200, especially in immunocompromised patients [5]. Congenital causes are primary; acquired reasons creates secondary neutropenias. The cause of transient neutropenia can be broadly categorized into infectious and noninfectious causes. Among infectious causes, viral infections are the most common cause; however, bacterial and protozoal infections are also associated with neutropenia [5]. Most common viral agents include the Epstein-Barr virus, human immunodeficiency virus (HIV), influenza, parvovirus B19, and cytomegalovirus [6]. Although COVID-19 infection is a viral infection, neutropenia is not an expected condition.

However, decreased absolute lymphocyte count in peripheral blood combined with high neutrophil count has been a consistent observation in hospitalized COVID-19 patients [7]. But our case was different from the literature data. The patient had a neutropenia profile that lasted for about 5 weeks starting from her admission. Although there was a rapid increase in neutrophil values after each G-CSF

treatment, there was a decrease in neutrophil values afterwards.

The low neutrophil count is directly proportional to the infection risk and also the severity of the infection [8]. The rapid development and prolonged duration of neutropenia are other factors that increase the risk of infection. The prophylactic use of G-CSF reduces the risk of chemotherapy-induced neutropenia and its complications, including febrile neutropenia and infection-related mortality [9]. In recent publications, it is recommended to give prophylactic G-CSF treatment to prevent possible complications in cancer patients who receive chemotherapy, especially during the COVID-19 pandemic [10]. In line with the recommendations in the literature, we started G-CSF treatment for our patient in order to prevent the progression of the current infection and to eliminate the possibility of secondary infection that may develop. But there were two handicaps of increasing neutrophil count. Accumulation of neutrophils in the lung is known to be the hallmark of ARDS [11]. The late stages of COVID-19 are due to the patient's excessive immune response rather than the high viral load [12]. Therefore, G-CSF therapy may pose the risk of exacerbating the hyperinflammatory response induced by COVID-19 [13].

When all these possibilities are evaluated, the location of G-CSF therapy in neutropenic patients with COVID-19 infection is uncertain. However, its place in treatment will become clear with the studies and case examples to be conducted. In our case example, G-CSF treatment prevented the patient's neutropenia from deepening, helping to prevent possible secondary infection and avoid COVID-19 infection to progress.

Conflict of interest: No conflict of interest was declared by the authors.

References

1. Aydođdu S, Celik A, Karakas Z. Nötropeniye yaklaşım. *Çocuk Dergisi* 2015;15:3-9. <https://doi.org/10.5222/j.child.2015.003>
2. Husain EH, Mullah Ali A, Al Sharidah S, Azab AF, Adekile A. Infectious etiologies of transient neutropenia in previously healthy children. *Pediatr Infect Dis J* 2012;31:575-577. <https://doi.org/10.1097/INF.0b013e318250084a>

3. Sloand E. Hematologic complications of HIV infection. *AIDS Rev* 2005;7:187-196.
4. Pourbagheri Sigaroodi A, Bashash D, Fateh F, Abolghasemi H. Laboratory findings in COVID-19 diagnosis and prognosis. *Clin Chim Acta* 2020;510:475-482. <https://doi.org/10.1016/j.cca.2020.08.019>
5. Singh N, Lubana SS, Dabrowski L. Isolated chronic and transient neutropenia. *Cureus* 2019;11:e5616. <https://doi.org/10.7759/cureus.5616>
6. Newburger PE, Dale DC. Evaluation and management of patients with isolated neutropenia. *Semin Hematol* 2013;50:198-206. <https://doi.org/10.1053/j.seminhematol.2013.06.010>
7. Huang W, Berube J, McNamara M, et al. Lymphocyte subset counts in COVID-19 patients: a meta-analysis. *Cytometry Part A* 2020;97:772-776. <https://doi.org/10.1002/cyto.a.24172>
8. Celkan T, Şirin Koç B. Approach to the patient with neutropenia in childhood. *Turk Arch Pediatr* 2015;50:136-144. <https://doi.org/10.5152/TurkPediatriArs.2015.2295>
9. Vehreschild JJ, Böhme A, Cornely OA, et al. Prophylaxis of infectious complications with colony-stimulating factors in adult cancer patients undergoing chemotherapy-evidence-based guidelines from the Infectious Diseases Working Party AGIHO of the German Society for Haematology and Medical Oncology (DGHO). *Ann Oncol* 2014;25:1709-1718. <https://doi.org/10.1093/annonc/mdu035>
10. Tralongo AC, Danova M. Granulocyte colony-stimulating factors (G-CSF) and COVID-19: a double-edged sword? *Infez Med* 2020;28:459-460.
11. Potey PMD, Rossi AG, Lucas CD, Dorward DA. Neutrophils in the initiation and resolution of acute pulmonary inflammation: understanding biological function and therapeutic potential. *J Pathol* 2019;247:672-685. <https://doi.org/10.1002/path.5221>
12. Siddiqi HK, Mehra MR. COVID-19 illness in native and immunosuppressed states: a clinical-therapeutic staging proposal. *J Heart Lung Transplant* 2020;39:405-407. <https://doi.org/10.1016/j.healun.2020.03.012>
13. Lang FM, Lee KMC, Teijaro JR, Becher B, Hamilton JA. GM-CSF-based treatments in COVID-19: reconciling opposing therapeutic approaches. *Nat Rev Immunol* 2020;20:507-514. <https://doi.org/10.1038/s41577-020-0357-7>

Informed consent: Written informed consent was obtained from the patient.

Authors' contributions to the article

NY, BÜK constructed/constructed the main idea and hypothesis of the study.

NY, EU, GAE developed the theory and arranged/edited the material and method section.

NY, BÜK, EU have/have done the evaluation of the data in the results section

The discussion section of the article was written by NY, EU, GAE and BÜK have reviewed and approved the necessary corrections.

In addition, all authors discussed the entire study and approved the final version.