

Femoral bowing plane adaptation to femoral anteversion

Alp Akman, Fahir Demirkan, Nuran Sabir¹, Murat Oto, Cagdas Yorukoglu, Esat Kiter

ABSTRACT

Background: Femoral bowing plane (FBP) is the unattended subject in the literature. More over the femoral shaft with its bowing is neglected in established anteversion determination methods. There is limited information about the relationship between FBP and anteversion. Thus we focused on this subject and hypothesized that there could be an adaptation of FBP to anteversion.

Materials and Methods: FBP is determined on three-dimensional solid models derived from the left femoral computerized tomography data of 47 patients which were taken before for another reason and comparatively evaluated with anteversion. There were 20 women and 27 men. The mean age of patients was 56 years (range 21–84 years).

Results: The anteversion values were found as the angle between a distal condylar axis (DCA) and femoral neck anteversion axis (FNAA) along an imaginary longitudinal femoral axis (LFA) in the true cranio-caudal view. The FBP was determined as a plane that passes through the centre-points of three pre-determined sections on the femoral shaft. The angles between DCA, FNAA and FBP were comparatively evaluated. The independent samples *t*-test was used for statistical analysis. At the end, it was found that FBP lies nearly perpendicular to the anteversion axis for the mean of our sample which is around 89° in females and 93° in males (range 78–102°). On the other hand, FBP does not lie close to the sagittal femoral plane (SFP); instead, there is an average 12.5° external rotation relative to the SFP. FBP is correlated well with anteversion in terms of FBP inclination from SFP and femoral torsion (i.e., angle between FBP and femoral neck anteversion axis ($P < 0.001$; $r = 0.680$ and $r = -0.682$, respectively). Combined correlation is perfect ($R^2 = 1$) as the FBP, SFP, and posterior femoral plane forms a triangle in the cranio-caudal view.

Conclusions: We found that FBP adapts to anteversion. As FBP lies close to perpendicularity for the mean, femoral component positioning perpendicular to the FBP can be an alternate way in the replacement surgeries. In addition, it has been found that FBP lies externally rotated relative to the SFP.

Key words: Anteversion, anthropometry, bowing of femur, femoral bowing plane, human

MeSH terms: Femur, anatomy, anthropometry, computerized tomography, x-ray

INTRODUCTION

The femur is unique in large bones that has a natural bowing in the shaft region¹ and the normal shape of proximal femur is variable, and variations in the absence of intrinsic bone disease appear to reflect adaptation to physiologic variations due to the line of action of muscle forces.² In addition, there is normal torsion or twist which is named as femoral anteversion (anteversion).³ The

anteversion is defined as the angle between a distal condylar axis (DCA) and femoral neck anteversion axis (FNAA) along an imaginary longitudinal femoral axis (LFA) in the true cranio-caudal view.⁴⁻¹⁶ However, it seems that there is no consensus for the method of the determination of the anteversion in the literature.⁴⁻¹⁶ The DCA is most commonly defined as the axis that passes through the most posterior points of the lateral and medial epicondyles.^{4-10,12-16} But, Yoshioka and Cooke defined the transepicondylar axis instead.¹¹ The determination in the three-dimensional (3D) environment¹⁶ uses a plane instead of the DCA. The coronal femoral plane (CFP) passes through the previous DCA and the most posterior point of the greater trochanter. But, the angle measurement is as it was before. The FNAA is the

Departments of Orthopaedics and Traumatology and ¹Radiology, School of Medicine, Pamukkale University, Denizli, Turkey

Address for correspondence: Dr. Alp Akman,
 Department of Orthopaedics and Traumatology, School of Medicine,
 Pamukkale University, 20160 Kinikli, Denizli, Turkey.
 E-mail: alpakman@gmail.com

Access this article online	
Quick Response Code:	Website: www.ijoonline.com
	DOI: 10.4103/0019-5413.197219

This is an open access article distributed under the terms of the Creative Commons Attribution-NonCommercial-ShareAlike 3.0 License, which allows others to remix, tweak, and build upon the work non-commercially, as long as the author is credited and the new creations are licensed under the identical terms.

For reprints contact: reprints@medknow.com

How to cite this article: Akman A, Demirkan F, Sabir N, Oto M, Yorukoglu C, Kiter E. Femoral bowing plane adaptation to femoral anteversion. *Indian J Orthop* 2017;51:49-54.

line passes through the center points, but the definition of the center point of neck varies among studies.⁴⁻¹⁶ The LFA is always an imaginary axis in the previous studies and it is between a defined proximal point to another in distal which differs in each study.⁴⁻¹⁶ Furthermore, in a previous study, an “averaged” LFA in cases with significant bowing is calculated.⁸

Although femoral bowing gets very high attention in the literature for intramedullary nailing due to matching necessity of the intramedullary cavity and corresponding nail bowings, the femoral bowing plane (FBP) does not. To our knowledge, only Corten *et al.*^{17,18} have studied on it for the referencing for positioning of knee replacement. They studied on the determination of anteversion using FBP instead of the reference CFP using different algorithms. They found that it is comparable to the CFP for anteversion measurements and, the bisector method of determination of FBP is the most consistent method. However, they only reported the comparative anteversion values.

Thus, we decided to study on the relationship of CFP and FNAA with FBP in a comparative evaluation using 3D models created from computed tomography (CT) data in a sample of 47 subjects.

MATERIALS AND METHODS

The left femoral CT data of 47 patients, which were taken before for another reason, was used. For standardization, patients in whom the same protocols were used in preparation for the CT data were chosen (12 kV, 195 mAs). All CT data were composed of sequential 5 mm thick axial CT slices in a single field of view with a resolution of 512 × 512 pixels. In total, 47 consecutive patients were chosen among the patients who had no operations on the lower extremity or pelvis with no deformity or tumoral

lesions. Margin of error was between 0.1% and 0.2% in our angle measurements. This study was approved by the local Ethics Committee.

By using CT data, left femur models have been created by using Mimics® version 10 (Materialise, Leuven, Belgium) 3D modeling program. The minimum threshold was set to 226 Hounsfield Unit, which was also a predefined program threshold for the bone used and it was concordant with Kang *et al.*'s findings.¹⁹ A mask for each of the left femur was created and edited to effectively separate bones and filling missing points to define boundaries, as osteoporosis leads to defects in the proximal and distal femur region. A 3D solid model was then generated from this mask [Figure 1a].

To measure angles, first three planes and one 3D axis were established at specified points on the femur. The CFP was established with three-point determination between the medial condyle, the lateral condyle, and the greater trochanter at their most posterior points.⁴ Whereas the FNAA was between the femoral head center point and the center point of the femoral neck on its the narrowest segment and along its long axis as similar to a previous definition,²⁰ but the environment was 3D. The determination of FBP was similar to the previously defined bisector method by Corten *et al.*^{17,18} The FBP was established in three predetermined sections within the intramedullary cavity that was in concordance with a previous definition for 3D femur bowing analysis.²¹ A proximal section was located 2 cm below the lesser trochanter; a distal section was located 2 cm above the distal metaphyseal flare, and a center section at equidistance between distal and proximal sections. The junction points of the sagittal and coronal center points in each section were found. FBP was found based on three-point determination using these junction points. In addition, a sagittal femoral plane (SFP) was established

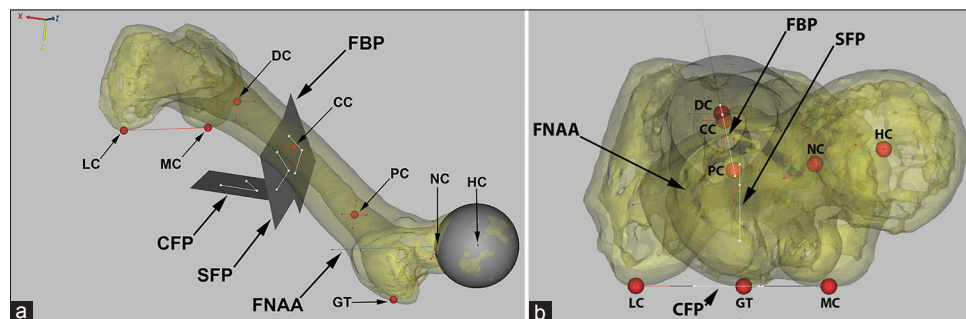


Figure 1: A created three-dimensional solid model of femur model with reference points, axes, and planes in three-dimensional space (a) and in cranio-caudal view (b). Condylar femoral plane is formed by joining the most posterior points of medial condyle, lateral condyle, and greater trochanter. Femoral neck anteversion axis passes through the femoral head center point circumference and the neck center point on its narrowest segment and along its long axis. Femoral bowing plane is formed by the center points of proximal section, center section, and distal section. Sagittal femoral plane is the plane which is perpendicular to condylar femoral plane along the femoral bowing plane. (FNAA: Femoral neck anteversion axis, CFP: Condylar femoral plane, FBP: Femoral bowing plane, SFP: Sagittal femoral plane, GT: Greater trochanter, MC: Medial condyle, LC: Lateral condyle, HC: Head center, NC: Neck center, PC: Proximal section center, CC: Center section center, DC: Distal section center)

as the plane that was perpendicular to the CFP along the FBP [Figure 1a and b].

At the final step, in the cranio-caudal view, the processed femur model was rotated until the FBP, CFP, and SFP become lines [Figure 1b]. If these three planes were seen as cross-hair lines on the screen, then it means that the femur was aligned perpendicular to the FBP, CFP, and SFP. The angle measured between CFP and FNAA was defined as anteversion, the angle between FBP and FNAA was defined as femoral bowing torsion (torsion), and the angle between CFP and FBP was defined as femoral bowing inclination (inclination). The inclination value was mathematically calculated using measured anteversion and torsion values as these two angles and “90° minus inclination,” as inclination, were defined relative to SFP, not to CFP that forms a triangle and their total value must be equal to 180° for each patient [Figure 2]. In addition, the axial length was measured as the distance between the deepest parts of piriformis fossa and intercondylar notch.

Each reference point and plane placement were checked and repeated 6 times/patient, and the highest and lowest readings were discarded. The average of 4 measurements was then used.

SPSS version 22 (IBM Corp., New York, USA) was used for statistical analysis. The closeness to normal distribution was evaluated by Lilliefors corrected Kolmogorov–Smirnov test and variance homogeneity by Levene test. Independent samples *t*-test was used for two group comparisons. Games–Howell test was used for *post hoc* analysis with Bootstrap results. Test correlations were done with Pearson’s correlation method. Correlation agreement indexes were

interpreted as follows: 0.81–1.00, perfect; 0.61–0.80, good; 0.41–0.60, moderate; 0.21–0.40, fair; and 0.00–0.20, poor agreement. Data were analyzed within 95% confidence interval and *P* < 0.05 was considered as significant.

RESULTS

All patients whose CT data was taken were adults. There are 20 women and 27 men (*n* = 47). The mean age of patients was 56 years (range 21–84 years). The ages did not differ by gender (*P* = 0.069). The mean axial shaft length of males was 39.6 cm, whereas it was 36.8 cm in females, which was significantly shorter (*P* = 0.008) [Table 1].

Our patients had a mean anteversion value of 10.74°. Although females had higher mean value than males, i.e., 13.15° in females and 8.96° in males, the difference was not statistically significant (*P* = 0.123). The mean inclination value was 12.46° which was similar in males and females (12.38° and 12.58°, respectively, *P* = 0.930). The mean torsion value was 91.72°, which is 89.43° in females and 93.42° in males. Gender difference was statistically significant unlike anteversion and inclination (*P* = 0.039) [Table 1]. These results showed us that gender affects torsion.

The comparative evaluation of anteversion with torsion showed us that there was a negative correlation between them (*P* < 0.001, *r* = -0.682). However, there was a positive correlation with inclination (*P* < 0.001, *r* = 0.680) [Table 2]. However, the combined correlation of torsion and inclination with anteversion was perfect (*R*² = 1).

By performing in-depth evaluation, we could mathematically explain this adaptation. As previously mentioned, total of the angles of anteversion, torsion, and PCP-FBP must be equal to 180° as they form a triangle in cranio-caudal view [Figure 2]. Thus, the equation was as follows:

$$180^\circ = \text{Anteversion} + \text{Torsion} + (90^\circ - \text{Inclination}).$$

If the equation was solved for

$$\text{Anteversion} = \text{Inclination} - (\text{Torsion} - 90^\circ).$$

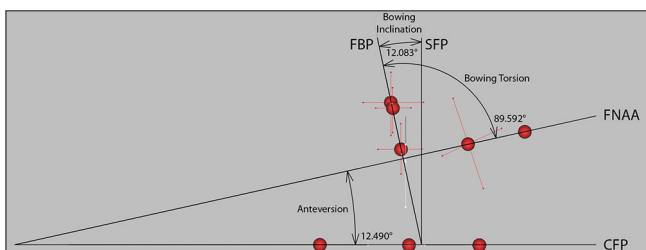


Figure 2: The illustration showing angle measurements

Table 1: The demographic characteristics of patients with measured angles

Parameter	Male (n=27)	Female (n=20)	Total (n=47)	<i>P</i> *
Age (year)	58.5±10.3 (21-76)	52.7±10.9 (40-84)	56.0±10.9 (21-84)	0.069
Axial length (mm)	395.9±36.6 (259.9-456.1)	368.1±29.5 (306.1-419.4)	384.0±36.2 (259.9-456.1)	0.008
Anteversion (°)	8.96±7.25 (-5.6-26.7)	13.15±9.70 (-2.8-29.1)	10.74±8.54 (-5.6-29.1)	0.123
Bowling torsion (°)	93.42±5.45 (78.2-102.4)	89.43±6.74 (78.5-100.2)	91.72±6.28 (78.2-102.4)	0.039
Bowling torsion difference** (°)	3.42±5.45 (-11.8-12.4)	-0.57±6.74 (-11.5-10.2)	1.72±6.28 (-11.8-12.4)	0.039
Bowling Inclination (°)	12.38±5.74 (-0.4-30.2)	12.58±7.06 (-2.9-28.7)	12.46±6.27 (-2.9-30.2)	0.930

All values are given in the form of mean±SD (range [minimum – maximum]), *Independent *t*-test (Bootstrap) for gender difference, **Bowling torsion - 90°, SD=Standard deviation

Table 2: Correlations with anteversion

Parameter	r	P
Axial length	-0.031	0.838
Bowing torsion	-0.682	<0.001
Bowing inclination	0.680	<0.001

Pearson's correlation test, r=Correlation coefficient

For our mean values, this equation was $10.7^\circ = 12.5^\circ - (91.8^\circ - 90^\circ)$.

The equation was further simplified if the difference of torsion from perpendicularity is taken into consideration. If we name this as bowing torsion difference from perpendicularity (difference) (i.e., Difference = Torsion - 90°.) we got:

Anteversion = Inclination - Difference.

Thus, we may say that FBP adapts to anteversion in terms of inclination and difference (or torsion) and for our mean values, this equation was $10.7^\circ = 12.5^\circ - 1.8$ for all subjects, $9^\circ = 12.4^\circ - 3.4^\circ$ for males, and $13.2^\circ = 12.6^\circ - (-0.6^\circ)$ for females.

DISCUSSION

When we look into the literature on anteversion measurements, there are little data studying differences in anteversion with gender and/or race. A mean anteversion value of 9.74° and 8.02° (7.94° in males and 8.11° in females) is reported before.^{4,22} In a study involving 48 pairs of normal cadavers in Norwegian population a mean version of 10.4° was found (10.2° in males and 10.7° in females).²³ They found no significant difference between sexes. In a study comparing Caucasians and Hong Kong Chinese, the anteversion angle averaged 7.08° in males and 10.8° in females among Caucasians versus an average of 14.08° in males and 16.8° in females among Chinese people.²⁴ A study involving the uninjured femur of 411 patients who were operated for femoral fracture found a mean anteversion of 8.85° (8.71° in males and 9.52° in females). The mean values of males were 7.92° for Caucasians, 8.96° for African-Americans, and 8.74° for Hispanics. These values were 12.91° , 8.19° , and 8.74° for females, respectively.²⁵ In a previous report from our country, 8.3° for right and 10.2° for left side mean anteversion values in a population of 85 people were reported (age range 40–81 years) with a history of knee pain, in which 80% of them were found to have no osteoarthritis.²⁶ In another study, 30 patients with osteoarthritis (age range 40–75 years) were compared with 29 control subjects (age range 19–75 years) and a mean anteversion value of 10.19° and 13.8° , respectively, was found.²⁷ Gender difference is not reported in these studies. The mean anteversion value is 10.74° , which is

8.96° for males and 13.15° for females in our study, thus our findings are comparable with the previous results, and gender difference is not significant. Our study differs from the previous studies as the LFA line becomes naturally defined without any assumptions, and averaging is not an issue.

Our results may have an impact on proper component positioning in total hip arthroplasty, which minimizes impingement.²⁸⁻³⁰ Hisatome and Doi³¹ stated that the best amount of femoral anteversion for the total hip stem has not been determined, although it is generally agreed to be between 10° to 20° and 10° to 30° , which are offering 10° and 20° variability ranges, respectively.^{32,33} Dorr *et al.*³⁴ stated that the surgeon's estimation of the anteversion of the stem still has a poor precision. The femoral component may be placed perpendicular to FBP which can be seen on careful inspection of femoral canal. In our sample, all patients are placed approximately between 78° and 102° in terms of torsion (12° antetorsion [values below 0°] and 12° retortorsion [values above 0°] in terms of difference) [Table 1]. With reference to our sample, our recommendation for femoral component positioning theoretically will result in that 79% of the patients will be in the $<10^\circ$ variation and 21% between 10° and 12° variation. However, for a final recommendation, we will need further prospective comparative studies. Another important point of this study may be prevention of malrotation after femoral nailing which continues as a problem despite preventive measures. The incidence of postoperatively detected malrotations of the femur is reported to be up to 47%.³⁵ The previous studies to control malrotation after femoral nailing inevitably involve positioning of distal locking screws parallel to PCA, which is named as "neutral" distal locking (NDL).³⁶⁻³⁸ NDL simulates anteversion measurement technique. As current femoral nails have distal locking screws perpendicular to their bowing,^{36,37} nail had to be positioned in the femoral canal with 0° inclination. One of the main findings of our study is that FBP lies approximately 12.5° externally rotated to SFP. Due to friction, flexible reamer and nail will tend to place closer to FBP. For no change in postoperative anteversion (POA), nail has to rotate in femoral canal to 0° inclination with NDL. Otherwise, fracture line rotates as you rotate distal fragment to achieve NDL, which may result in decrease of POA and/or external rotation deformity if not nail rotates within the intramedullary cavity. There are little data studying POA using NDL. In a previous controlled study done by Yang *et al.*³⁸ in Korean patients, NDL is performed with POA measurements. Asian people are known for high femoral shaft bowing in the coronal plane, which, in turn, points out high inclination.³⁹⁻⁴¹ After 43 nailing, unacceptable level of malrotation ($>10^\circ$) is

achieved in eight patients but resulted in increased POA with a mean of 21.8° (range 12–20°) (note: values are calculated from the given data). The increase in POA in their study may be attributed to nail rotation within the intramedullary cavity.

In long cephalomedullary nails, recon screw(s) or a blade is placed at 10–12° angle to the distal locking screw in the transversal plane.^{36,37} This anteversion value corresponds 78–80° in terms of torsion (10–12° antetorsion in terms of difference). Thus, centrally positioned recon screws or blade within the femoral head will compensate the effect of neutral distal locking. In fact, nail will realign in femur into its built-in anteversion value with FBP locking, if it rotates in the intramedullary cavity. The calculated value for POA in each patient of our study without nail rotation in intramedullary cavity confirms this. In the literature, there are just two technical trick definitions using ND. In the first study, the technique is defined but anteversion measurements are not included,³⁷ but in the second study,³⁶ it involved just three patients. The nail used in the second study had 12° inherent anteversion. In this study, the first patient had 18° anteversion at healthy side and he/she achieved 12° POA with 6° external rotation in side-to-side difference. In their second patient, they achieved 4° POA who had 17° anteversion at healthy side. The real deviation is reported as 12°, as they placed recon screws slightly anteriorly. They accepted their failure as they should internally rotate distal fragment by 8° and they accepted patient's rotational profile. In the third patient, the result was 8° with a healthy side of 8° with no side-to-side difference. Their difficulty in reaching into nail's built-in anteversion may be attributed to limited nail rotation within the intramedullary cavity. In addition, the placement of the FBP externally rotated relative to the SFP in addition to being near perpendicular relative to FNAA in our study can be another factor, which is not in concordance with the current intramedullary nail designs.

The main limitation of this study is small sample size. Furthermore, a wide range of age has been present. There may be a possibility of variation.⁴² The subjective nature of point selection for measurements of angles and its inherent error is another limitation. In addition, it is conceivable that reconstruction artifacts occur in the process of creating the 3D-CT models.²¹ However, 3D modeling method provides very accurate and reliable measurements of anteversion. It has no intrinsic source of method error because it is virtually equivalent to the direct measurement of the bisected dried femur *in vitro*. It does not make any difference whether the measurement is taken on an anatomical specimen or *in vivo*.¹⁶

CONCLUSIONS

It seems that FBP adapts to anteversion in terms of inclination and difference. We found that FBP lies close to perpendicular to FNAA for the mean in our sample. Femoral component positioning perpendicular to the FBP can be an alternate way. FBP can be seen on careful inspection of femoral canal. All patients in our study range approximately between 12° antetorsion to 12° retortorsion in terms of difference. This finding needs additional comparative studies for a definitive conclusion. In addition, we found that FBP lies approximately 12.5° externally rotated to SFP (i.e., inclination), which is not in concordance with the current intramedullary nail designs. We believe that further research needs to be done in this topic for clinical use and importance of FBP.

Financial support and sponsorship

Nil.

Conflicts of interest

There are no conflicts of interest.

REFERENCES

1. Walensky NA. A study of anterior femoral curvature in man. *Anat Rec* 1965;151:559-70.
2. Clark JM, Freeman MA, Witham D. The relationship of neck orientation to the shape of the proximal femur. *J Arthroplasty* 1987;2:99-109.
3. Cibulka MT. Determination and significance of femoral neck anteversion. *Phys Ther* 2004;84:550-8.
4. Kingsley PC, Olmsted KL. A study to determine the angle of anteversion of the neck of the femur. *J Bone Joint Surg Am* 1948;30A: 745-51.
5. Dunn DM. Anteversion of the neck of the femur; a method of measurement. *J Bone Joint Surg Br* 1952;34-B: 181-6.
6. Magilligan DJ. Calculation of the angle of anteversion by means of horizontal lateral roentgenography. *J Bone Joint Surg Am* 1956;38-A: 1231-46.
7. LaGasse DJ, Staheli LT. The measurement of femoral anteversion. A comparison of the fluoroscopic and biplane roentgenographic methods of measurement. *Clin Orthop Relat Res* 1972;86:13-5.
8. Ogata K, Goldsand EM. A simple biplanar method of measuring femoral anteversion and neck-shaft angle. *J Bone Joint Surg Am* 1979;61:846-51.
9. Jend HH. Computed tomographic determination of the anteversion angle. Premises and possibilities. *Rof* 1986;144:447-52.
10. Murphy SB, Simon SR, Kijewski PK, Wilkinson RH, Griscom NT. Femoral anteversion. *J Bone Joint Surg Am* 1987;69:1169-76.
11. Yoshioka Y, Cooke TD. Femoral anteversion: Assessment based on function axes. *J Orthop Res* 1987;5:86-91.
12. Høiseth A, Reikerås O, Fønstelien E. Aspects of femoral neck anteversion. Theoretical considerations and experimental results. *Acta Radiol* 1988;29:689-94.

13. Høiseth A, Reikerås O, Fønsteli E. Evaluation of three methods for measurement of femoral neck anteversion. Femoral neck anteversion, definition, measuring methods and errors. *Acta Radiol* 1989;30:69-73.
14. Lee DY, Lee CK, Cho TJ. A new method for measurement of femoral anteversion. A comparative study with other radiographic methods. *Int Orthop* 1992;16:277-81.
15. Tönnis D, Heinecke A. Acetabular and femoral anteversion: Relationship with osteoarthritis of the hip. *J Bone Joint Surg Am* 1999;81:1747-70.
16. Kim JS, Park TS, Park SB, Kim JS, Kim IY, Kim SI. Measurement of femoral neck anteversion in 3D. Part 1: 3D imaging method. *Med Biol Eng Comput* 2000;38:603-9.
17. Corten K, Jonkergouw F, Bartels W, Lenthe HV, Bellemans J, Simon JP, *et al.* Bowing of the Femur: A New Reference Plane for Axial Alignment of Total Knee Replacements. ORS Annual Meeting, Long Beach, CA, USA; 2011. Poster No. 1247. Available from: <http://www.ors.org/Transactions/57/1247.pdf>. [Last assessed on 2015 Aug 12].
18. Corten K, Jonkergouw F, Bartels W, Van Lenthe H, Bellemans J, Simon JP, *et al.* Bowing of the femur: A new reference plane for axial alignment of total knee replacements. *J Bone Joint Surg Br* 2012;94-B Suppl XL: 34. Available from: http://www.bjjprocs.boneandjoint.org.uk/content/94-B/SUPP_XL/34. [Last assessed on 2015 Aug 12].
19. Kang Y, Engelke K, Kalender WA. A new accurate and precise 3-D segmentation method for skeletal structures in volumetric CT data. *IEEE Trans Med Imaging* 2003;22:586-98.
20. Reikerås O, Bjerkeim I, Kolbenstvedt A. Anteversion of the acetabulum and femoral neck in normals and in patients with osteoarthritis of the hip. *Acta Orthop Scand* 1983;54:18-23.
21. Buford WL Jr., Turnbow BJ, Gugala Z, Lindsey RW. Three-dimensional computed tomography-based modeling of sagittal cadaveric femoral bowing and implications for intramedullary nailing. *J Orthop Trauma* 2014;28:10-6.
22. Toogood PA, Skalak A, Cooperman DR. Proximal femoral anatomy in the normal human population. *Clin Orthop Relat Res* 2009;467:876-85.
23. Reikerås O, Høiseth A, Reigstad A, Fønsteli E. Femoral neck angles: A specimen study with special regard to bilateral differences. *Acta Orthop Scand* 1982;53:775-9.
24. Hoaglund FT, Low WD. Anatomy of the femoral neck and head, with comparative data from Caucasians and Hong Kong Chinese. *Clin Orthop Relat Res* 1980;152:10-6.
25. Koerner JD, Patel NM, Yoon RS, Sirkin MS, Reilly MC, Liporace FA. Femoral version of the general population: Does "normal" vary by gender or ethnicity? *J Orthop Trauma* 2013;27:308-11.
26. Akalin Y, Ozçelik A, Köse N, Seber S. Rotational alignment of the lower extremity in adults: No relationship with osteoarthritis of the knee was proved. *Eklem Hastalik Cerrahisi* 2011;22:75-80.
27. Hapa O, Muratli HH, Cakici H, Gülçek S, Aksahin E, Biçimoglu A. Is there a relation between hip torsion, coverage and osteoarthritis of the knee? *J Child Orthop* 2009;3:27-31.
28. Widmer KH, Zurfluh B. Compliant positioning of total hip components for optimal range of motion. *J Orthop Res* 2004;22:815-21.
29. Yoshimine F. The safe-zones for combined cup and neck anteversions that fulfill the essential range of motion and their optimum combination in total hip replacements. *J Biomech* 2006;39:1315-23.
30. Malik A, Maheshwari A, Dorr LD. Impingement with total hip replacement. *J Bone Joint Surg Am* 2007;89:1832-42.
31. Hisatome T, Doi H. Theoretically optimum position of the prosthesis in total hip arthroplasty to fulfill the severe range of motion criteria due to neck impingement. *J Orthop Sci* 2011;16:229-37.
32. Emerson RH Jr. Increased anteversion of press-fit femoral stems compared with anatomic femur. *Clin Orthop Relat Res* 2012;470:477-81.
33. Botsler IB, Ozoude GC, Martin DE, Siddiqi AJ, Kuppuswami S, Domb BG. Femoral anteversion in the hip: Comparison of measurement by computed tomography, magnetic resonance imaging, and physical examination. *Arthroscopy* 2012;28:619-27.
34. Dorr LD, Wan Z, Malik A, Zhu J, Dastane M, Deshmane P. A comparison of surgeon estimation and computed tomographic measurement of femoral component anteversion in cementless total hip arthroplasty. *J Bone Joint Surg Am* 2009;91:2598-604.
35. Jiang X, Li X, Wang M, Gu X, Zhang B, Sun L, *et al.* Measurement of fracture malrotation after interlocking intramedullary nailing of femoral shaft fracture. *Zhonghua Wai Ke Za Zhi* 2002;40:55-8.
36. Espinoza C, Sathy AK, Moore DS, Starr AJ, Reinert CM. Use of inherent anteversion of an intramedullary nail to avoid malrotation in femur fractures. *J Orthop Trauma* 2014;28:e34-8.
37. Hoigné D, Hauck R, Babst R. Technique for intraoperative determination of femoral rotation with a lateral femur nail (LFN, Synthes, Oberdorf, Switzerland). *Arch Orthop Trauma Surg* 2011;131:1649-54.
38. Yang KH, Han DY, Jahng JS, Shin DE, Park JH. Prevention of malrotation deformity in femoral shaft fracture. *J Orthop Trauma* 1998;12:558-62.
39. Yau WP, Chiu KY, Tang WM, Ng TP. Coronal bowing of the femur and tibia in Chinese: Its incidence and effects on total knee arthroplasty planning. *J Orthop Surg (Hong Kong)* 2007;15:32-6.
40. Lasam MP, Lee KJ, Chang CB, Kang YG, Kim TK. Femoral lateral bowing and varus condylar orientation are prevalent and affect axial alignment of TKA in Koreans. *Clin Orthop Relat Res* 2013;471:1472-83.
41. Kim JM, Hong SH, Kim JM, Lee BS, Kim DE, Kim KA, *et al.* Femoral shaft bowing in the coronal plane has more significant effect on the coronal alignment of TKA than proximal or distal variations of femoral shape. *Knee Surg Sports Traumatol Arthrosc* 2015;23:1936-42.
42. Karakas HM, Harma A. Femoral shaft bowing with age: A digital radiological study of Anatolian Caucasian adults. *Diagn Interv Radiol* 2008;14:29-32.