

CASE REPORT

The Right Inferior Pulmonary Vein Related Inflammatory Myofibroblastic Tumor in an Adult Case*

Ümit Aydoğmuş¹, Erhan Uğurlu², Ferda Bir³, Figen Türk¹, Gökhan Yuncu¹

¹Department of Chest Surgery, Pamukkale University Faculty of Medicine, Denizli, Turkey

²Department of Chest Diseases, Pamukkale University Faculty of Medicine, Denizli, Turkey

³Department of Medical Pathology, Pamukkale University Faculty of Medicine, Denizli, Turkey

Abstract

Inflammatory myofibroblastic tumor (IMT) is a rare neoplasm, which is derived of mesenchymal origin. Here we present an adult case with IMT, the origin of which was considered to be right inferior pulmonary vein. A male patient who was 52 years old, admitted to our outpatient clinic with the complaint of shortness of breath. He had cigarette smoking history for 30 years. On direct posterior - anterior X-Ray of the chest, a well-circumscribed mass with calcification in right hilum of the lung was observed. There was a mass which was extending to the inferior inferior pulmonary vein from right hilum of the lung, was measured 70 x 60 mm on computed tomography of the chest. Hamartoma, teratoma and Castleman Disease were among the possible diagnoses. On diagnostic bronchoscopy, signs of pressure from outside to the bronchi of the right middle and lower lobe was observed. Surgical excision is decided and the mass was totally excised through a muscle-sparing thoracotomy. The mass thought to arise from the inferior pulmonary vein on intraoperative inspection and right inferior lobe excision is undertaken by intrapericardial approach. No postoperative complication is encountered. Histological examination of the mass indicated inflammatory myofibroblastic tumor. Main treatment of IMT is surgical excision with negative surgical margin. Here in we present an IMT which is encountered at an unexpected location is excised completely with right lower lobe excision by an intrapericardial approach.

KEYWORDS: Inflammatory myofibroblastic tumor, rare lung neoplasm, benign lung neoplasm

Received: 06.07.2015

Accepted: 14.10.2015

INTRODUCTION

Inflammatory myofibroblastic tumor (IMT) is a rare neoplasm of mesenchymal origin. As well as being located generally in the lungs of children and adolescents, it can be seen nearly everywhere in the body. Tumors of pulmonary and, more rarely, cardiac origin are seen in the adult period. Locally invasive and noninvasive forms have been defined for the ones located in the lungs[1].

This study aimed to present a case with IMT completely resected by thoracotomy, which was perhaps directly rooted from right inferior pulmonary vein (RIPV) and invaded the RIPV macroscopically, and to discuss diagnosis and treatment options in cases with IMT located in the thorax.

CASE PRESENTATION

A 52-year-old male patient presented to the chest disease clinic with a complaint of dyspnea. The patient had been smoking for thirty years. There was no previous disease in patient's history. Coarse rales were heard in the right lower zone on auscultation.

A smoothly-marginated lesion showing calcification in the right hilar region was seen on chest radiography (Figure 1A, B). A hypodense, smoothly-marginated mass, 70 x 60 mm in size, involving calcification and stretching out to the inferior pulmonary vein was seen on computed tomography (Figure 2). Findings of external pressure on mid-right and lower-right lobe were detected on bronchoscopy performed for probable diagnoses of hamartoma, teratoma and Castleman disease.

Biochemical evaluation was as follows: C-Reactive Protein: 7.67 mg/dL, WBC: 10950/mm³, 1 hour erythrocyte sedimentation rate: 49, and hemoglobin: 14.2 g/dL. First second force expiration volume (FEV₁) of the patient was 1540 mL (49%), force vital capacity (FVC) was 2510 mL (65%), FEV₁/FVC was 61, residual volume was 3280 mL (158%), and total lung volume was 6470 mL (106%) in the best respiratory function test of the patient while using a bronchodilator.

Surgical resection of the tumor was planned and was completely excised with muscle-protecting thoracotomy. It was observed during intraoperative evaluation that the tumor was well-marginated; however, while it could be dissected

* Toraks 18th National Congress, 1-5 April 2015, Belek, Antalya



Address for Correspondence: Ümit Aydoğmuş, Pamukkale Üniversitesi, Tıp Fakültesi, Göğüs Cerrahisi Anabilim Dalı, Denizli, Türkiye Phone: +90 258 296 60 00 E-mail: mdaydogmus@yahoo.com

©Copyright 2016 by Turkish Thoracic Society - Available online at www.turkishthoracicjournal.com

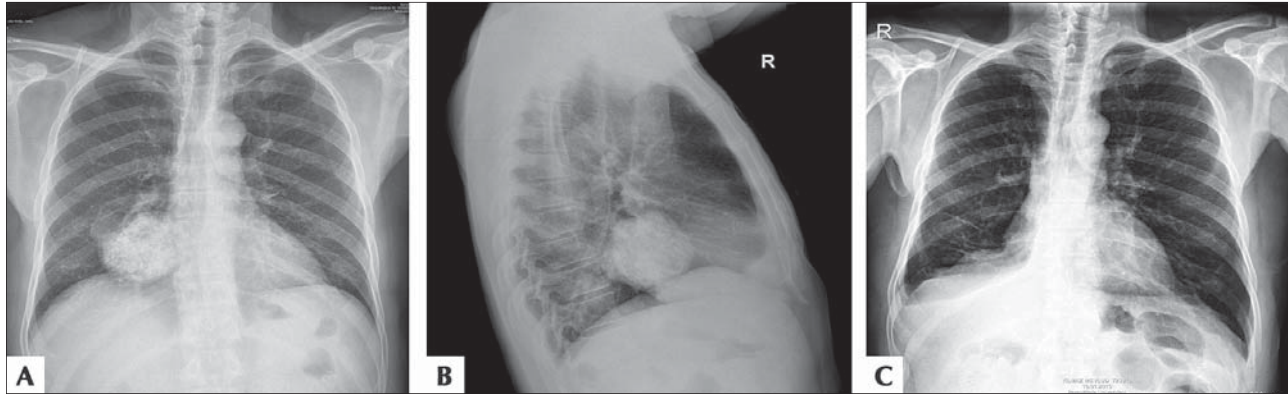


Figure 1. (A) Pre-operative PA chest radiography of the patient, (B) Pre-operative lateral chest graphy of the patient, (C) Post-operative PA chest radiography of the patient.

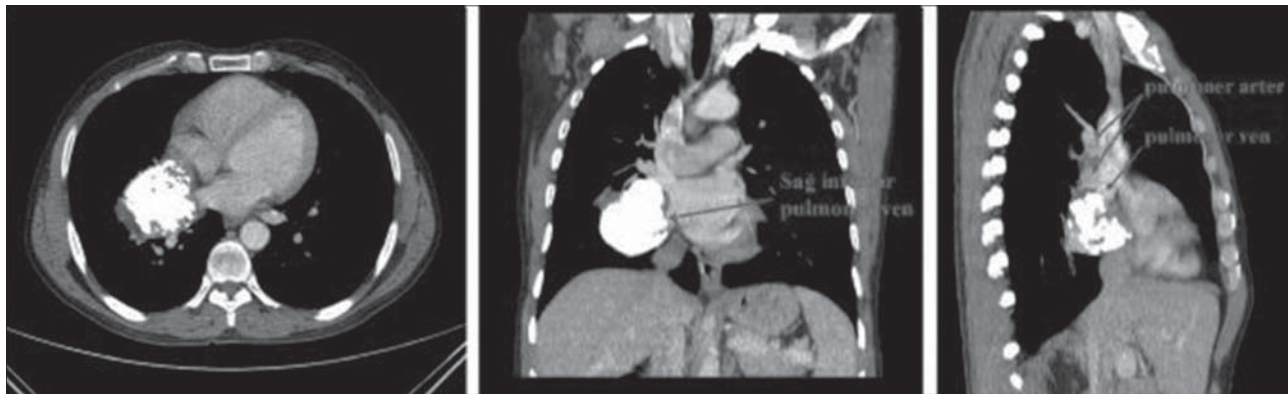


Figure 2. Thoracic CT sections of the patient.

from the lung parenchyma with a good margin, it did not allow for a dissection in the inferior pulmonary vein region (Figure 3A). Hence, intrapericardial right-lower lobectomy was performed. There were no postoperative complications.

Pathologically, a nodular, solid, calcified, brown mass leaning against the pulmonary vein, approximately 6.5 x 5 x 5 cm in size, was seen in the lung on macroscopic examination (Figure 3B). On the external surface of the material, nodular protrusions in the visceral pleura covering the lesion drew attention. Lung parenchyma was normal in regions without the lesion. On the myxoid collagenous bed, a tumoral proliferation, with a fusiform nucleus, generated by cells showing minimal pleomorphism, which created random bundles in some regions, was seen. Plasma cells and lymphocytes generating lymphoid follicles in some regions were observed on the tumor bed (Figure 4). The number of

mitoses per 50 high-power fields were two in the microscopic examination. While actin was found positive on immunohistochemical examination, desmine, p53, HHV-8, CD117 and ALK were found negative. CD34 was detected positive around vascular regions and in Bcl-2 lymphocytes. Ki-67 proliferation index was found as 3%. IMT diagnosis was made with these findings.

There are no recurrent findings in the patient who is in his ninth month after resection (Figure 1C).

DISCUSSION

Among the primary pulmonary regions of the adult period, IMT is a rarely encountered tumor with a rate of less than 1%. 44% to 78% of the cases of pulmonary origin are symptomatic [1,2,3]. Cough, fever and dyspnea are frequently seen signs [1,2,3]. IMT of cardiac origin is mostly in the form

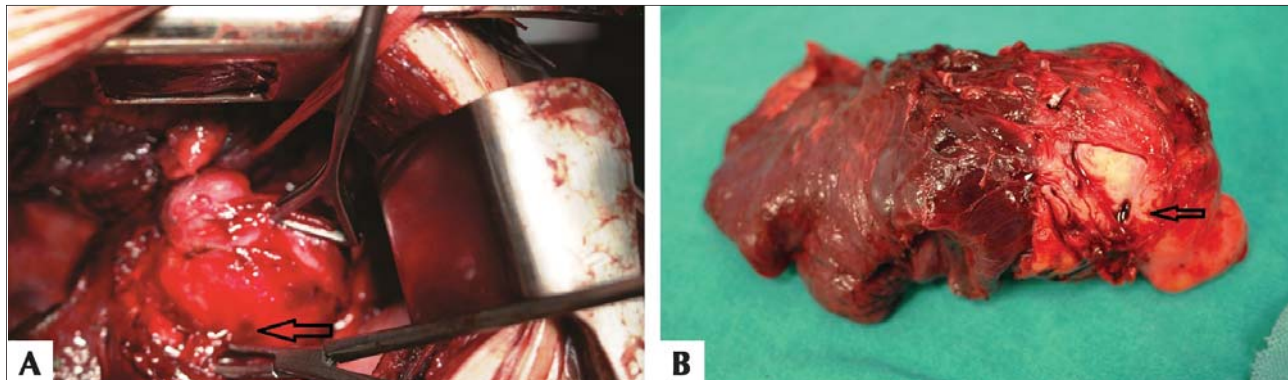


Figure 3. (A) Pulmonary vein branch continuing to the lung parenchyma from within the mass, (B) Vein branch progressing into the mass.

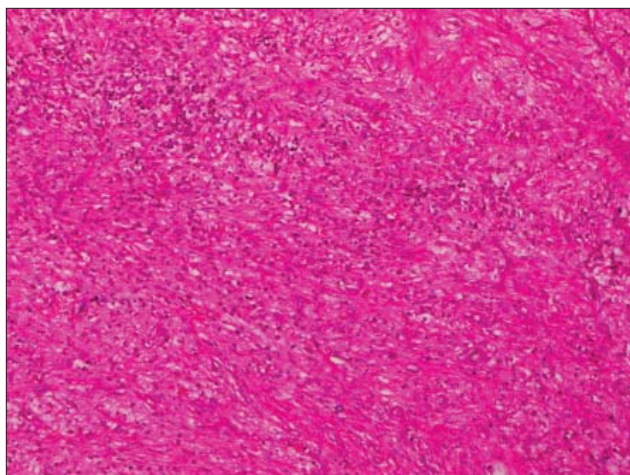


Figure 4. Fusiform cell proliferation infiltrated with lymphocyte and plasma cells X10, H&E.

of polypoid lesion with small myocardial infiltrations [4]. There is no specific symptom and it can show signs according to the location site [5]. IMT associated with heart valves and coronary arteries can progress fatally [4].

Radiologic findings also vary just as the symptoms. According to Argons et al., IMT is generally seen in the lower lobes as a solitary, peripheral mass with sharp margins, and invasion, mediastinum involvement and invasion of the hilar structures are extraordinary symptoms [6]. Melloni et al. [3] have specified that lesions are 3 cm and under in 61% of the cases and that radiologically, lesions with pneumonic infiltrations in the lower lobes are seen in 28% of the cases. Yet, in a series of Cerfolio et al. [1], mean tumor diameter of the cases is 4 cm (between 1 and 15 cm) and lesions of 48% of the cases are masses. Since a high rate of the patients was symptomatic in the series of Cerfolio et al. [1], it makes us think that symptoms may be associated with not only the location of the lesion but also with its size. Radiologic findings show differences in invasive and noninvasive forms of the lesion, which also asserts mortality suspicion. Hirai et al. [7] have detected irregularly-marginated lesions in 36%, spicule contour lesions in 18% and lesions showing pleural notch in 18% of the patients, and emphasized that it is difficult to differentiate IMTs from primary pulmonary cancers. FDG-PET may be helpful in malignancy differentiation; however, it should not be forgotten that its specificity is low in cases with acute, active inflammation [7]. Calcification is not generally seen in small lesions. Fabre et al. [2] have reported calcification in 6 of the 7 patients with lesions larger than 4 cm. The tumor was 6.5 cm in our case and showed intense calcification, and thus, FDG-PET was not performed. Pulmonary lesions that may cause calcification (like hamartoma, teratoma and Castleman disease) were considered in differential diagnosis. There is no specific distinguishing characteristic in cardiac lesions. Echocardiography is generally used in diagnosis [4,5]. While the ones located in the left atrium may lead to pulmonary edema, the ones located in the right atrium may cause vena cava inferior thrombosis, liver congestion or vena cava superior disease [4,5].

Bronchoscopy and transthoracic needle biopsy (TTNB) are mostly not helpful in diagnosis. In the series of Fabre et al. [2], diagnosis was made with bronchoscopy in 16% of the

patients and with TTNB in 8% of the patients. Therefore, surgery is generally necessary in diagnosis and treatment [1]. Videothoroscopic surgical resection with stable surgical margins is a good option in solitary pulmonary nodules [7]. Surgical excision is a diagnostic and treatment option in the ones with cardiac origin [5].

Some cases may progress locally invasive and invade the chest wall and mediastinal structures [1,2,7]. IMT, which is a rare tumor of mesenchymal origin, can be seen in nearly everywhere in the body [8]. Macroscopic findings of our case suggested that it may have been resulted from RIPV (Figure 3). No matter where it originates from, the main treatment of IMT is surgical excision [1-3,8]. The efficiency of nonsurgical treatments has not been established [3]. Local recurrence is very low in IMT of pulmonary origin; however, up to 25% recurrence can be seen in extrapulmonary IMT [4]. Survival is poor in both cardiac and pulmonary recurrences [1,3,4].

In conclusion, IMT is a rare neoplasm that may show radiologic resemblance to both benign and malignant lesions of the lungs with regard to localization, characteristics and size of the lesion. Despite being seen rarely and the low number of cases in series, the consensus is that a complete surgical resection is necessary for long-term survival.

Written consent was obtained from the patient for all interventions performed. The consent also include the use of findings and images related to his disease for scientific and educational purposes.

Author Contributions: Concept - Ü.A.; Design - E.U.; Supervision - G.Y.; Resources - F.T.; Materials - F.B.; Data Collection and/or Processing - E.U.; Analysis and/or Interpretation - Ü.A.; Literature Search - F.T.; Writing Manuscript - Ü.A.; Critical Review - F.B., G.Y.

Conflict of Interest: No conflict of interest was declared by the authors.

Financial Disclosure: The authors declared that this study has received no financial supports.

REFERENCES

1. Cerfolio RJ, Allen MS, Nascimento AG, et al. Inflammatory pseudotumors of the lung. *Ann Thorac Surg* 1999;67:933-6. [\[CrossRef\]](#)
2. Fabre D, Fadel E, Singhal S, et al. Complete resection of pulmonary inflammatory pseudotumors has excellent long-term prognosis. *J Thorac Cardiovasc Surg* 2009;137:435-40. [\[CrossRef\]](#)
3. Melloni G, Carretta A, Ciriaco P, et al. Inflammatory pseudotumor of the lung in adults. *Ann Thorac Surg* 2005;79:426-32. [\[CrossRef\]](#)
4. Yang X, Xiao C, Liu M, Wang Y. Cardiac inflammatory myofibroblastic tumor: does it recur after complete surgical resection in an adult? *J Cardiothorac Surg* 2012;4:7:44.
5. Jha NK, Trudel M, Eising GP, et al. Inflammatory myofibroblastic tumor of the right atrium. *Case Rep Med* 2010;2010. pii: 695216. doi: 10.1155/2010/695216.
6. Agrons GA, Rosado-de-Christenson ML, Kirejczyk WM, Conran RM, Stocker JT. Pulmonary inflammatory pseudotumor: radiologic features. *Radiology* 1998;206:511-8. [\[CrossRef\]](#)
7. Hirai S, Katayama T, Chatani N, et al. Inflammatory pseudotumor suspected of lung cancer treated by thoracoscopic resection. *Ann Thorac Cardiovasc Surg* 2011;17:48-52. [\[CrossRef\]](#)
8. Pavithran K, Manoj P, Vidhyadharan G, Shanmugasundaram P. Inflammatory myofibroblastic tumor of the lung: unusual imaging findings. *World J Nucl Med* 2013;12:126-8. [\[CrossRef\]](#)